

# Snapshot of degenerative aging of porcine intervertebral disc: a model to unravel the molecular mechanisms

Hongsik Cho<sup>1,3</sup>, Sang-Hyug Park<sup>2</sup>, Sangmin Lee<sup>1,3</sup>, Miji Kang<sup>1</sup>, Karen A. Hasty<sup>1,3,5</sup> and Song-Ja Kim<sup>4,5</sup>

<sup>1</sup>University of Tennessee Health Science Center  
Memphis, TN, U.S.A.

<sup>2</sup>Tufts University  
Boston, MA, U.S.A.

<sup>3</sup>Veterans Affairs Medical Center  
Memphis, TN, U.S.A.

<sup>4</sup>Kongju National University  
Gongju 314-701, Korea

<sup>5</sup>Corresponding authors: Tel, 1-901-523-8990 (ext 6175);  
Fax, 1-901-577-7273; E-mail, khasty@uthsc.edu (K.A.H.);  
Tel, 82-41-850-8507; Fax, 82-41-850-0927;  
E-mail, ksj85@kongju.ac.kr (S.J.K.)  
DOI 10.3858/emm.2011.43.6.036

Accepted 8 April 2011  
Available Online 18 April 2011

Abbreviations: AF, anulus fibrosus; IVD, intervertebral disc; NP, nucleus pulposus; PTGL, proteoglycan

## Abstract

Larger animal models, such as porcine, have been validated as appropriate models of the human disc with respect to biomechanics and biochemistry. They are advantageous for research as the models are relatively straightforward to prepare and easily obtainable for research to perform surgical techniques. The intention of this study was to quantitatively analyze gene expression for collagen and proteoglycan components of the extracellular matrix and for collagenase (MMP-1) in porcine discs of varying ages (Newborn; 2-3weeks, Mature; 6-9 month, Older; 2-3 years). In this study, we observed that the cell number and GAG (glycosaminoglycan) formation dramatically decreased with aging. Also, gene expression in the annulus fibrosus (AF) and nucleus pulposus (NP) cells changed with aging. The level of MMP-1 mRNA increased with age and both type I, II collagens decreased with age. The level of aggrecan mRNA was highest in the mature group and decreased significantly with aging. In the mature group, MMP-1 expression was minimal compared to the newborn group. In AF cells, type II collagen was expressed at a high level in the mature group with a higher level of ag-

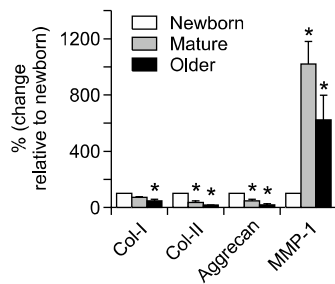
grecan, when aged NP showed a decrease in type II collagen. The model of IVD degeneration in the porcine disc shows many changes in gene expression with age that have been previously documented for human and may serve as a model for studying changes in IVD metabolism with age. We concluded that the porcine model is excellent to test hypotheses related to disc degeneration while permitting time-course study in biologically active systems.

**Keywords:** aging; glycosaminoglycans; intervertebral disk degeneration; reverse transcriptase polymerase chain reaction; swine

## Introduction

The Intervertebral Disc (IVD) is a unique structure that consists of the nucleus pulposus (NP), a hydrated proteoglycan (PTGL)-rich gel, surrounded by a tough layer of collagen fibrils, the annulus fibrosus (AF). These components form a unit in which all elements have to retain their structural integrity in order to provide normal function. For example, the hydrated PTGL's of the NP provide viscoelasticity and also resistance to compression upon axial loading. The energy applied upon loading dissipates through the cartilage endplate to the vertebral body and laterally to the AF fibers, which receives it in the form of tension. With aging, the PTGLs and the water content of the disc decreases. In contrast, the collagen content increases, compromising the biomechanical properties and impairing the function of the disc (Adams and Roughley, 2006; Alini *et al.*, 2008; Colombini *et al.*, 2008)

In addition to the intact morphological structures, a normal disc contains collagen types I, II, III, V, VI, IX, and XI. Few studies have been performed on the localization of the latter five collagen types. Previous studies have shown that the amount of type I collagen from the outer AF to the NP decreases, whereas the amount of type II collagen increases. Therefore, the AF contains more collagen type I than II, whereas the NP consists mainly of type II collagen (Setton *et al.*, 2007). Degradation of the disc is believed to be in part of an outcome of age-related degeneration of the proteoglycans and collagens by locally generated MMPs (matrix metalloproteinases) but its role of is not yet



**Figure 1.** The aged AF cells were compared with newborn AF cells according to gene expression by RT-PCR. The level of expression of type I collagen decreased with age. Significance is seen between the newborn and the older group, but not between the Newborn and the mature group. The level of expression of type II collagen and aggrecan were significantly decreased from the Newborn in both the mature and older group whereas the level of mRNA for MMP-1 was highly expressed in aged AF. The respective cells from Newborn ( $n = 10$ , 1-2 weeks old) Mature ( $n = 7$ , 7-8 month old) or Older ( $n = 4$ , 2-3 years old) pigs were extracted for mRNA and specific genes were quantitated by real time RT-PCR. The mRNA levels are normalized to values for housekeeping genes and plotted as change relative to newborn (%). Data is presented as mean  $\pm$  SD (\* Indicates  $P < 0.05$  relative to newborn tissue).

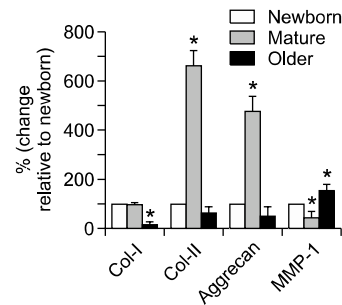
been fully clarified (Boos *et al.*, 1997; Borenstein *et al.*, 2001).

To test hypotheses of degenerative mechanisms and pathways in humans, animal models offer advantages over cell culture and mathematical models because they can be prepared directly and gripped to perform motion segments studies and surgical techniques. For these reasons, animal models can be exploited for time-course studies in a supervised, biologically active system (Elliott and Sarver, 2004).

This study quantitatively analyzed gene expression for collagen and proteoglycan components of the extracellular matrix and for collagenase (MMP-1) in porcine discs of varying ages. A shift in the balance of expression with age could provide a valuable model to study how aging might affect the metabolism and pathogenesis of the IVD. Accordingly, porcine lumbar spines were obtained from various age groups and the disc components were categorized into either NP or AF. The quantity of type I collagen, type II collagen, and PTGL within IVD samples were identified through a real time polymerase chain reaction (RT PCR) analysis. During the study, the expression of MMP-1 was also quantitatively analyzed.

## Results

The model of IVD aging in the domestic porcine shows many changes in gene expression with aging. The mRNA level of MMP-1 expression increased in AF with age while type II collagen ex-

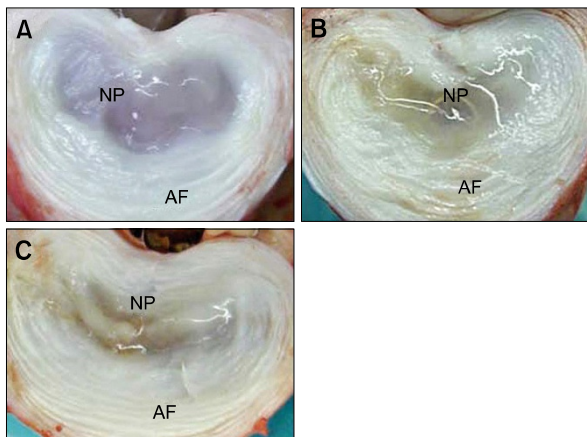


**Figure 2.** The aged NP cells were compared with newborn NP cells according to gene expression by RT-PCR. Although the level of mRNA for type II collagen and aggrecan were highly expressed in the mature group. Finally, the level of expression of type I collagen, type II collagen and aggrecan decreased with age. Show the opposite pattern in the level of expression of MMP-1 according to aged. The respective cells from Newborn ( $n = 5$ , 1-2 weeks old) Mature ( $n = 5$ , 7-8 month old) or Older ( $n = 4$ , 2-3 years old) pigs were extracted for mRNA and specific genes were quantitated by real time RT-PCR. The mRNA levels are normalized to values for housekeeping genes and plotted as change relative to newborn (%). Data is presented as mean  $\pm$  SD (\* Indicates  $P < 0.05$  relative to newborn tissue).

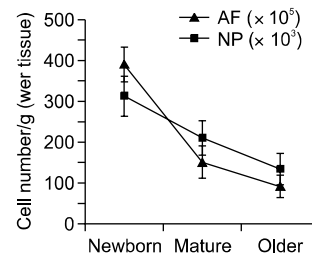
pression was down regulated. The level of MMP-1 mRNA was increased significantly from newborn level in both the mature and older groups. Both type I and type II collagens significantly decreased with age with type II collagen expressed to a lesser extent than type I collagen. The level of aggrecan mRNA was the highest in the newborn group and decreased significantly in the mature and older group (Figure 1).

When the gene expression of NP was analyzed, MMP-1 expression was found to be minimal in the mature group in comparison to the newborn and older groups. NP gene expression showed that type I collagen remained relatively constant between the newborn and mature groups with a very steep drop in levels in the older group. In contrast to the AF, type II collagen and aggrecan peaked in the mature group but fell to amounts less than that of the newborn group in the older group. NP expression of MMP-1 showed a unique pattern with quantities lowest in the mature group and highest in the old group (Figure 2). As seen in Figures 1 and 2, the expression of all examined genes was low in the old groups except for MMP-1.

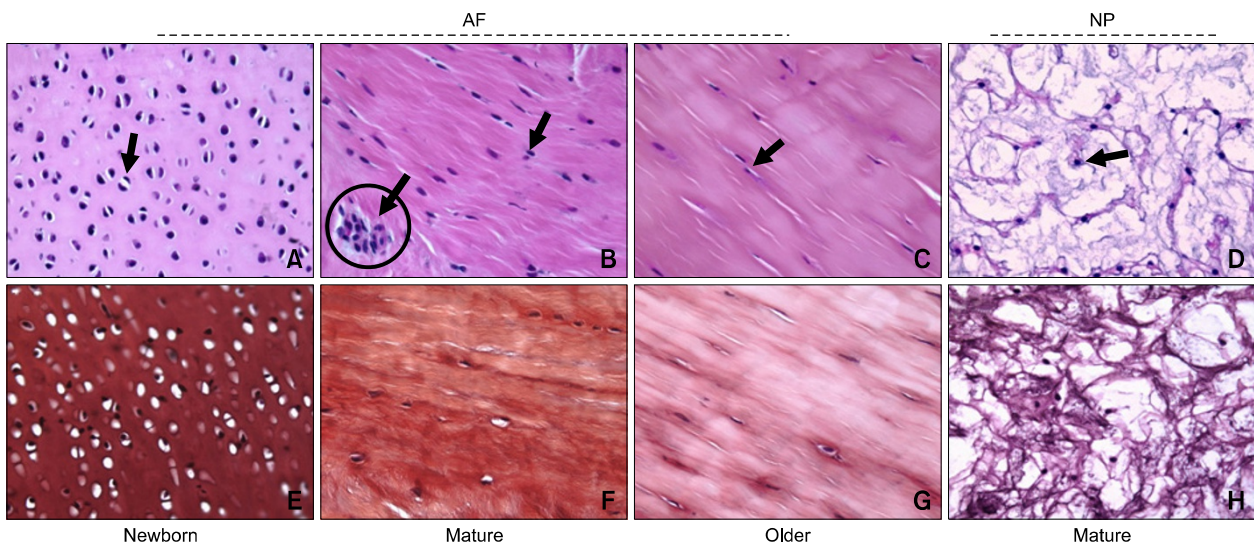
Morphological variability on a macroscopic level was observed between the AF of varying age groups when AF tissues were obtained from the spine. The color and shape of newborn AF was very similar to those of mature cartilage and ring-shaped collagen fibers were clearly visible. The NP of a newborn porcine IVD was white in color and gelatinous in form, whereas the NP of mature porcine IVD was more yellowish in color and appeared to be dehydrated. Old NP was almost nonexistent and



**Figure 3.** Representative discs from the porcine lumbar spines of different age. (A) Younger disc (Grade I; Boos *et al.*), (B) Mature Disc (Grade III), (C) Older Disc (Grade IV), In the older disc, the gelatinous nucleus had been replaced by fibrous material or disappeared. There was a loss of annular-nuclear demarcation (Macroscopic grading of age-related disc alterations according to Thompson *et al.*, 1990).



**Figure 5.** Cell number according to age. Cell number was determined by trypan blue exclusion in enzymatic digests of dissected annular or nuclear tissues, shown as mean cell number/gram of tissue +/- SD (Unit; AF is 100,000 / NP is 1,000).



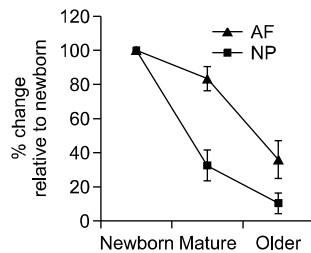
**Figure 4.** Histology comparison of AF tissue according to age and mature NP tissue. The cells were uniformly distributed in the newborn, and lacunae were observed surrounding them. (arrow in A) The newborn AF tissue was stained heavily with safranin-O, confirming that that the aged tissues are less in GAG than the newborn tissue (E, F, G). (circle in B) Newborn AF tissue shows numerous cells encapsulated with a material called lacunae; the mature AF tissue starts to show strains stacked in different diagonal directions with markedly reduced numbered cells and developed cell clusters (circle in B). In older AF tissue strains become blurred (C). NP tissue showing irregular direction and shape of strains. The NP cells have a rounder shape than the same age AF cells (D, H) (Note; the arrow indicated to cell; Newborn; 2 wks, 12 lb / mature; 6-7 mth, 150 lb / older; 2-3 yr, 250-350 lb).

brownish (Figure 3).

Histological analysis provides valuable information about the matrix build up and the cell distribution during aging. The cell shape and the tissue formation of newborn porcine (1-2 weeks) annular tissue was very similar to hyaline cartilage seen in joints, according to observations made through the H&E and safranin-O stain. No fibers or rings were observed in the sample. The cells were uniformly

distributed in the baby porcine tissue, and surrounding lacunae were observed (Figure 4A).

The mature and older groups showed several differences including fibers and rings in the AF. The older AF cells showed a more flattened shape than the newborn group and lie in a modest lacunar space within collagen lamellar bundles and cell clusters. The tissue also took on a more fibrocartilaginous pattern, and traces of collagen fiber



**Figure 6.** Amount of GAG in AF and NP tissue according to age with DMB assay. The DMB results showed that the amount of GAG decreased with aging in equal wet weight (average weight is 0.1 g). The aged tissues were compared with newborn tissue and indicated with % (Data is presented as mean  $\pm$  SD).

were found in the aged tissues. In the NP tissue, it consists of ground substance and physaliphorous cells (Figure 4B). At a gross anatomical inspection, the NP aged from a clear jelly like appearance to yellow in the mature group. Old pig samples lost almost all NP tissue and any remaining substance was brown. Due to a large decline in cell number of the NP, not enough tissue could be collected for microscopic inspection of the old group. However, no distinct histological differences were found between the newborn and mature NP samples (data not shown).

Using trypan blue (Invitrogen, CA) staining after isolating cells from both of AF and NP tissues, we observed that the cell numbers were dramatically decreased with aging in AF tissue (Figure 5). This is in agreement with the histopathological results seen Figure 4A. The synthesis of GAG is important for the inner layers of the AF tissue and NP tissue. DMB assay results showed that the amount of GAG decreased with aging in both AF and NP tissue (Figure 6). However, the total amount of glycosaminoglycan per cell dramatically increased with aging in both tissues.

## Discussion

Several previous studies have shown that large animal models mirror the anatomy, pathology, histology, etc. of humans. Similarly, the present study found that humans and pig share many similar characteristics in regard to IVD aging. Some investigators have supported the idea that proteoglycans and collagens undergo marked changes in IVD tissues during the process of aging (Gotz *et al.*, 1997; Gruber and Hanley, 1998; Inkinen *et al.*, 1998; Nerlich *et al.*, 1998; Sztrolovics *et al.*, 1999). The ECM content and the synthesis of aggrecan decreases noticeably with age, and in the end-stage degeneration of human IVD (Melrose *et al.*,

1992; Buckwalter *et al.*, 1994; Antoniou *et al.*, 1996).

An age-related decrease in the content of small proteoglycans was detected in the annulus fibrosus as well as changed synthesis patterns, there is an increase in matrix degradation (Cawston and Billington, 1996; Dolan and Adams, 2001). The major degradation process is interfered by the MMPs. These are a large family of extracellular zinc-dependent proteinases comprising four main subfamilies: collagenases, stromelysins, gelatinases, and membrane-type MMPs. MMPs also changes synthesis patterns and matrix degradation increases. Throughout disc turnover, MMPs 1, 3, 7, 9, and 13 and the number of MMPs that degrade many of the main matrix components increase during disc degeneration (Roberts *et al.*, 2000; Le Maitre *et al.*, 2005, 2006).

Our results have shown that the level of MMP-1 expression is increased in the both aged AF and NP, while type II collagen and aggrecan expression were down-regulated. As seen in Figures 1 and 2, the expression of all genes examined except for MMP-1 was low in the old pigs. Interestingly, in the NP of the mature pig, mRNA for type II collagen and aggrecan were elevated relative to immature pigs, which may be related to the increased compressive load in larger animals.

The porcine model demonstrated that as pigs age the number of cells in both the AF and NP decrease. A decrease in the amount of GAG molecules in the IVD was also observed. These cells are responsible for the regulation of the matrix and the syntheses in the disc that manage the homeostasis between the matrix synthesis and matrix degradation. Roberts *et al.* (2000) demonstrated that the normal human intervertebral disc in adulthood comprises a huge amount of extracellular matrix dispersed by a small number of cells that accounts for approximately 1% of the total volume. Interestingly, the ratio of GAG to the number of cells increased as the pig aged. This could mean that the remaining cells try to compensate for the loss and increase activity with the aging process.

In addition to gene expression and matrix synthesis change, AF and NP showed changes in histomorphology. Some researchers have contended that changes in histomorphology such as fibrosis of the nucleus pulposus, lamellae disorganizing of the annulus fibrosus, and thinning and calcification of the cartilaginous endplates are the results of tissue reconstruction mediated by disc cells (Thompson *et al.*, 1990; Yasuma *et al.*, 1990; Ishii *et al.*, 1991; Adams and Roughley, 2006).

In humans, the major age-related changes in the intervertebral disc are decay of cells, alterations in cell density, and matrix degeneration. The altera-

tions also include an increased number and range of clefts and tears. The presence of granular material and the progressive changes in disc histology that occur with age have been described in detail by Boos *et al.* (2002).

More structural disorganization of the IVD, including cracks, thinning of the end plate, altered cell density, microfracture in the adjacent subchondral bone, and bone sclerosis, is also seen with the aging process along with cell proliferation, clustered formation, and a greater level of cell death. At the ultrastructural level, wavy collagen bands characterize mature AF tissue whereas in older AF tissue, the collagen fiber number is much less and the shape is unclear.

With aging process or degenerated discs, the cell clusters easily can be seen in areas where cells may easily access to nutrient supply and growth factors, these areas are adjacent to the newly constituted blood vessels or tissue clefts. (Beard *et al.*, 1981; Johnson *et al.*, 2001; Boos *et al.*, 2002). The tissue clefts would predictably alter the mechanical environment of the adjoining tissues, thereby accompanying with increased level of cytokines such as interleukin-1; the cells inside these areas would demonstrate aging process phenotype (Kang *et al.*, 1997; Le Maitre *et al.*, 2005). Therefore, they may produce increased MMP. (Poole *et al.*, 1997).

Our results show that the results of a histomorphological analysis of AF and NP of porcine samples are closely associated with human tissue. We believe that these similarities demonstrate that pigs can serve as an effective model for studying IVD and its pathology in humans. In this study, we have not shown the histomorphology of different aged NP because the old NP was almost non-existent and brownish. The intervertebral disc renders cells of the disc, particularly in the central nucleus, which is considerably far removed from any source of nutrients or clearance of metabolites and is often described as the largest avascular tissue in the body.

In conclusion, the gene expression patterns, GAG contents, and number of cells in aging of pig IVD in this study were similar to patterns seen in humans. Therefore, it can be concluded that the porcine model may be utilized for studying changes in IVD metabolism with age and serve as an accurate model for humans.

## Methods

### Source of tissues

IVD used in this investigation was obtained from lumbar

disc of the following age classifications: Newborn (NB): 2-3 weeks old, Mature: 7-9 month old, Older: 2-3 years old. A total of 21 pigs (NB: 10, mature: 7, old: 4) were used for this study. The spine was sectioned between each of the lumbar discs from 10th thoracic vertebrae (T10) to 5th lumbar vertebrae (L5). The vertebrae T10 to L2 were used for cell isolation. RNA was extracted for RT-PCR and GAG was measured in a 1,9-dimethylmethylene blue (DMB) assay. The L3 to L5 vertebrae were used for histopathology and macroscopic grading. The muscles and tendons were removed, and the column was sectioned transversally in the middle of each disc. The AF tissue was isolated from both halves of the disc. The outer edge containing muscle and connection ligaments was removed to obtain pure AF tissue specimens. The inner edge which is transitional zone touching the NP was also discarded. All pig tissues were taken from the spines of healthy pigs freshly sacrificed for other experiments according to approved protocols and experimental procedures at the University of Tennessee Center for the Health Sciences.

### Cell isolation and counting

Cells from the AF & NP tissues were isolated by 1-2 hours digestion at 37°C in 0.05% pronase (Boehringer Mannheim), followed by overnight digestion at 37°C in 0.2% collagenase (Worthington Biologicals) using modified F-12K medium (Invitrogen) with 5% fetal calf serum (FCS, Atlanta Biologicals), 4.8 mM CaCl<sub>2</sub>, and 40mM HEPES buffer (Sigma). After 18 hours of shaking, the specimens were completely digested and individual cells released. This was confirmed by phase contrast microscopy. The digested samples were then centrifuged at 250 g for 5 minutes to isolate the annulus fibrosis chondrocytes for a cell counting test. After resuspension of the cell pellets, the cells were counted using a hemocytometer and cell viability was determined using a trypan blue exclusion test.

### Analysis of gene expression

The cells ( $1 \times 10^6$ ) from AF and NP tissue of each aging group's pig were centrifuged and 1ml TRIzol™ reagent was added (Life Technologies, Carlsbad, CA). The total RNA was extracted following the manufacturer's instructions.

Both total RNA concentration and its purity were determined using a spectrophotometer (GeneQuant, Pharmacia, UK) at 260 nm and 280 nm UV wavelengths. Reverse transcriptase was used to prepare cDNA and the samples were assayed using primers and TaqMan® probes for targeting the following genes: porcine procollagens type I and II, MMP-1, aggrecan core protein, and housekeeping genes porcine GAP 2 Vic and beta actin RNA (Supplemental Data Table S1). This was performed on an ABI PRISM 7900 system (Applied Biosystems, CA), which detects fluorescence signals from TaqMan probes during the PCR amplification. A comparative cycle time (CT) method was used to quantify the target gene, due to a lack of known amount of standard. The Delta CT was determined by subtracting the average CT of the housekeeping gene from the average CT of the target gene. The cells from the baby annular and nucleus tissue served as a reference for



comparison of mRNA levels with the aged disc cells.

### Measurement of glycosaminoglycan (GAG)

Concentrations of the GAG in AF and NP tissues were determined using a 1,9-dimethylmethylene blue (DMB) assay. The samples were mixed with a digestion solution, containing 500 g/ml papain (CalBiochem, Indianapolis, IN) in 0.1 M sodium phosphate with 5 mM Na-EDTA, 5 mM cysteine-HCl at pH 6.2 and incubated in a 65°C water bath for 16 hours. In addition to preparing samples for the DMB assay, control samples were prepared using 0.2% collagenase/Dulbecco's Modified Eagle Medium (DMEM) mixed with the digestion solution. A 5 ml aliquot of each sample was used and gently mixed and immediately transferred to disposable cuvettes and the optical density was determined at a wavelength of 525nm using a Beckman Spectrophotometer (Model Number: DU-20) (Farndale *et al.*, 1986).

### Histology

The annular tissues and nucleus tissues were fixed in 10% buffered formaldehyde, dehydrated in alcohol, paraffin-sectioned, and stained with H&E and Safranin-O for GAG. Both staining intensity and cell morphology were observed via light microscopy.

### Statistics

All experiments were performed independently at least three times. Student's *t*-test and analysis of variance were used to determine statistical significance.

### Acknowledgements

This work was supported in part by the Arthritis Foundation (H. Cho) and Veteran's Administration (K. A. Hasty), and a National Research Foundation of Korea (NRF) grant by the Korean Government (MEST)(2009-0084569 & 2010-0003239). The authors would like to thank Christy Patterson who is technical director and William J. Tidwell who is medical student of University of Tennessee for their help for assistant of this study and invaluable comments.

### Supplemental data

Supplemental data include a figure and a table and can be found with this article online at [http://e-emm.or.kr/article/article\\_files/SP-43-6-02.pdf](http://e-emm.or.kr/article/article_files/SP-43-6-02.pdf).

### References

Adams MA, Roughley PJ. What is intervertebral disc degeneration, and what causes it? *Spine (Phila Pa 1976)* 2006;31:2151-61

Alini M, Eisenstein SM, Ito K, Little C, Kettler AA, Masuda K, Melrose J, Ralphs J, Stokes I, Wilke HJ. Are animal models useful for studying human disc disorders/degeneration? *Eur Spine J* 2008;17:2-19

Antoniou J, Steffen T, Nelson F, Winterbottom N, Hollander

AP, Poole RA, Aebi M, Alini M. The human lumbar intervertebral disc: evidence for changes in the biosynthesis and denaturation of the extracellular matrix with growth, maturation, ageing, and degeneration. *J Clin Invest* 1996;98:996-1003

Beard HK, Roberts S, O'Brien JP. Immunofluorescent staining for collagen and proteoglycan in normal and scoliotic intervertebral discs. *J Bone Joint Surg Br* 1981;63B:529-34

Boos N, Nerlich AG, Wiest I, von der Mark K, Aebi M. Immunolocalization of type X collagen in human lumbar intervertebral discs during ageing and degeneration. *Histochem Cell Biol* 1997;108:471-80

Boos N, Weissbach S, Rohrbach H, Weiler C, Spratt KF, Nerlich AG. Classification of age-related changes in lumbar intervertebral discs: 2002 Volvo Award in basic science. *Spine (Phila Pa 1976)* 2002;27:2631-44

Borenstein DG, O'Mara JW Jr, Boden SD, Lauerman WC, Jacobson A, Platenberg C, Schellinger D, Wiesel SW. The value of magnetic resonance imaging of the lumbar spine to predict low-back pain in asymptomatic subjects : a seven-year follow-up study. *J Bone Joint Surg Am* 2001;83-A:1306-11

Buckwalter JA, Roughley PJ, Rosenberg LC. Age-related changes in cartilage proteoglycans: quantitative electron microscopic studies. *Microsc Res Tech* 1994;28:398-408

Cawston TE, Billington C. Metalloproteinases in the rheumatic diseases. *J Pathol* 1996;180:115-7

Colombini A, Lombardi G, Corsi MM, Banfi G. Pathophysiology of the human intervertebral disc. *Int J Biochem Cell Biol* 2008;40:837-42

Dolan P, Adams MA. Recent advances in lumbar spinal mechanics and their significance for modelling. *Clin Biomech (Bristol, Avon)* 2001;16 Suppl 1:S8-S16

Elliott DM, Sarver JJ. Young investigator award winner: validation of the mouse and rat disc as mechanical models of the human lumbar disc. *Spine (Phila Pa 1976)* 2004;29:713-22

Farndale RW, Buttle DJ, Barrett AJ. Improved quantitation and discrimination of sulphated glycosaminoglycans by use of dimethylmethylene blue. *Biochim Biophys Acta* 1986;883:173-7

Gotz W, Barnert S, Bertagnoli R, Miosge N, Kresse H, Herken R. Immunohistochemical localization of the small proteoglycans decorin and biglycan in human intervertebral discs. *Cell Tissue Res* 1997;289:185-90

Gruber HE, Hanley EN Jr. Analysis of aging and degeneration of the human intervertebral disc. Comparison of surgical specimens with normal controls. *Spine (Phila Pa 1976)* 1998;23:751-7

Inkinen RI, Lammi MJ, Lehmonen S, Puustjarvi K, Kaapa E, Tammi MI. Relative increase of biglycan and decorin and altered chondroitin sulfate epitopes in the degenerating human intervertebral disc. *J Rheumatol* 1998;25:506-14

Ishii T, Tsuji H, Sano A, Katoh Y, Matsui H, Terahata N. Histochemical and ultrastructural observations on brown degeneration of human intervertebral disc. *J Orthop Res*

1991;9:78-90

Johnson WE, Eisenstein SM, Roberts S. Cell cluster formation in degenerate lumbar intervertebral discs is associated with increased disc cell proliferation. *Connect Tissue Res* 2001;42:197-207

Kang JD, Stefanovic-Racic M, McIntyre LA, Georgescu HI, Evans CH. Toward a biochemical understanding of human intervertebral disc degeneration and herniation. Contributions of nitric oxide, interleukins, prostaglandin E2, and matrix metalloproteinases. *Spine (Phila Pa 1976)* 1997;22:1065-73

Le Maitre CL, Freemont AJ, Hoyland JA. The role of interleukin-1 in the pathogenesis of human intervertebral disc degeneration. *Arthritis Res Ther* 2005;7:R732-45

Le Maitre CL, Freemont AJ, Hoyland JA. Human disc degeneration is associated with increased MMP 7 expression. *Biotech Histochem* 2006;81:125-31

Melrose J, Ghosh P, Taylor TK, Hall A, Osti OL, Vernon-Roberts B, Fraser RD. A longitudinal study of the matrix changes induced in the intervertebral disc by surgical damage to the annulus fibrosus. *J Orthop Res* 1992;10:665-76

Nerlich AG, Boos N, Wiest I, Aebi M. Immunolocalization of major interstitial collagen types in human lumbar interver-

tebral discs of various ages. *Virchows Archiv* 1998;432:67-76

Poole CA. Articular cartilage chondrons: form, function and failure. *J Anat* 1997;191( Pt 1):1-13

Roberts S, Caterson B, Menage J, Evans EH, Jaffray DC, Eisenstein SM. Matrix metalloproteinases and aggrecanase: their role in disorders of the human intervertebral disc. *Spine (Phila Pa 1976)* 2000;25:3005-13

Setton L, Bonassar L, Masuda K. "Regeneration and Replacement of the Intervertebral Disc" *Principles of tissue engineering 3rd (Elsevier Press) 2007;Chap.58*

Sztrolovics R, Alini M, Mort JS, Roughley PJ. Age-related changes in fibromodulin and lumican in human intervertebral discs. *Spine (Phila Pa 1976)* 1999;24:1765-71

Thompson JP, Pearce RH, Schechter MT, Adams ME, Tsang IK, Bishop PB. Preliminary evaluation of a scheme for grading the gross morphology of the human intervertebral disc. *Spine (Phila Pa 1976)* 1990;15:411-5

Yasuma T, Koh S, Okamura T, Yamauchi Y. Histological changes in aging lumbar intervertebral discs. Their role in protrusions and prolapses. *J Bone Joint Surg Am* 1990;72:220-9