

ARTICLE

An atypical 7q11.23 deletion in a normal IQ Williams–Beuren syndrome patient

Giovanni Battista Ferrero^{1,5}, Cédric Howald^{2,5}, Lucia Micale³, Elisa Biamino¹, Bartolomeo Augello³, Carmela Fusco^{3,4}, Maria Giuseppina Turturo³, Serena Forzano¹, Alexandre Reymond² and Giuseppe Merla^{*,3}

Williams–Beuren syndrome (WBS; OMIM no. 194050) is a multisystemic neurodevelopmental disorder caused by a hemizygous deletion of 1.55 Mb on chromosome 7q11.23 spanning 28 genes. Haploinsufficiency of the *ELN* gene was shown to be responsible for supravalvular aortic stenosis and generalized arteriopathy, whereas *LIMK1*, *CLIP2*, *GTF2IRD1* and *GTF2I* genes were suggested to be linked to the specific cognitive profile and craniofacial features. These insights for genotype–phenotype correlations came from the molecular and clinical analysis of patients with atypical deletions and mice models. Here we report a patient showing mild WBS physical phenotype and normal IQ, who carries a shorter 1 Mb atypical deletion. This rearrangement does not include the *GTF2IRD1* and *GTF2I* genes and only partially the *BAZ1B* gene. Our results are consistent with the hypothesis that hemizyosity of the *GTF2IRD1* and *GTF2I* genes might be involved in the facial dysmorphisms and in the specific motor and cognitive deficits observed in WBS patients. *European Journal of Human Genetics* (2010) 18, 33–38; doi:10.1038/ejhg.2009.108; published online 1 July 2009

Keywords: 7q11.23; microdeletion; Williams–Beuren syndrome; mental retardation; haploinsufficiency

INTRODUCTION

Williams–Beuren syndrome (WBS) is a multisystemic developmental disorder caused by a hemizygous deletion spanning 1.55 or 1.84 Mb on chromosome 7q11.23, a segment encoding 28 genes.^{1–4} This region frequently undergoes genomic rearrangements due to the presence of low copy repeats flanking the commonly deleted region and results in meiotic nonallelic paralogous recombination.¹ Consistently, along with the 7q11.23 deletion, recent papers reported the reciprocal duplication^{5,6} and inversion^{7,8} of the region. WBS has a prevalence estimated between 1/7500 and 1/20 000.⁹ The phenotype is widely heterogeneous in severity and manifestations (see Table 1), but generally entails distinctive facial dysmorphisms, cardiovascular abnormalities and mental retardation with a particular cognitive profile.¹⁰ The main cardiovascular abnormality is a generalized arteriopathy that is often accompanied by early hypertension.¹¹ It is characterized by arteries stenoses, predominantly affecting the supravalvular aortic (SVAS) and peripheral pulmonary (PPS) regions. Nearly all WBS infants and young children exhibit developmental delay, which subsequently results in mild to moderate mental retardation. WBS is characterized by a specific cognitive profile with relative strengths in selected language domains alongside a prominent weakness in visuospatial construction.¹¹ Similarly, WBS patients show a combination of high sociability and empathy for others with high anxiety. Patients demonstrate an adaptable behavior profile with relative strengths in socialization and communication skills and obvious weakness in daily living skills.^{10,12} Endocrine abnormalities, including impaired glucose tolerance and diabetes mellitus are commonly observed in WBS patients and recently impairment of thyroid function and/or structure has been reported in about a third of patients.¹³

The majority of deletions span the same interval, however, a few individuals have smaller and/or larger deletions of the region. Their phenotypic features vary from isolated SVAS to classic WBS associated

with infantile spasms or with autism spectrum behavior.^{5,14,15} Genotype–phenotype correlation studies of these patients suggested important insights in the genetic causes of some of the typical WBS symptoms. So far, the strongest correlations have been found for some of the facial features and cardiovascular problems linked to elastin haploinsufficiency.^{16,17} In addition, clinical and molecular correlations in atypical patients and mouse models studies provided further genotype–phenotype correlations. These studies revealed that the most telomerically mapping genes such as *GTF2I*, *GTF2IRD1* and *CLIP2* (a.k.a. *CYLN2*) may contribute to the behavioral and cognitive manifestation of WBS.^{14,18–24}

Here we describe a male child (WBS207) with mild WBS physical features, average intelligence with normal IQ and only some features of the WBS neuropsychological profile. He carries a smaller atypical deletion of ~1 Mb that does not include *GTF2IRD1*, *GTF2I* and only partially includes *BAZ1B*. Our results are consistent with the hypothesis that associates *GTF2IRD1* and *GTF2I* hemizyosity to the WBS specific motor and cognitive deficits.

MATERIALS AND METHODS

Sample preparation

Genomic DNA from the proband and his parents were extracted from peripheral blood leukocyte using QIAamp DNA Mini Kit (Qiagen, Hilden, Germany). WBS and normal individuals' samples to be used as controls were selected from a previous study.²¹

Fluorescence *in situ* hybridization and quantitative real-time PCR

Fluorescence *in situ* hybridization was performed on metaphase cells following standard technique using the LSI *ELN*, D7S486 and D7S522 probes (Vysis). At least 30 metaphases were analyzed. All quantitative real-time PCR (QPCR) reactions were carried out as described.²¹ Amplicons and primer pairs are presented in Supplementary Table S1. The comparative C_t method reported in²⁵ was used to measure relative quantities.

¹Department of Pediatrics, University of Torino, Torino, Italy; ²Center for Integrative Genomics, University of Lausanne, Lausanne, Switzerland; ³Medical Genetics Unit, IRCCS 'Casa Sollievo della Sofferenza', San Giovanni Rotondo, Italy; ⁴PhD Program, Department of Biomedical Sciences, University of Foggia, Foggia, Italy

*Correspondence: Dr G Merla, Servizio di Genetica Medica, IRCCS Casa Sollievo della Sofferenza, Poliambulatorio Giovanni Paolo II, I-71013 San Giovanni Rotondo (FG), Italy. Tel: +39 0882 416350; Fax: +39 0882 411616; E-mail: g.merla@operapadrepio.it

⁵These authors contributed equally to this work

Received 19 January 2009; revised 19 May 2009; accepted 27 May 2009; published online 1 July 2009

Table 1 Proband phenotype compared to WBS typical phenotype

| Clinical features of WBS | Typical deletion ^a | Proband |
|--------------------------------------|-------------------------------|------------------|
| <i>Cardiovascular</i> | | |
| Supravalvular aortic stenosis (SVAS) | 75% | + |
| Peripheral pulmonary stenosis (PPS) | 50% | – |
| Valvular pulmonic stenosis | 5% ^b | + |
| Hypertension | 50% | – |
| <i>Neuropsychological</i> | | |
| Developmental delay | 95% | – |
| Mental retardation | 75% | – |
| Cognitive profile | + | +/– ^c |
| Psychological profile | + | +/– ^c |
| Behavioral profile | + | – |
| <i>Craniofacial</i> | | |
| Bitemporal narrowing | + | + |
| Periorbital fullness | + | – |
| Epicanthal folds | + | – |
| Stellate irides | + | – |
| Malar flattening | + | – |
| Short upturned nose | + | + |
| Bulbous nasal tip | + | + |
| Long philtrum | + | + |
| Full lips | + | + |
| Dental abnormalities/malocclusion | + | – |
| <i>Endocrine</i> | | |
| Subclinical hypothyroidism | 30% ^d | + |
| Precocious puberty | 50% | – |
| Hypercalcemia | 15% | – |
| <i>Gastrointestinal</i> | | |
| Feeding difficulties | 70% | – |
| Celiac disease | 9.5% | – |
| Constipation | 40% | – |
| <i>Genitourinary</i> | | |
| Congenital malformation | 20% | – |
| Enuresis | 50% | + |
| <i>Ocular</i> | | |
| Strabismus | 50% | + |
| Hypermetropia | 50% | + |
| <i>Musculoskeletal</i> | | |
| Kyphosis | 20% | – |
| Lordosis | 40% | – |
| Radioulnar synostosis | 20% | + |
| Umbilical hernia | 50% | + |
| <i>Other</i> | | |
| Hoarse voice | + | + |
| Hyperacusis | 80% | – |

^aMorris *et al* 1988. *J Pediatr*.^bPober *et al* 2007. *Am J Med Genet C Semin Med Genet*.^cSee text for details.^dSelicorni *et al*, 2006. *Am J Med Genet A*.

RESULTS

Clinical findings

The proband, an 11-year-old boy, is the second child of healthy non-consanguineous Italian parents aged 38 years (father) and 33 years (mother). The parents have both secondary educational levels, displaying normal professional and social interactions; their cognitive assessment has not been performed, due to lack of collaboration. Paternal and maternal

heights are 180 cm and 172 cm respectively. Family history is unremarkable for mental retardation and/or congenital anomalies. He was born by spontaneous delivery without complications after 40 weeks of gestation. The pregnancy was complicated by uterine contractions from the 22nd week of gestation, controlled with rest and oral β -mimetic (Isoxsuprine). Birth weight, length and head circumference (OFC) were 2.830 kg (10th centile), 47.5 cm (3rd to 10th centile) and 34 cm (25–50th centile), respectively. Apgar scores were 9/9. He was breastfed, displaying a normal length and weight growth. During the first month of life an umbilical hernia was diagnosed, afterwards it spontaneously regressed. He was hospitalized for the persistence of a systolic heart murmur. A cardiology ultrasound examination unveiled a stenosis of the pulmonary valve with instantaneous pressure gradient (Δp) of 30 mm Hg, hemodynamically insignificant. Yearly echocardiography follow-up disclosed a mild SVAS (Δp 25 mm Hg) at 5 years of age. Hence the patient was referred to the pediatric-genetic clinic, where the association of the arterial abnormality with peculiar facial traits led to the clinical suspicion of WBS. The hypothesis was subsequently confirmed by cytogenetics analysis (see below). Spontaneous improvement of pulmonary valve stenosis and steadiness of SVAS have been documented by annual echocardiography follow-up.

Developmental milestones were reached at appropriate ages. He walked without support and spoke his first words at 13 and 15 months, respectively, showing a definitively normal motor development. The parents reported alteration of the normal 24 h sleep–wake cycle (sleep time 2000 hours to 0300 hours) and an outgoing personality consisting of increased approach to strangers and loquacity in early infancy. A cognitive assessment using the WPPSI test was performed at 6 years of age, revealing a normal full-scale IQ score of 105, although with an important difference between verbal IQ (117) and performance IQ (91). Particularly, he exhibited weaknesses on object assembly, geometric design and block design subtests, and strengths on vocabulary and similarities subtests (see Figure 1 for details). Remarkably, a mild impairment of ocular convergence and some hampering of fine motricity (the patient is left handed) were concurrently noted. The boy attended regular school with good results, without requiring specific teaching backup. An ophthalmologic assessment at 7 years of age revealed a hypermetropic astigmatism associated with convergent strabismus of the right eye. A concomitant evaluation by Developmental Test of Visual Perception (DTVP) disclosed an attention deficit and confirmed the light motricity impairment. A subsequent psychomotor evaluation, including DTVP, puzzles reproduction, block construction and drawing task, was performed after ocular anomalies correction. It revealed adequate results in ocular-motor integration, in hand-eye coordination and in visual perception. Moreover simple and complex ideomotor praxias resulted normal in movement programming and execution, but a slight weakness was observed in visual explorative and visual constructive performances (single scores not available). At the age of 11 years, the proband weight was 35 kg (50th centile), height 132 cm (5th centile), head circumference 51 cm (10th centile). Clinical evaluation disclosed bitemporal narrowing, broad forehead, short upturned nose with bulbous tip, long philtrum, full lips, bilateral clinodactyly of 5th fingers of the hands, hoarse voice, mild limitation of supination and pronation of the forearm, valgus flatfoot and knock knees. Echocardiography confirmed a hemodynamically insignificant mild SVAS (Δp 20 mm Hg). An elevation of serum TSH level (6.10 mUI/l, n.v. 0.4–4.4 mUI/l) with normal fT3 and fT4 levels was found; further analyses revealed antithyroid antibodies (antithyroid peroxidase, 342 kU/l, n.v. <40 kU/l), not associated with morphological abnormalities, leading to medical therapy with L-thyroxine. Screening for celiac disease was negative (quantitative serum IgA 163 mg/100 ml, antitissue transglutaminase IgA 0 IU/ml, antiendomysium IgA negative). Serum calcium (5.10 mEq/l), creatinine, cholesterol, triglyceride, liver enzymes, urinalysis, urinary

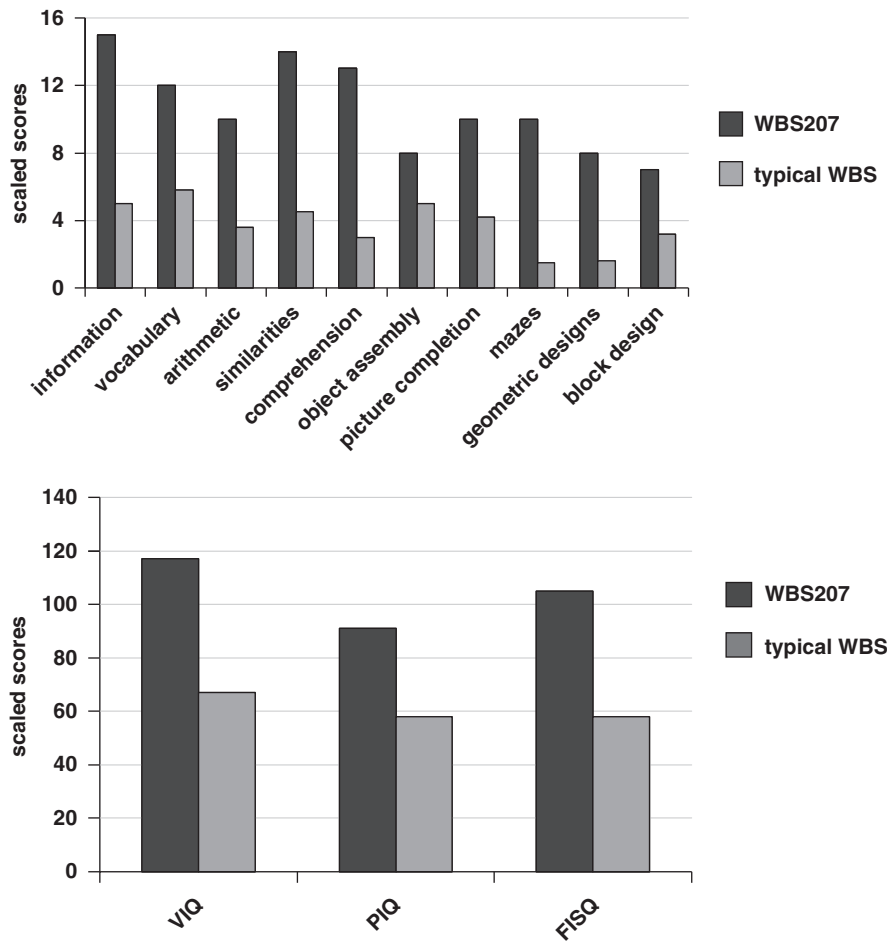


Figure 1 WBS207's scores on cognitive evaluation by WPPSI-R compared to WBS patients carrying typical deletion derived from Dai *et al* (VIQ, verbal IQ; PIQ, performance IQ; FISQ, full-scale IQ).³⁰

calcium, 24-hour ambulatory blood pressure monitoring (mean daytime blood pressure 109/72 mm Hg, mean nighttime blood pressure 100/63 mm Hg) and abdominal ultrasound examination completed by echo color Doppler ultrasound of renal vessels were all normal.

Neurological examination did not show any abnormalities. An updated cognitive and psychological assessment by specific tests could not be performed because of parental refusal. Nevertheless the proband is attending regular schooling, and teachers, unaware of the genetic diagnosis, never pointed out any learning difficulties. Moreover, he plays soccer in a nondisabled age-matched team, showing a normal social life for his age, overall. We had the opportunity to observe the patient during the entire day on the occasion of clinical follow-up appointment and we noted that the outgoing personality traits referred by the parents since 5 years of age completely disappeared as he did not display increased sociability or anxiety with peers and/or strangers and an adequate interaction was observed at clinical examination.

Deletion mapping by FISH and genomic QPCR

FISH analysis revealed a single signal in cells from proband WBS207, whereas control probes detected two signals on chromosome 7 (data not shown). To map the deletion breakpoints we used QPCR as described.²¹ The first set of assays detected hemizyosity for the genes comprised between *TBL2* and *CLIP2* but not for *BAZ1B* and *GTF2IRD1* (data not shown). To narrow down the centromeric and telomeric breakpoints, we designed new QPCR assays mapping to the *BAZ1B* and *CLIP2* loci,

respectively (Figure 2; Supplementary Table S1). The centromeric breakpoint maps between assay BAZ1B_17.002 (assay mapping in the third intron of *BAZ1B*) and assay BAZ1B_17.003 (fourth intron of *BAZ1B*) that are present in one and two copies, respectively. Thus *BAZ1B* is hemizygote for its transcription start site (TSS) and at least its first three exons. Note that both Ensembl release 50 (July 2008) and the UCSC Genome Browser do not report other more distal TSSs for that gene.

The telomeric breakpoint reaches the gene *CLIP2* but preserves the two copies of the adjacent *GTF2IRD1* and *GTF2I* genes. The boundary assays are 5_CYLN2 (intron 3 of *CLIP2*) and 4.13_CYLN2/GTF2IRD1 (intergenic region between *CLIP2* and *GTF2IRD1*), which are present in a single and two copies, respectively (Supplementary Table S1 and Figure 1). These analyses indicate that the WBS207 proband carries a deletion of less than 1 Mb (0.84–0.94 Mb) that maps to the core of the WBS critical region and excludes the *GTF2I*, *GTF2IRD1* and the 3' portion of the *BAZ1B* gene. The absence of the deletion in both parents, assayed by QPCR, indicated that the deletion occurred *de novo* (Figure 2).

DISCUSSION

We describe a patient with a ~1 Mb deletion in the WBS genomic interval. This atypical rearrangement is shorter than the classical deletion both at the centromeric and telomeric sides. Cytogenetic and molecular analyses showed that the proband carries a deletion that does not include *GTF2IRD1* and *GTF2I* at the telomeric end whereas the centromeric breakpoint lies between introns 3 and 4 of the *BAZ1B* gene (Figure 2). Even

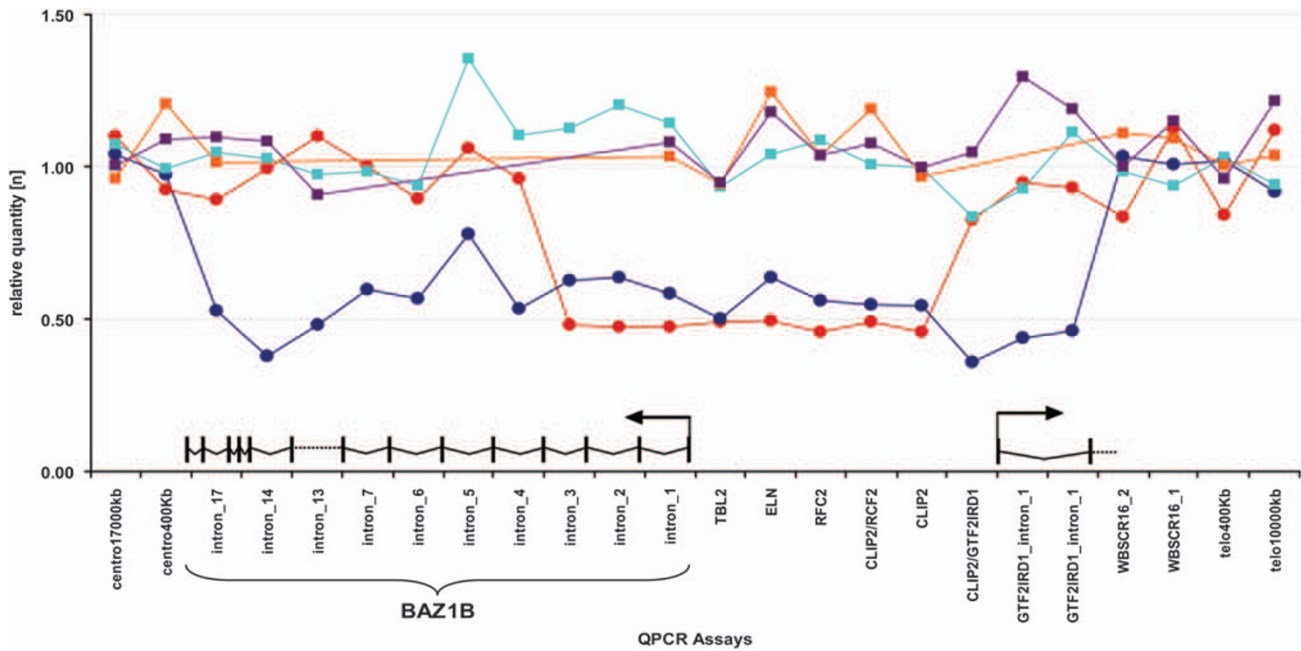


Figure 2 Mapping Williams–Beuren syndrome atypical deletion by QPCR. Relative DNA quantity was quantified for the WBS207 proband (red circles), his mother (orange squares) and father (purple squares), as well as an unaffected control (CNTL1, light blue squares) and a WBS patient carrying the classical deletion (WBS10, blue circles) at 24 human chromosome 7 loci (see Supplementary Table S1 for assay coordinates and primer sequences). The *BAZ1B* gene (bottom left side) and the two first exons of *GTF2IRD1* (bottom right side) are schematically represented. Note that patient WBS207 is hemizygous at least for the last 13 exons of *BAZ1B* (black rectangles), whereas both copies of *GTF2IRD1* are maintained.

if not formally proven, because of lack of mRNA for WBS207, the expression of the *BAZ1B* is probably affected because the most distally mapped transcriptional start site for that gene is hemizygous in our patient. Although we were partially prohibited by the parents to pursue in-depth cognitive profiling, the comparison of the phenotype of proband WBS207 with those of typical WBS patients revealed some interesting clues. From a phenotypic perspective, he does not present a striking facial gestalt of WBS. For instance, he does not present periorbital fullness, stellate iris, dental abnormalities and the malocclusion commonly observed in WBS patients. Similarly, he does not present hypercalcemia, feeding difficulties or other gastrointestinal abnormalities (see Table 1). The most interesting feature of WBS207 is the peculiar cognitive profile, characterized by a normal full-scale IQ (105), with a difference between verbal IQ (117) and performance IQ (91). He displayed strengths on all verbal subtests except for arithmetic and weaknesses on object assembly, geometric designs and block design subtests. He attends regular school without any support and does not present overfriendly personality, even though parents reported an increased approach to strangers and loquacity in early infancy.

Our data are in keeping with previous partial deletion studies (Figure 3). Specifically, the mild clinical phenotype and the cognitive profile seen in WBS 207 and the mapping of the breakpoints suggest a role for *CLIP2*, *GTF2IRD1* or *GTF2I* in some of the WBS facial features consistently with previous reports.^{14,21,24,26} In the past years, the identification of an increasing number of WBS with smaller than usual deletions of 7q11.23 shed light on the genetic bases of some of associated clinical features (Figure 3). From these studies, it has been argued, for example, that *CLIP2* hemizygosity contributes to motor coordination abnormalities.²⁷ Other reports suggested that the *GTF2I* and *GTF2IRD1* genes have dosage-dependent influences on craniofacial and neurological development and that hemizygosity for these genes appears to be associated with the general intellectual disability/mental retardation²² and/or visuospatial construction difficulties.^{19,21,24,28–30} Finally, further insights into genotype–phenotype correlations come from an intriguing report of an individual without

the abnormal motor behavior and the specific spatial and impaired visual–spatial capacities. Genetic analysis showed that this patient had a deletion that excluded the genes *RFC2*, *CLIP2*, *GTF2IRD1* and *GTF2I*.²⁷ Recently Korenberg’s group described a child with an atypical WBS deletion.³⁰ This female patient is hemizygote for *GTF2IRD1*, but the rearrangement does not include the more distal *GTF2I* gene. Her cognitive performance was overall remarkably above WBS typical range, but with striking deficits in visual–spatial construction (VSC). In addition, she did not show the typical overly social behavior seen in WBS individuals. These observations combine with previously published cases suggest that hemizygosity of the *GTF2IRD1* gene is associated with the WBS facial features and VSC deficits, whilst that of the *GTF2I* gene plays a crucial role in the genesis of the WBS social behavior. Together these studies indicated that the telomeric end of the WBS critical region contains genes that emerge as the most promising candidates for the cognitive, behavioral and neural phenotype seen in WBS patients. The detection of a normal full-scale IQ in our patient supports the previous assumptions that *GTF2IRD1* and *GTF2I* genes are crucial for WBS cognitive features.^{19,22,27–31} Nevertheless, we have to emphasize that our patient exhibits a peculiar discrepancy between verbal IQ and performance IQ, resembling the PIQ/VIQ ratio that has been reported in typical WBS patients.^{19,32,33} This finding seems contrary to previous reports of absent or minor visuospatial deficit in atypical WBS patients keeping *GTF2IRD1* and *GTF2I* genes.^{19,28,31} Nonetheless, WBS207 scores on performance subtests were heterogeneous because he exhibited difficulties in geometric designs but not in picture completion, even if both investigate VSC, and in object assembly and in block design, but not in mazes, even if all investigate visual–motor integration. Therefore, the low result of PIQ could be related to the ocular anomalies (hypermetropic astigmatism associated with convergent strabismus) in association to some hampering of his fine motricity. Unfortunately, an updated and in-depth cognitive assessment by specific tests could not be performed because of parental refusal. Moreover, as parental IQs were unavailable, we can’t exclude that the high VIQ score

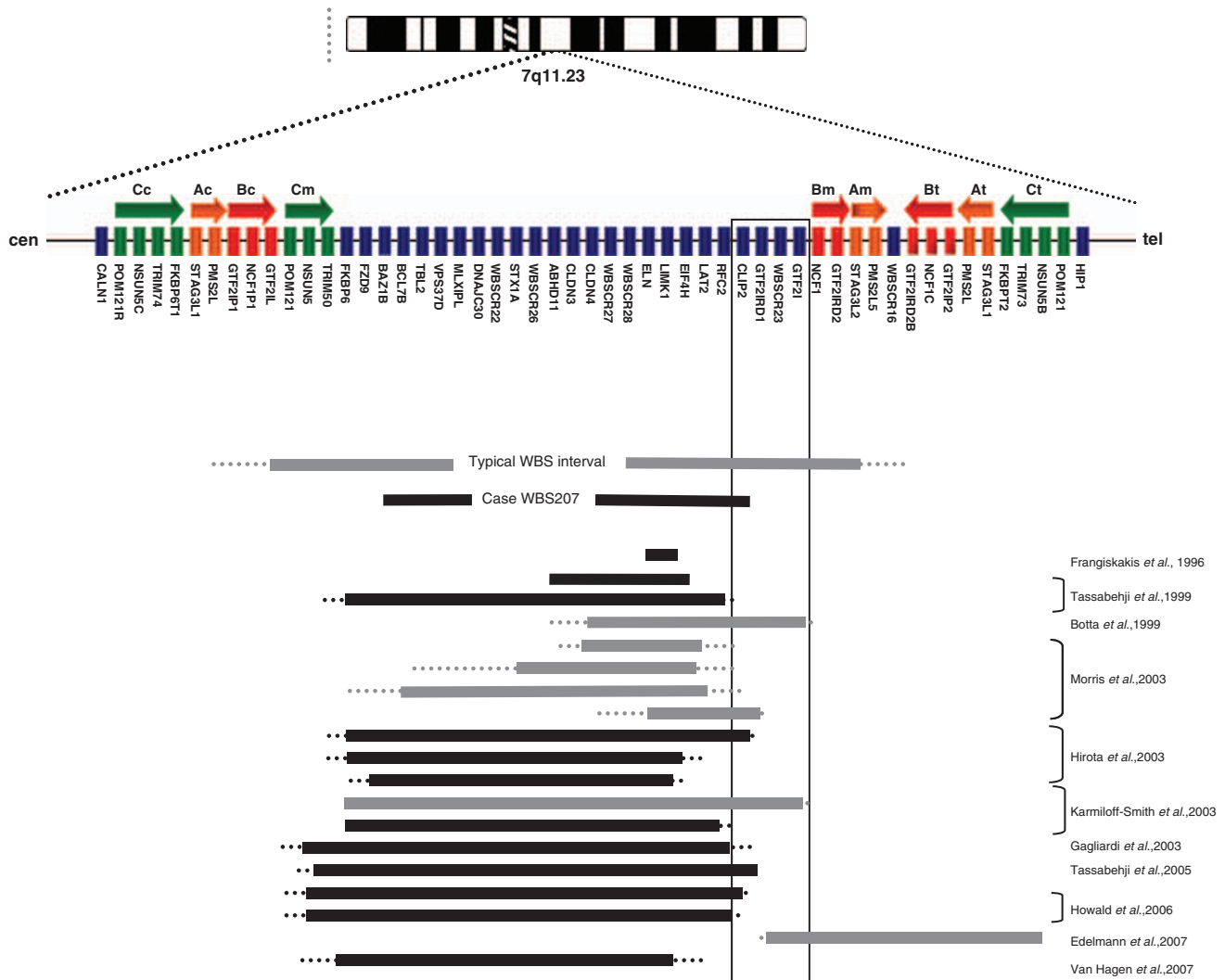


Figure 3 Summary of deletion mapping of WBS classical and atypical patients. Deletion mapping of WBS atypical cases defines a critical region for the WBS visual-spatial construction, cognition and social behavior (depicted by a vertical rectangle). A schematic representation of the genes mapping at 7q11.23 critical region is shown below the human chromosome pictogram. The thick horizontal arrows represent the three large blocks of low-copy repeats (LCRs), labeled A, B and C, with centromeric (c), medial (m) and telomeric (t) sequence indicated (see Bayes *et al.*¹ for details). The typical 1.54 Mb WBS deletion interval is depicted below as a solid line, whereas the extended boundaries of the rarer 1.84 Mb deletion are shown as dotted lines. Deletion mapping of WBS atypical patients reported in the literature are displayed below the WBS207 case. Gray bars represent deletions of WBS patients reported by authors with typical and well-documented WBS Cognitive Profile (WBSCP), whereas black bars represent deletions of WBS patients for whom the authors reported absent or not well-defined WBSCP.

results from high biological potential derived from high-functioning parents. Alternatively, the visual-spatial impairment showed by WBS207 could be explained by a long-range position effect of the deletion that modifies the physiologic expression of *GTF2IRD1* and/or *GTF2I* genes. Consistently, submicroscopic deletion and duplication were shown to modify the expression levels of some of their flanking genes.^{34–38} We could also not rule out the possibility that abnormally low levels of *LIMK1* combined with reduced levels of other proteins involved in brain function (eg *CLIP2*) could affect spatial impairment, as suggested previously.³⁵

GTF2I, *GTF2IRD1* and *GTF2IRD2* belong to the TFII-I gene family of transcription factors.³⁶ They interact promiscuously with multiple proteins and DNA and could, therefore, influence a broad range of neural physiological and developmental processes. *GTF2I* acts as a basal transcription factor that binds to initiator elements of various promoters and also regulates transcription through E-box elements at enhancers in response to upstream signaling events.³⁷ *GTF2IRD1* can bind regulatory elements upstream of genes involved in tissue development and differ-

entiation such as *HOXC8*, *GOOSECOID* and *TROPONIN I_{SLOW}*.^{38,39} The null mutants of the orthologous *Gtf2ird1* and *Gtf2i* genes have been generated.^{24,40,41} The deletion of *Gtf2ird1* by targeted insertion of a LacZ cassette in its second exon does not exhibit craniofacial dysmorphism or dental abnormalities.⁴¹ In contrast, a previous report, a mouse model with a deletion between *Clip2* and the first exon of *Gtf2ird1*, presented craniofacial abnormalities involving a misaligned jaw, a twisted snout and dental abnormalities.²⁴ The recently complete knockouts of the *Gtf2ird1* and *Gtf2i* genes demonstrated that mice heterozygous for these genes are often growth retarded and exhibit hypoplasia of the mandible, as well as other craniofacial defects reminiscent of the characteristic facial appearance and dental problems seen in WBS individuals.⁴⁰ Concomitantly a recent article showed that during mouse embryogenesis *Baz1b* is expressed strongly in the cranial neural crest-derived mesenchyme that drives facial morphogenesis. The reduction of the level of encoded protein was the source of an array of craniofacial features similar to those shown by typical WBS patients, such as a small upturned nose with flat nasal

bridge, micrognathia (or mandibular hypoplasia), malocclusion, bitemporal narrowing and prominent forehead.⁴² These results suggest that genes mapping at the proximal and the distal end of the WBS deletion could be implicated in the genesis of the typical elfin facies. We should, therefore, not exclude the possibility that some of the mild facial features seen in the WBS207 patient could result from *Baz1b* haploinsufficiency.

Our study confirms the utility of atypical patients for WBS genotype–phenotype correlation. The identification of more of those subjects with a careful comparison of their genetic, clinical and neuropsychological profiles will be needed and useful to assess the contribution of each gene to the WBS phenotype. We also underline the utility of QPCR as a feasible and reliable method to precisely map deletion breakpoints. This technique represents a valid cost-effective alternative to FISH and MLPA or other more expensive, although with higher resolution, methods such as array CGH.

KEY POINTS

- Williams–Beuren syndrome is caused by a 1.55 Mb hemizygous deletion on chromosome 7q11.23, a segment encoding 28 genes
- Genotype–phenotype correlation studies of few individuals with smaller deletions are useful to assess the contribution of each gene to the WBS phenotype
- The phenotype of the WBS207 atypical patient suggests that *GTF2IRD1* and/or *GTF2I* genes hemizygosity play(s) a role in the facial dysmorphisms and in the specific motor and cognitive deficits observed in WBS patients.

CONFLICT OF INTEREST

The authors declare no conflict of interest.

ACKNOWLEDGEMENTS

We are grateful to the family who participated in the study. This work was supported by grants from the Jérôme Lejeune Foundation, the Telethon Action Suisse Foundation, the Novartis Foundation, the Swiss National Science Foundation and the European commission (anEUplodidy grant 037627) to AR, by grants from the Italian Ministry of Health (Ricerca Corrente 2007–09), the Fondazione Banca del Monte di Foggia ‘Domenico Siniscalco Ceci’, the Italian Telethon Foundation (Grant N. GGP06122), the Jérôme Lejeune Foundation and Italian Foreign Office to GM, Compagnia di San Paolo and Fondazione CRT, Torino to GBF.

- Bayes M, Magano LF, Rivera N, Flores R, Perez Jurado LA: Mutational mechanisms of Williams–Beuren syndrome deletions. *Am J Hum Genet* 2003; **73**: 131–151.
- Cairo S, Merla G, Urbinati F, Ballabio A, Reymond A: WBS14, a gene mapping to the Williams–Beuren syndrome deleted region, is a new member of the Mlx transcription factor network. *Hum Mol Genet* 2001; **10**: 617–627.
- Merla G, Ucla C, Guipponi M, Reymond A: Identification of additional transcripts in the Williams–Beuren syndrome critical region. *Hum Genet* 2002; **110**: 429–438.
- Micale L, Fusco C, Augello B *et al*: Williams–Beuren syndrome TRIM50 encodes an E3 ubiquitin ligase. *Eur J Hum Genet* 2008; **16**: 1038–1049.
- Osborne LR, Mervis CB: Rearrangements of the Williams–Beuren syndrome locus: molecular basis and implications for speech and language development. *Expert Rev Mol Med* 2007; **9**: 1–16.
- Somerville MJ, Mervis CB, Young EJ *et al*: Severe expressive-language delay related to duplication of the Williams–Beuren locus. *N Engl J Med* 2005; **353**: 1694–1701.
- Osborne LR, Li M, Pober B *et al*: A 1.5 million-base pair inversion polymorphism in families with Williams–Beuren syndrome. *Nat Genet* 2001; **29**: 321–325.
- Tam E, Young EJ, Morris CA *et al*: The common inversion of the Williams–Beuren syndrome region at 7q11.23 does not cause clinical symptoms. *Am J Med Genet A* 2008; **146A**: 1797–1806.
- Stromme P, Bjornstad PG, Ramstad K: Prevalence estimation of Williams syndrome. *J Child Neurol* 2002; **17**: 269–271.
- Ferrero GB, Biamino E, Sorasio L *et al*: Presenting phenotype and clinical evaluation in a cohort of 22 Williams–Beuren syndrome patients. *Eur J Med Genet* 2007; **50**: 327–337.
- Bellugi U, Lichtenberger L, Jones W, Lai Z, St George M: I. The neurocognitive profile of Williams Syndrome: a complex pattern of strengths and weaknesses. *J Cogn Neurosci* 2000; **12** (Suppl 1): 7–29.
- Meyer-Lindenberg A, Mervis CB, Berman KF: Neural mechanisms in Williams syndrome: a unique window to genetic influences on cognition and behaviour. *Nat Rev Neurosci* 2006; **7**: 380–393.
- Selicorni A, Fratoni A, Pavesi MA, Bottigelli M, Arnaboldi E, Milani D: Thyroid anomalies in Williams syndrome: investigation of 95 patients. *Am J Med Genet A* 2006; **140**: 1098–1101.
- Tassabehji M: Williams–Beuren syndrome: a challenge for genotype–phenotype correlations. *Hum Mol Genet* 2003; **12** (Spec No 2): R229–R237.
- Marshall CR, Young EJ, Pani AM *et al*: Infantile spasms is associated with deletion of the MAGI2 gene on chromosome 7q11.23–q21.11. *Am J Hum Genet* 2008; **83**: 106–111.
- Francke U: Williams–Beuren syndrome: genes and mechanisms. *Hum Mol Genet* 1999; **8**: 1947–1954.
- Metcalfe K, Rucka AK, Smoot L *et al*: Elastin: mutational spectrum in supravalvular aortic stenosis. *Eur J Hum Genet* 2000; **8**: 955–963.
- Heller R, Rauch A, Luttgen S, Schroder B, Winterpacht A: Partial deletion of the critical 1.5 Mb interval in Williams–Beuren syndrome. *J Med Genet* 2003; **40**: e99.
- Hirota H, Matsuoka R, Chen XN *et al*: Williams syndrome deficits in visual spatial processing linked to GTF2IRD1 and GTF2I on chromosome 7q11.23. *Genet Med* 2003; **5**: 311–321.
- Hoogenraad CC, Koekkoek B, Akhmanova A *et al*: Targeted mutation of Cyn2 in the Williams syndrome critical region links CLIP-115 haploinsufficiency to neurodevelopmental abnormalities in mice. *Nat Genet* 2002; **32**: 116–127.
- Howald C, Merla G, Digilio MC *et al*: Two high throughput technologies to detect segmental aneuploidies identify new Williams–Beuren syndrome patients with atypical deletions. *J Med Genet* 2006; **43**: 266–273.
- Morris CA, Mervis CB, Hobart HH *et al*: GTF2I hemizygosity implicated in mental retardation in Williams syndrome: genotype–phenotype analysis of five families with deletions in the Williams syndrome region. *Am J Med Genet A* 2003; **123**: 45–59.
- Tassabehji M, Carette M, Wilmot C, Donnai D, Read AP, Metcalfe K: A transcription factor involved in skeletal muscle gene expression is deleted in patients with Williams syndrome. *Eur J Hum Genet* 1999; **7**: 737–747.
- Tassabehji M, Hammond P, Karmiloff-Smith A *et al*: GTF2IRD1 in craniofacial development of humans and mice. *Science* 2005; **310**: 1184–1187.
- Livak KJ, Schmittgen TD: Analysis of relative gene expression data using real-time quantitative PCR and the 2[−](Delta Delta C(T)) Method. *Methods* 2001; **25**: 402–408.
- Tassabehji M, Metcalfe K, Karmiloff-Smith A *et al*: Williams syndrome: use of chromosomal microdeletions as a tool to dissect cognitive and physical phenotypes. *Am J Hum Genet* 1999; **64**: 118–125.
- van Hagen JM, van der Geest JN, van der Giessen RS *et al*: Contribution of CYLN2 and GTF2IRD1 to neurological and cognitive symptoms in Williams Syndrome. *Neurobiol Dis* 2007; **26**: 112–124.
- Gagliardi C, Bonaglia MC, Selicorni A, Borgatti R, Giorda R: Unusual cognitive and behavioural profile in a Williams syndrome patient with atypical 7q11.23 deletion. *J Med Genet* 2003; **40**: 526–530.
- Edelmann L, Prosnitz A, Pardo S *et al*: An atypical deletion of the Williams–Beuren syndrome interval implicates genes associated with defective visuospatial processing and autism. *J Med Genet* 2007; **44**: 136–143.
- Dai L, Bellugi U, Chen XN *et al*: Is it Williams syndrome? GTF2IRD1 implicated in visual-spatial construction and GTF2I in sociability revealed by high resolution arrays. *Am J Med Genet A* 2009; **149A**: 302–314.
- Karmiloff-Smith A, Grant J, Ewing S *et al*: Using case study comparisons to explore genotype–phenotype correlations in Williams–Beuren syndrome. *J Med Genet* 2003; **40**: 136–140.
- Boddaert N, Mochel F, Meresse I *et al*: Parieto-occipital grey matter abnormalities in children with Williams syndrome. *Neuroimage* 2006; **30**: 721–725.
- Karmiloff-Smith A, Tyler LK, Voice K *et al*: Linguistic dissociations in Williams syndrome: evaluating receptive syntax in on-line and off-line tasks. *Neuropsychologia* 1998; **36**: 343–351.
- Merla G, Howald C, Henrichsen CN *et al*: Submicroscopic deletion in patients with Williams–Beuren syndrome influences expression levels of the nonhemizygous flanking genes. *Am J Hum Genet* 2006; **79**: 332–341.
- Gray V, Karmiloff-Smith A, Funnell E, Tassabehji M: In-depth analysis of spatial cognition in Williams syndrome: a critical assessment of the role of the LIMK1 gene. *Neuropsychologia* 2006; **44**: 679–685.
- Bayarsaihan D, Dunai J, Greally JM *et al*: Genomic organization of the genes Gtf2ird1, Gtf2i, and Ncf1 at the mouse chromosome 5 region syntenic to the human chromosome 7q11.23 Williams syndrome critical region. *Genomics* 2002; **79**: 137–143.
- Roy AL, Du H, Gregor PD, Novina CD, Martinez E, Roeder RG: Cloning of an inr- and E-box-binding protein, TFII-I, that interacts physically and functionally with USF1. *EMBO J* 1997; **16**: 7091–7104.
- Thompson PD, Webb M, Beckett W *et al*: GTF2IRD1 regulates transcription by binding an evolutionarily conserved DNA motif ‘‘GUCE’’. *FEBS Lett* 2007; **581**: 1233–1242.
- Chimge NO, Makeyev AV, Ruddle FH, Bayarsaihan D: Identification of the TFII-I family target genes in the vertebrate genome. *Proc Natl Acad Sci USA* 2008; **105**: 9006–9010.
- Enkhmandakh B, Makeyev AV, Erdenechimeg L *et al*: Essential functions of the Williams–Beuren syndrome-associated TFII-I genes in embryonic development. *Proc Natl Acad Sci USA* 2009; **106**: 181–186.
- Palmer SJ, Tay ES, Santucci N *et al*: Expression of Gtf2ird1, the Williams syndrome-associated gene, during mouse development. *Gene Expr Patterns* 2007; **7**: 396–404.
- Ashe A, Morgan DK, Whitelaw NC *et al*: A genome-wide screen for modifiers of transgene variegation identifies genes with critical roles in development. *Genome Biol* 2008; **9**: R182.

Supplementary Information accompanies the paper on European Journal of Human Genetics website (<http://www.nature.com/ejhg>)