

## LETTER TO THE EDITOR

## Treatment of acute fibrinous organizing pneumonia following hematopoietic cell transplantation with etanercept

*Bone Marrow Transplantation* (2017) 52, 141–143; doi:10.1038/bmt.2016.197; published online 15 August 2016

Infectious and non-infectious pulmonary complications are reported in 30–60% of all hematopoietic cell transplant (HCT) recipients and result in a high morbidity and mortality.<sup>1–3</sup> Non-infectious pulmonary complications encompass a heterogeneous group of conditions including chronic GvHD, frequently manifested as bronchiolitis obliterans and cryptogenic organizing pneumonia (COP), pulmonary edema, diffuse alveolar hemorrhage and idiopathic pneumonia syndrome.<sup>1</sup> Acute organizing fibrinous pneumonia (AFOP) was first described by Beasley *et al.*<sup>3</sup> in 2002 as a unique histological pattern of acute lung injury that is histologically different from diffuse alveolar damage, eosinophilic pneumonia, bronchiolitis obliterans and COP. AFOP is recognized in the classification of idiopathic interstitial pneumonias as a rare histological pattern differentiated from other causes of acute lung injury by a histologic pattern of diffuse alveolar damage and organizing pneumonia with intra-alveolar fibrin within the alveolar space without hyaline membranes.<sup>4</sup> AFOP is a rare presentation of acute lung injury and the etiology is unknown. AFOP has been described in patients to be caused by idiopathic, drug associated (decitabine, amiodarone, abacavir), collagen vascular disease (systemic lupus erythematosus), infectious (Whipple disease) and occurring following HCT. To date there is only one documented case of AFOP following allogeneic HCT. Unfortunately, the patient died after treatment with methylprednisolone.<sup>5</sup> Here, we describe the first reported case of AFOP following HCT successfully treated with etanercept, suggesting TNF in the pathogenesis of AFOP.

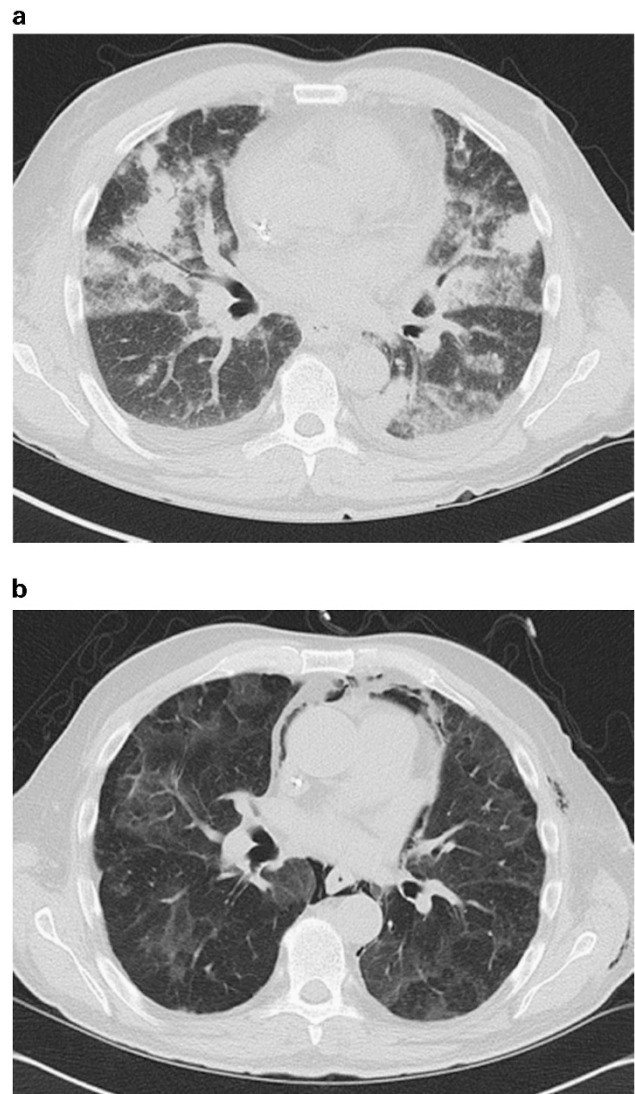
A 52-year-old male was diagnosed with stage IV angioimmunoblastic T-cell lymphoma with bone marrow involvement in 2011. He was originally treated with CHOP x6. Owing to refractory lymphoma, he received salvage ifosfamide, carboplatin, etoposide x2, a clinical trial with high-dose cyclosporine discontinued due to seizures, and reached a partial response with seven cycles of romidepsin before matched unrelated donor hematopoietic cell transplant (HCT). His conditioning regimen was reduced intensity with rabbit anti-thymocyte globulin, 2.5 mg/kg from day –9 to –7 followed by TBI to a total dose of 4.5 Gy, delivered in three 1.5 Gy fractions on day –1 to 0. For GvHD prophylaxis, he received tacrolimus and mycophenolate.

His post-transplant course was uncomplicated by day +180. His days +60 and +100 bone marrow, blood and T cells were 100% donor and no evidence of disease recurrence was found on radiographic imaging. Pulmonary function testing day +100 revealed a FEV1 of 93% and DLCO of 78%; pre-transplant FEV1 and DLCO were 93 and 80%, respectively. The patient had mild classic chronic GvHD of skin and eyes treated with topical hydrocortisone and Refresh eye drops. He was off immunosuppression by day +168. He started his vaccination protocol on day +240 for meningococcal, haemophilus influenza type B, influenza, pneumococcal 13, Hepatitis A and B, inactivated polio and Dtap.

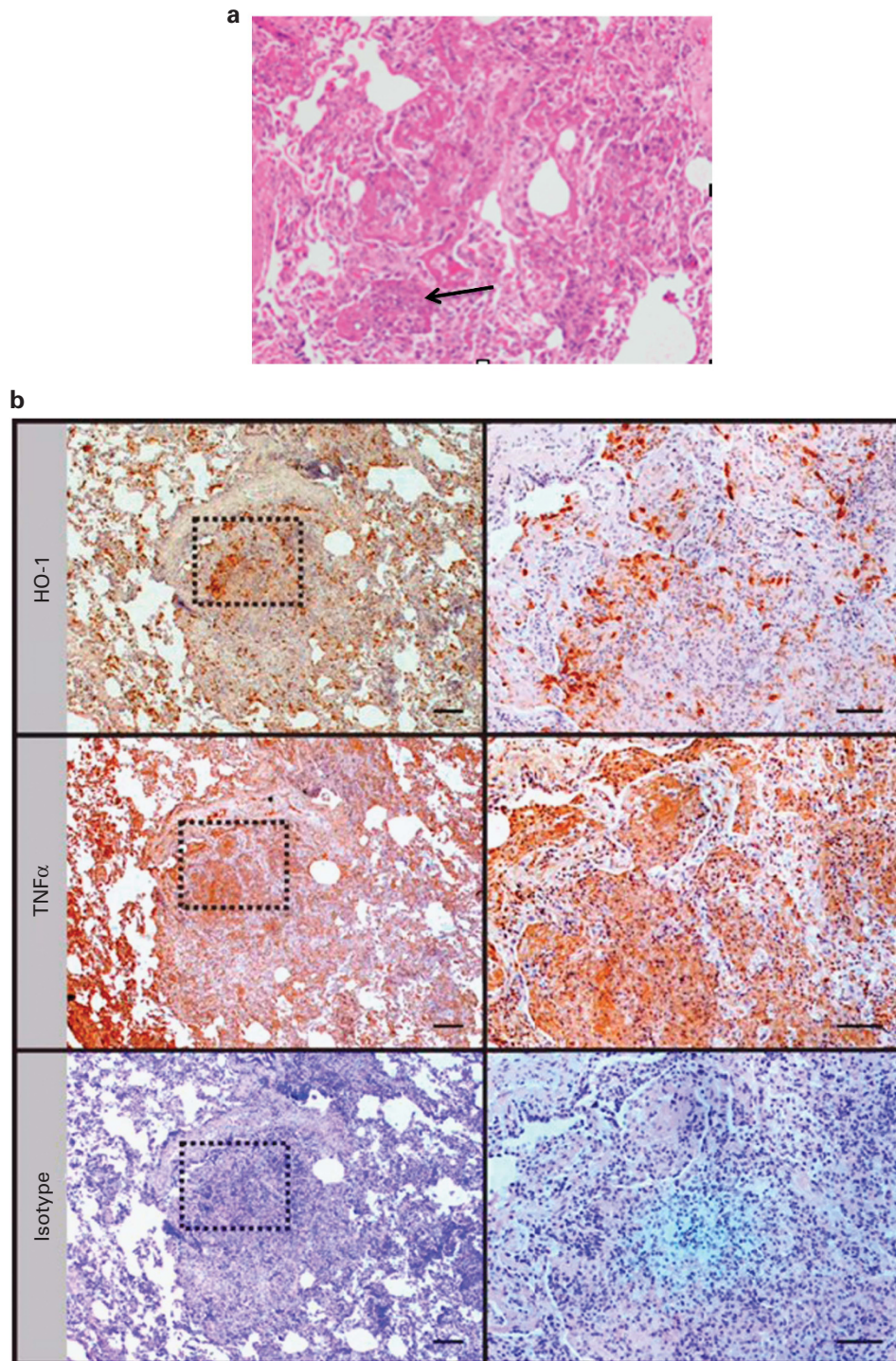
On day +325 after transplant he presented to the outpatient bone marrow transplant clinic with subacute cough, dyspnea, hypoxemia and no other clinical symptoms of GvHD. Pulse oximetry showed oxygen saturations of 68% on room air.

Computed tomography (CT) of the chest showed rapidly progressive pulmonary infiltrates (Figure 1a). He was admitted to the inpatient bone marrow transplant floor, started on broad-spectrum antimicrobials, and subsequently underwent bronchoscopy that was non-diagnostic. Over the next 2 days he developed worsening hypoxemia requiring transfer to the medical intensive care unit for hypoxemic respiratory failure. High-dose methylprednisolone 125 mg every 6 h was initiated. On day +328 he underwent video-assisted thoracoscopic surgery (VATS) and left upper lobe/left lower lobe wedge resection.

He was extubated on day +329, but remained hypoxic, requiring non-invasive ventilation. On day +331 the pathology from the wedge resections showed Acute organizing fibrinous



**Figure 1.** CT of chest. (a) Day +325. (b) Day +364.



**Figure 2.** Lung Biopsy with pathology of AFOP. (a) Arrow shows fibrin ball (b) HO-1, TNF- $\alpha$  and controls at 25x and 100x. Samples were deparaffinized and rehydrated. Ag retrieval was performed with 0.01 M citrate buffer (pH6.0) for 20 min. Then endogenous peroxidase was blocked with 3% H<sub>2</sub>O<sub>2</sub>/PBS for 5 min. Tissue samples were blocked in 1% normal swine serum (NSS) for 15 min, before incubation with primary antibodies for TNF $\alpha$  (clone 2C8, Novus Biologicals, Littleton, CO, USA) 670  $\mu$ g/mL or HO-1 (clone HO-1-1, Enzo Life Sciences, Farmingdale, NY, USA) 20  $\mu$ g/mL overnight in 1% normal swine serum/PBS. Next day, sections were stained with biotinylated secondary goat anti mouse Ab (1:1500, Millipore, Darmstadt, Germany) for 1 h followed by streptavidin/HRP solution (Vector laboratories, Burlingame, CA, USA) 1:200 for 45 min. Samples were stained with DAB chromogen (Dako, Carpinteria, CA, USA) and counterstained with Mayer's hematoxylin. Negative staining with isotype Ab run in parallel.

pneumonia (AFOP) (Figure 2a). Given the lack of clinical improvement, methylprednisolone was increased from 125 to 250 mg every 6 h, tacrolimus was continued (goal trough level 10) and we started etanercept 25 mg SC twice weekly for a total of

eight doses. After the initiation of etanercept the patient had significant improvement in respiratory status. His hypoxemia improved, he was off non-invasive ventilation after two days and supplemental oxygen was rapidly weaned. He completed 8 doses



of etanercept; continued tacrolimus and steroids were tapered off over 2 weeks. His VATS was complicated by pneumothorax and pneumomediastinum, which required small bore thoracostomy placement and eventually mechanical pleurodesis due to persistent air leak. On day +364 he was discharged home off supplemental oxygen with significant clinical and radiographic improvement (Figure 1b). His post hospitalization FEV1 was 72% and DLCO was 58%.

Currently, the patient is 2.5 years from HCT and remains in remission from his lymphoma; he is on tacrolimus and twice weekly every other week extracorporeal photopheresis for GVHD as a steroid sparing agent that was started after day +364 upon discharge from the hospital. Prednisone was discontinued at day +393. He has had no other symptoms of GVHD except for an erythematous rash on day +519. He was started on 20 mg of prednisone, which was tapered off by day +756. He is off supplemental oxygen and recent CT scans reveal mild air trapping, however, a significant improvement from prior CT scans and his spirometry is normal, FEV1 (96%) and DLCO 89.

AFOP has been reported post allogeneic HCT and has two subtypes, one indolent and one very aggressive that carries a high morbidity (as in our patient). The pathogenesis of AFOP is unknown, but our patient's response to etanercept suggests a role of TNF- $\alpha$  as part of a cytokine-modulated immune response causing inflammation and fibrosis. Hara *et al.* report two cases of AFOP in non-HCT transplant patients. They demonstrated overexpression of heme oxygenase-1 (HO-1) in the macrophages within the fibrin balls and type II pneumocytes.<sup>6</sup> In another study, Terry *et al.* demonstrated that the inflammatory cytokines IL-1 and TNF- $\alpha$  are effective inducers of HO-1 in vascular endothelial cells and oxidative stress is implicated in the pathogenesis of many pulmonary diseases associated with inflammation, including acute respiratory distress syndrome.<sup>7</sup> Therefore, the initial insult/injury could have led to increased TNF- $\alpha$  and HO-1 that have been described in AFOP.

Murine models of induced pluripotent stem (IPS) after HCT, suggest the lung is a target of immune-mediated injury by two distinct and related pathways involving soluble inflammatory effectors including TNF- $\alpha$  and the other driven by antigen specific donor T-cell effectors, which synergize to cause inflammation and cellular injury.<sup>8</sup> Etanercept has been used as a treatment in transplant-related lung injury after HCT with 24% of patients surviving hospital stay.<sup>9</sup> Yanik *et al.* studied the TNF inhibitor, etanercept, combined with corticosteroids in treating 15 patients with IPS after HCT. Etanercept was administered SC at a dose of 0.4 mg/kg (maximum 25 mg) twice weekly, for a maximum of eight doses.<sup>10</sup> Therapy was well tolerated and 10 of 15 patients had a complete response, defined as the ability to discontinue supplemental oxygen support during study therapy. The 28-day survival was 73%. The combination of etanercept and corticosteroids is safe and is associated with high response rates and improved survival in patients with IPS after HCT.<sup>10</sup>

To our knowledge this is the first case AFOP after HCT, successfully treated with etanercept. Although, there is a lack of clinical evidence to support the use of etanercept in patients with AFOP. Our rationale for the use of etanercept in this critically ill patient with a non-infectious lung injury was that AFOP may be driven by oxidative stress, which may be modulated by TNF- $\alpha$ . Interestingly, the lung biopsy was positive for both HO-1 and TNF- $\alpha$  (Figure 2b). This supports our hypothesis that AFOP may be driven by oxidative stress induced by TNF- $\alpha$ . Therefore, we propose that etanercept may be responsible for the marked clinical improvement in the patient because with high-dose steroids and tacrolimus the patient was requiring non-invasive ventilation and high-flow oxygen 15 L nasal canula until the addition of etanercept. We speculate that AFOP is a manifestation of GvHD, and that TNF- $\alpha$  is implicated in its pathogenesis. Until

more information is available on the pathogenesis of AFOP after HCT, we recommend early use of etanercept in patients with AFOP post HCT because of rapidly progressive respiratory failure and high mortality.

## CONFLICT OF INTEREST

The authors declare no conflict of interest.

## AUTHOR CONTRIBUTIONS

Manuscript was written by GLS and WBC, KM and WBC were both senior authors.

GL Simmons<sup>1</sup>, HM Chung<sup>1</sup>, JM McCarty<sup>1</sup>, AA Toor<sup>1</sup>, D Farkas<sup>2</sup>, K Miller<sup>2</sup> and WB Clark<sup>1</sup>

<sup>1</sup>Department of Internal Medicine, Division of Hematology/Oncology and Palliative Care, Virginia Commonwealth University, Bone Marrow Transplant Program, Richmond, VA, USA and

<sup>2</sup>Department of Internal Medicine, Division of Pulmonary and Critical Care Medicine, Virginia Commonwealth University, Richmond, VA, USA

E-mail: William.clark@vcuhealth.org

## REFERENCES

- Cordonnier C, Bernaudin JF, Bierling P, Huet Y, Vernant JP. Pulmonary complications occurring after allogeneic bone marrow transplantation. A study of 130 consecutive transplanted patients. *Cancer* 1986; **58**: 1047–1054.
- Palmas A, Tefferi A, Myers JL, Scott JP, Swensen SJ, Chen MG *et al.* Late-onset noninfectious pulmonary complications after allogeneic bone marrow transplantation. *Br J Haematol* 1998; **100**: 680–687.
- Beasley MB, Franks TJ, Galvin JR, Gochuico B, Travis WD. Acute fibrinous and organizing pneumonia: a histological pattern of lung injury and possible variant of diffuse alveolar damage. *Arch Pathol Lab Med* 2002; **126**: 1064–1070.
- Travis WD, Costabel U, Hansell DM, King TE Jr, Lynch DA, Nicholson AG *et al.* An official American Thoracic Society/European Respiratory Society statement: update of the international multidisciplinary classification of the idiopathic interstitial pneumonias. *Am J Respir Crit Care Med* 2013; **188**: 733–748.
- Lee SM, Park JJ, Sung SH, Kim Y, Lee KE, Mun YC *et al.* Acute fibrinous and organizing pneumonia following hematopoietic stem cell transplantation. *Korean J Intern Med* 2009; **24**: 156–159.
- Hara Y, Shinkai M, Kanoh S, Kawana A, Rubin BK, Matsubara O *et al.* Clinico-pathological analysis referring hemeoxygenase-1 in acute fibrinous and organizing pneumonia patients. *Respir Med Case Rep* 2015; **14**: 53–56.
- Terry CM, Clikeman JA, Hoidal JR, Callahan KS. TNF- $\alpha$  and IL-1 $\alpha$  induce heme oxygenase-1 via protein kinase C, Ca<sup>2+</sup>, and phospholipase A2 in endothelial cells. *Am J Physiol* 1999; **276**: H1493–H1501.
- Shankar G, Bryson JS, Jennings CD, Morris PE, Cohen DA. Idiopathic pneumonia syndrome in mice after allogeneic bone marrow transplantation. *Am J Respir Cell Mol Biol* 1998; **18**: 235–242.
- Hohlfelder BA, Anger KE, Szumita PM, Degrado JR. Etanercept for the treatment of transplantation-related lung injury after hematopoietic stem cell transplantation. *Am J Ther* (e-pub ahead of print 13 August 2015; doi:10.1097/MJT.0000000000000315).
- Yanik GA, Ho VT, Levine JE, White ES, Braun T, Antin JH *et al.* The impact of soluble tumor necrosis factor receptor etanercept on the treatment of idiopathic pneumonia syndrome after allogeneic hematopoietic stem cell transplantation. *Blood* 2008; **112**: 3073–3081.



This work is licensed under a Creative Commons Attribution-NonCommercial-NoDerivs 4.0 International License. The images or other third party material in this article are included in the article's Creative Commons license, unless indicated otherwise in the credit line; if the material is not included under the Creative Commons license, users will need to obtain permission from the license holder to reproduce the material. To view a copy of this license, visit <http://creativecommons.org/licenses/by-nc-nd/4.0/>

© The Author(s) 2017