FG Ahfat[1] and CH Yuen[2]

[1]Maidstone General Hospital, Hermitage Lane
Maidstone, Kent ME16 9QQ

[2]CP Groenewald, St Paul's Eye Unit
Royal Liverpool University Hospital, Prescot Street
Liverpool L7 8XP

Correspondence: FG Ahfat
Tel: 01622 729000
E-mail: ahfat99@hotmail.com

Eye (2005) **19,** 218–219. doi:10.1038/sj.eye.6701468
Published online 30 July 2004

Sir,

Multifocal electroretinogram and optical coherence tomography of commotio retinae and traumatic macular hole

Blunt trauma like football injury may result in commotio retinae and traumatic macular hole.[1,2] Persistent visual impairment may occur in severe cases of commotio retinae due to damage to the photoreceptors or retinal pigment epithelia. We report the use of multifocal electroretinogram (mfERG) and optical coherence tomography (OCT) in a patient with commotio retinae and traumatic macular hole following blunt ocular injury. To our knowledge, there has been no previous report in the literature on the mfERG findings following commotio retinae.

Case report

A 24-year-old man presented with left eye visual loss after blunt injury by a football. On examination, his visual acuity was 6/6 for the right eye and hand movement for the left eye. There was 2 mm hyphema with mild vitreous haemorrhage in the left eye. Fundus examination showed a localised area of commotio retinae at the superionasal part of the macula. At 2 weeks after the injury, the hyphema and vitreous haemorrhage resolved, and his left eye visual acuity improved to 6/36. He noted a relative scotoma at the inferiotemporal visual field. Fundus examination showed an area of mild retinal pigment epithelial atrophy at the site of the commotio retinae. OCT imaging revealed a 100 μm full thickness traumatic macular hole (Figure 1a).

Automated visual field testing detected a relative inferionasal scotoma. MfERG demonstrated reduction in retinal response density at the central macula with a well-demarcated area of depressed retinal response density in the superionasal part of the macula (Figure 1b).

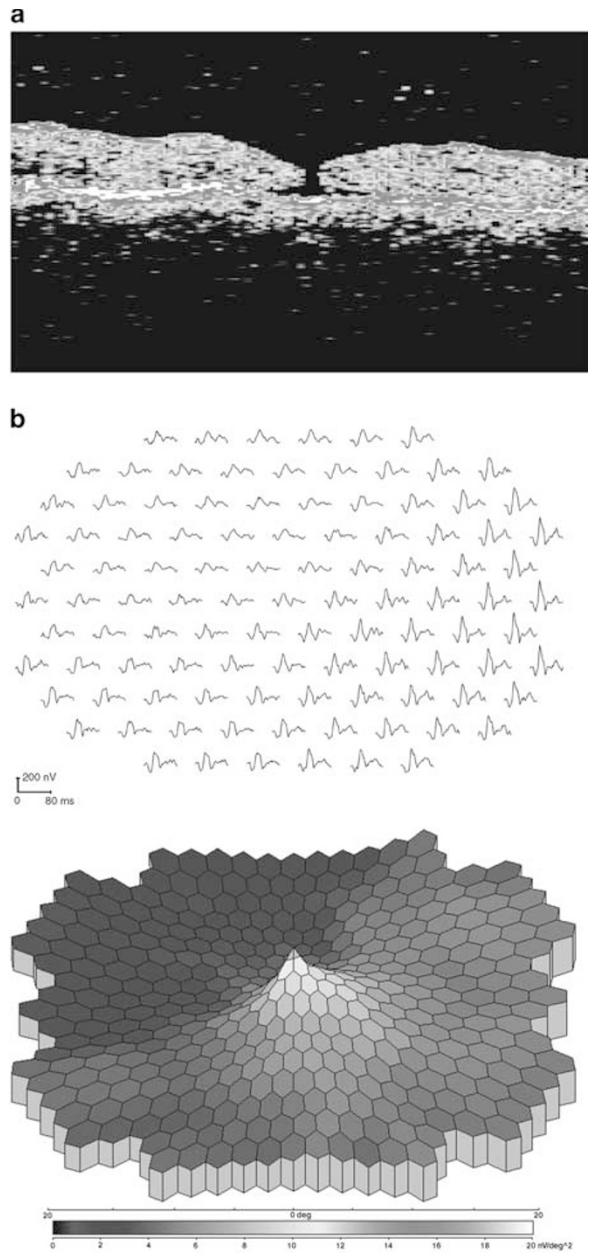

Figure 1 (a) Optical coherence tomography of the left eye 3 weeks after injury showing a full thickness macular hole of 100 μm in size. (b) Trace array and three-dimensional topography of the multifocal electroretinogram of the left eye showing reduced retinal response density at the central macula due to the traumatic macular hole. There was also a well-demarcated area of reduced retinal response density at the superionasal part of the macula corresponding to the area of commotio retinae.

In view of the small size of the traumatic macular hole, he was observed and surgery was not performed. At 6 weeks after the injury, the left eye visual acuity improved to 6/9. OCT demonstrated spontaneous closure of the macular hole (Figure 2a). At 18 months after the injury, his left eye vision recovered to 6/6 but he still complained of a relative scotoma at the inferiotemporal field. MfERG showed recovery of the retinal response density at the central macula due to closure of the macular hole (Figure 2b). However, the well-demarcated area of depressed retinal response in the superionasal macula persisted secondary to the damage associated with commotio retinae.

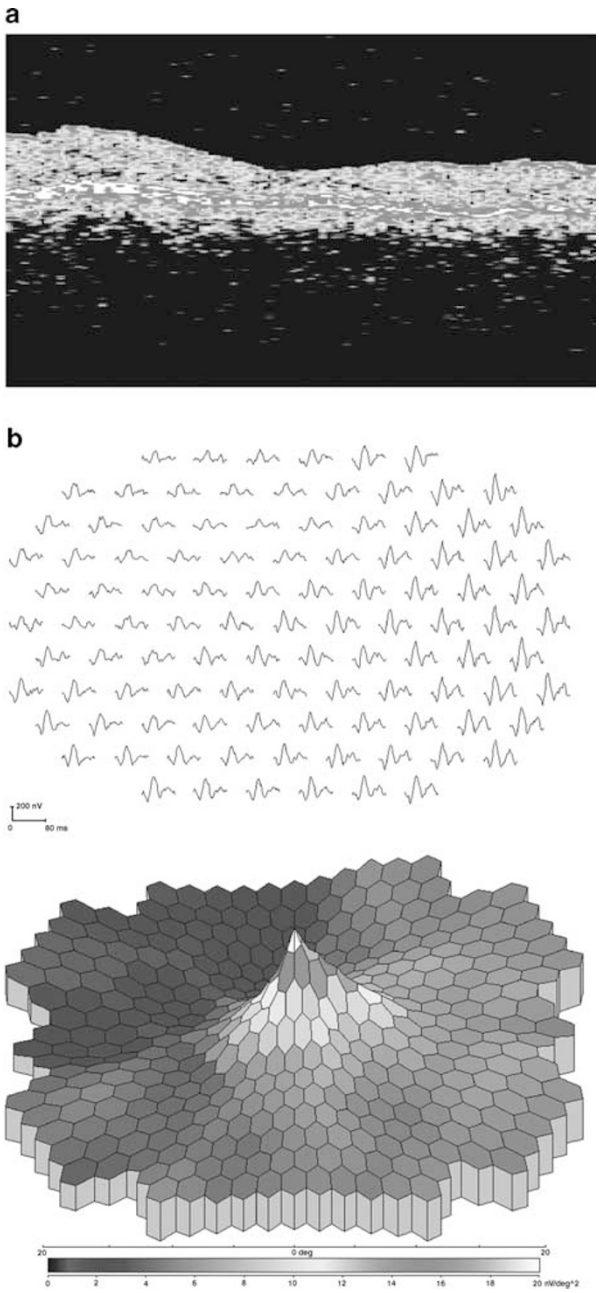

Figure 2 (a) Optical coherence tomography of the left eye 6 weeks after injury showing spontaneous closure of the macular hole. (b) Trace array and three-dimensional topography of the multifocal electroretinogram of the left eye 18 months after the injury demonstrating recovery of the retinal response density at the central macula due to spontaenous closure of the traumatic macular hole. The well-demarcated area of reduced retinal response density at the superionasal part of the macular persisted secondary to permanent loss of photoreceptors following the blunt trauma.

Comment

Previous studies have utilised OCT imaging in documenting the natural progression and spontaneous closure of traumatic macular holes anatomically.[2–4] However, the changes in retinal functions following traumatic macular hole could not be assessed using OCT. MfERG is an objective tool that has been used to evaluate retinal function in various macular disorders including idiopathic macular holes and X-linked juvenile retinoschisis.[5,6] The use of mfERG in our patient enabled us to demonstrate objectively the functional improvement after spontaneous closure of the traumatic macular hole as illustrated by the recovery of the retinal response amplitude at the central macula.

Histological study of commotio retinae in primate models has demonstrated that disruption and degeneration of photoreceptor outer segments may occur after blunt ocular injury.[7] As observed in our patient, the inferiotemporal visual field defect which persisted after the injury corresponded to the area of the commotio retinae. This was confirmed objectively by the well-demarcated reduction in retinal response density in the mfERG. The mfERG findings in our patient supported the suggestion that permanent visual loss following commotio retinae may occur due to permanent loss of photoreceptors. We believe that OCT and mfERG are valuable tools for assessing the anatomical alterations and functional changes of the retina, respectively, in patients after blunt ocular trauma.

References

1 Capao Filipe JA, Fernandes VL, Barros H, Falcao-Reis F, Castro-Correia J. Soccer-related ocular injuries. *Arch Ophthalmol* 2003; **121**: 687–694.
2 Ismail R, Tanner V, Williamson TH. Optical coherence tomography imaging of severe commotio retinae and associated macular hole. *Br J Ophthalmol* 2002; **86**: 473–474.
3 Yamashita T, Uemara A, Uchino E, Doi N, Ohba N. Spontaneous closure of traumatic macular hole. *Am J Ophthalmol* 2002; **133**: 230–235.
4 Yamada H, Sakai A, Yamada E, Nishimura T, Matsumura M. Spontaneous closure of traumatic macular hole. *Am J Ophthalmol* 2002; **134**: 340–347.

5 Si YJ, Kishi S, Aoyagi K. Assessment of macular function by multifocal electroretinogram before and after macular hole surgery. *Br J Ophthalmol* 1999; **83**: 420–424.
6 Muscat S, Fahad B, Parks S, Keating D. Optical coherence tomography and multifocal electroretinography of X-linked juvenile retinoschisis. *Eye* 2001; **15**: 796–799.
7 Sipperley JO, Quigley HA, Gass DM. Traumatic retinopathy in primates. The explanation of commotio retinae. *Arch Ophthalmol* 1978; **96**: 2267–2273.

TYY Lai, WWK Yip, VWY Wong and DSC Lam

Department of Ophthalmology and Visual Sciences
The Chinese University of Hong Kong
Hong Kong Eye Hospital, 147K, Argyle Street
Hong Kong, People's Republic of China

Correspondence: TYY Lai
Tel: +852 2762 3000
Fax: +852 2714 3922
E-mail: tyylai@netvigator.com

Eye (2005) **19,** 219–221. doi:10.1038/sj.eye.6701462
Published online 16 July 2004

Sir,

Bilateral acute uveitis and conjunctivitis after zoledronic acid therapy

We report a case of severe, bilateral fibrinous anterior uveitis with concurrent bilateral conjunctivitis following administration of intravenous zoledronic acid for the treatment of a monoclonal gammopathy of undetermined significance (MGUS).

Case study

A 62-year-old lady, with no ophthalmic history, had been under the care of the haematologists for 6 months for an MGUS with paraprotein levels of 3.3 g/l. and a slightly reduced IgM level (0.39). She began to suffer increasing pain in her back and femur with spontaneous bruising so a skeletal survey was performed, which revealed no localised bony pathology and the decision was made to administer zoledronic acid 4 mg IV. At 48 h after administration, she developed severe blurring of vision associated with pain and swelling of both eyelids—at this point, she was administered chloramphenicol ointment. The situation continued to deteriorate and 5 days after administration of zoledronic acid, she presented to the ophthalmic clinic with a best-corrected visual acuity of 6/60 bilaterally. She had severe chemosis in both eyes, especially of the lower fornix, and bilateral fibrinous uveitis with no hypopyon. Her intraocular pressures were 19 bilaterally and medium sized keratic precipitates were noted on the cornea. There was no evidence of any involvement of the vitreous and there was no abnormality of the retina. On dilation, posterior synechiae were noted, particularly in the left eye—Figure 1, which were broken after a short period of intensive dilation. The chloramphenicol treatment was discontinued and the patient was started on intensive Prednisolone Forte with regular 1% cyclopentolate. Over the following 10 days—with no further zoledronic acid treatment—the situation improved to no anterior chamber activity and the conjunctivitis settled completely. Best-corrected visual acuity is now 6/18 right and 6/12 left.

Comment

MGUS is found in approximately 3% of those older than 70 years. It is a plasma cell proliferative disorder and the diagnosis implies the presence of a monoclonal protein without evidence of multiple myeloma, macroglobulinaemia or amyloidosis. Patients have a 1% per year risk of converting to a malignant monoclonal gammopathy—multiple myeloma.[1]

Zoledronic acid belongs to the bisphosphonate class of drugs, which are used to treat bone diseases characterised by increased osteoclastic bone resorption. Ophthalmologic adverse effects of bisphosphonate therapy are infrequent, with conjunctivitis being a recognised side effect. Severe anterior uveitis has been reported with other members of this drug family—alendronate,[2,3] pamidronate[4]—but never

Figure 1 On dilation, posterior synechiae were noted, particularly in the left eye.