Correspondence: B Chang
Tel: +353 1 664 4600
Fax: +353 1 868 4681
E-mail: benchang@eircom.net

Eye (2004) **18,** 653–656. doi:10.1038/sj.eye.6700730
Published online 9 January 2004

Sir,

Massive subretinal haemorrhage secondary to age-related macular degeneration in a patient with idiopathic thrombocytopenic purpura

Idiopathic thrombocytopenic purpura (ITP) is a condition characterized by persistently low platelet counts, resulting from accelerated platelet destruction mediated by antiplatelet antibody. As ocular complication with ITP, hemianopia caused by intracranial haemorrhage, intraretinal haemorrhage caused by anaemia are reported.[1,2] An association between age-related macular degeneration (AMD) and ITP has not been reported to our knowledge. We describe a rare association between severe subretinal haemorrhage and ITP. Our case demonstrates that close ophthalmologic examination is very important in ITP.

Case report

A 73-year-old woman experienced a sudden loss of vision in the left eye and are referred to our macular clinic for a detailed examination. She had been followed up for exudative AMD and received cataract surgery with intraocular lens implantation at the age of 66 years. During the referring physician's recent observation, the visual acuity of the left eye was 0.1–0.3. Ophthalmoscopic examination (Figure 1a), fluorescein angiography, (Figure 1b) and indocyanine green angiography (Figure 1c) reavealed a persistent occult choroidal neovascular membrane not suitable for treatment. She also had a systemic previous history of diabetes mellitus, hypertension, and ITP. The platelet count was 7000/mm^3. On our ophthalmologic examination, the visual acuity became 30 cm hand movements. The dilated fundus examination of the left eye revealed 7×10 disc diameter (DD) submacular haemorrhage (Figure 1d). Although fluorescein angiography failed to detect the cause of haemorrhage, indocyanine green angiography (ICG) disclosed a hyperfluorescent lesion indicative of choroidal neovascularization (CNV). Observation was recommended. After 1 month, massive haemorrhage developed so rapidly that it reached the posterior capsule of the lens as disclosed by B-mode ultrasonography (Figure 1e) and slit-lamp biomicroscopy (Figure 1f). The visual acuity dropped to light perception. Within the following week, the patient revisited us claiming of severe headache. The visual acuity was no light perception. The ocular pressure of the left eye was 63 mmHg. Slit-lamp examination showed a narrow anterior chamber, and dilated fundus examination and B-mode ultrasonography revealed total retinal detachment (Figure 1g).

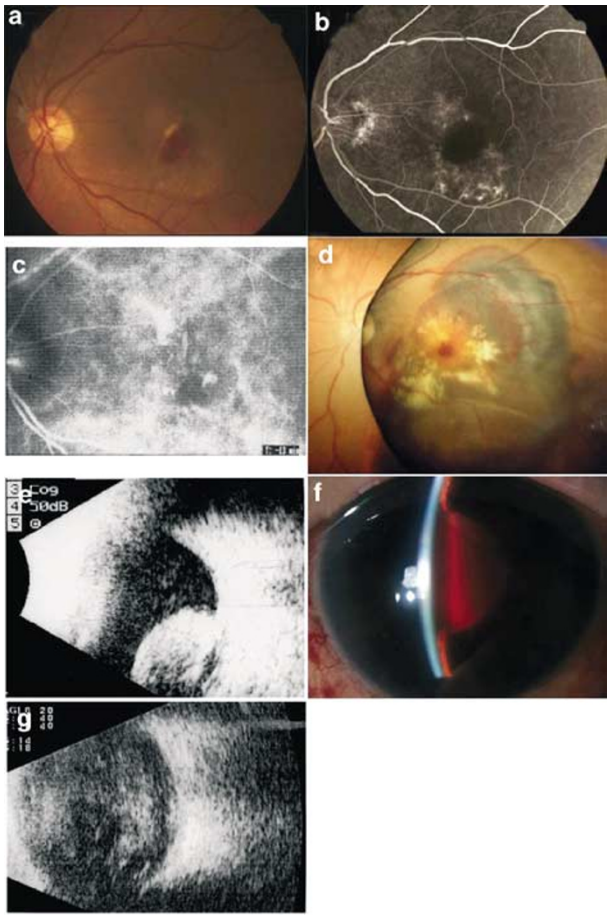

Figure 1 Dilated fundus examination (a) revealed subretinal haemorrhage in the macular area at our recent observation. Fluorescein angiography (b) and indocyanine green angiography (c) disclosed a persistent occult choroidal membrane not suitable for treatment. At initial presentation to our clinic, the dilated fundus examination disclosed a massive subretinal haemorrhage (d). After 1 month, massive subretinal haemorrhage was seen as high reflex on B-mode ultrasonography (e) and slit-lamp examination showed massive subretinal haemorrhage reaching the posterior capsule of the lens (f). At 1 week thereafter, the subretinal haemorrhage reached the posterior capsule of the lens as shown by B-mode ultrasonography (g).

Comment

Massive subretinal haemorrhage is a serious complication of AMD. Systemic hypertension[3] and the use of anticoagulants[4] are known risk factors of subretinal haemorrhage. We describe a rare association between subretinal haemorrhage and ITP. This case indicates that close ophthalmologic examination is necessary for us to treat thrombocytopenic diseases like ITP.

References

1 Walsh FB, Hoyt WF (ed). *In Clinical Neuro-ophthalmology*, Vol 2, pp 1921–1925. Williams and Wilkins: Baltimore, 1969.
2 Rubenstein R, Yanoff M, Albert D. Thrombocytopenia, anemia and retinal hemorrhage. *Am J Ophthalmol* 1968; **65**: 435–440.
3 Lewis H, Sloan SH, Foos RY. Massive intraocular hemorrhage associated with anticoagulation and age-related macular degeneration. *Graefes Arch Clin Exp Ophthalmol* 1988; **226**: 59–64.
4 Hyman L, Neborsky R. Risk factors for age-related macular degeneration: an update. *Curr Opin Ophthalmol* 2002; **13**: 171–175.

T Inoue, Y Yanagi, Y Tamaki, J Kami and Y Kato

Department of Ophthalmology
University of Tokyo School of Medicine
7-3-1 Hongo
Bunkyo-ku, Tokyo, Japan

Correspondence: Y Yanagi,
Tel: +81 3 5800 8660
Fax: +81 3 3817 0798
E-mail: yanagi-tky@umin.ac.jp

Eye (2004) **18,** 656–657. doi:10.1038/sj.eye.6700732
Published online 9 January 2004

Sir,

Corneal endothelial transplantation using femtosecond laser technology

Penetrating keratoplasty has been the treatment of choice for eyes with corneal endothelial dysfunction such as pseudophakic bullous keratopathy, Fuchs' corneal endothelial dystrophy, and congenital hereditary endothelial dystrophy. Since it is only the inner corneal layer which is defunct in these diseases, the idea has been to selectively transplant a deep corneal layer including Descemet's membrane and the corneal endothelium.[1,2] It would markedly decrease the amount of grafted allogenic tissue, and by leaving the surface of the cornea mostly untouched, it may decrease postoperative corneal astigmatism. Using new femtosecond laser technology,[3,4] the purpose of the present study was to describe the possibility to nonmechanically create a deep corneal lamella containing Descemet's membrane for transplantation of corneal endothelium.[5]

Case report

The study included five freshly enucleated porcine eyes. Using a corneal contact lens and a femtosecond laser (20/10 Perfect Vision, Am Taubenfeld 21/1, D-69123 Heidelberg, Germany) with a wavelength of 1060 nm, a spot size of about 10 μm, a pulse energy of less 10 μJ, and a laser pulse duration of several hundred femtoseconds, a deep corneal lamella was created. Thickness of the lamella was about 50–100 μm. Diameter of the lamella on its endothelial side was 6 mm. In the periphery of the lamella in its stromal part, an overhanging circular ledge of 1 mm was created leading to a diameter of 8 mm of the lamella in its stromal part. The ledge fitted into a corresponding circular groove in the surrounding deep stroma of the recipient cornea. The overhanging ledge of the lamellar graft with the corresponding groove in the recipient cornea were formed to enhance the stability of the graft. In a second step, on top of the deep corneal lamella, a thick corneal flap with three positional spikes and a hinge was created. The positional spikes in the thick autologous corneal flap were formed to increase postoperative rotational stability of the flap and to decrease corneal astigmatism.[5,6] The flap was opened, the deep corneal lamella with Descemet's membrane and corneal endothelium was removed and inserted into the bed of recipient eyes which had been prepared in the same way.

For all eyes included in the study, the deep thin corneal lamellae and the thick corneal flaps could be prepared without major difficulties. The deep corneal lamella containing corneal endothelium and Descemet's membrane with a thin adjacent layer of corneal stroma could easily be removed and repositioned into their original beds as well as into the recipient beds of other eyes in which the recipient beds were created in the same way. The time taken for the preparation of the corneal lamellae and the corneal flaps was less than 5 min in all cases.

Comment

In corneal surgery, femtosecond laser technology allows to create deep corneal lamellae containing Descemet's