

# Management of high-risk corneal grafts

DJ Coster and KA Williams

## Abstract

**Corneal transplantation is not invariably successful despite the anterior chamber of the eye being an immunologically privileged site. Inflammation erodes privilege. Other than by reducing inflammation through meticulous surgery, careful postoperative surveillance, and effective topical corticosteroids in the postoperative phase, there is little that a surgeon can do to improve the outlook for the majority of patients receiving corneal transplants. For patients at appreciable risk, HLA Class I matching may help where it is available. So too will systemic immunosuppression where it can be justified. Despite these measures, the results of corneal transplantation have not shown the improvement seen in solid organ transplantation over the last 30 years. New approaches applicable to corneal transplantation are required.**

*Eye* (2003) 17, 996–1002. doi:10.1038/sj.eye.6700634

**Keywords:** high-risk corneal transplantation; HLA matching; immunosuppression; antibody engineering; gene therapy

## Introduction

Corneal transplantation is often thought of as being highly successful because the cornea and anterior chamber of the eye are privileged sites. In some experimental situations, a normal cornea grafted into a normal cornea will survive indefinitely. Unfortunately, in clinical practice, normal corneas are not grafted into normal recipient beds. The closest a clinician comes to this is grafting someone for keratoconus or stromal dystrophy. In these cases, graft survival is almost invariably prolonged. However, many patients requiring a corneal graft have acquired corneal conditions and for this group of patients, prolonged graft survival occurs less frequently. In Australia, only 31% of corneal

grafts are performed for keratoconus and less than 1% are carried out for stromal dystrophies.<sup>1</sup> The majority of corneal transplants are carried out for acquired corneal conditions.

In patients with acquired corneal disease, immunological privilege is eroded. Erosion of corneal privilege leaves the graft prone to allograft rejection, the commonest reason for corneal graft failure. The degree of erosion of privilege is related to the nature of the underlying disease. In some conditions and circumstances, the erosion of graft privilege and the tendency to allograft rejection is such that graft failure is almost inevitable. In others, the erosion is much less and prolonged graft survival can occur but is not invariable. A comprehensive evaluation of the clinical factors associated with a higher risk of corneal graft failure is made in the regular reports of the Australian Corneal Graft Register and assessed by multivariate analysis.<sup>2</sup> The clinical factors shown to be related to the risk of corneal graft failure are presented in Table 1.

Those for whom the chance of prolonged survival is reduced are considered high-risk patients. Just how this high-risk group is defined depends on how high one wishes to put the bar. Any patient having a graft for an acquired condition is at a higher risk of failure compared to someone having a graft for keratoconus. This risk is much higher if the recipient cornea has recently been inflamed, is inflamed at the time of surgery, or subsequently becomes inflamed.

There is some debate as to what constitutes a high-risk corneal graft. This is evident from the criteria used to admit patients to treatment trials where there is considerable variation in the criteria used. For the purposes of this discussion, we have adopted an arbitrarily determined categorization that we use in our clinical practice. It is based on consideration of factors shown to be associated with graft survival in the Australian Corneal Graft Register and presented in Table 2.

Flinders Drive  
 Bedford Park  
 South Australia  
 Australia

Correspondence:  
 DJ Coster  
 Flinders Drive  
 Bedford Park 5042  
 South Australia  
 Australia  
 Tel: +61 8 8204 5511  
 Fax: +61 8 8204 5450  
 E-mail: doug.coster@flinders.edu.au

Received: 28 February 2003  
 Accepted in revised form:  
 28 February 2003

**Table 1** Variables best predicting corneal graft failure. Summary of the multivariate analysis reported in the 1999 report of the Australian Corneal Graft Register

Indication for graft
Number of previous ipsilateral grafts
Eye inflamed at the time of graft
Graft size
Lens status immediately after graft
Neovascularization of the graft
Occurrence of graft rejection episode
Microbial keratitis or stitch abscess in the graft
Early removal of graft sutures
Postoperative rise in intraocular pressure

**Table 2** Risk assignment for corneal grafts based on preoperative pathology

Low risk	Keratoconus, stromal dystrophies
Intermediate risk	Not keratoconus or stromal dystrophy and excluding patients with clinical features associated with high risk, for example, most cases of pseudophakic bullous keratopathy
High risk	Any one of <ul style="list-style-type: none"> <li>● previous graft failure</li> <li>● previous keratitis</li> <li>● current keratitis</li> <li>● vascularization into recipient bed</li> </ul>

A distinction must be made between a high-risk graft and a patient at high risk. A high-risk graft is one that is likely to fail. The risk faced by a patient is a more complicated consideration because for a patient the concept of risk entails not only the probability of a complication occurring but the consequence of its occurrence. For this reason, one-eyed patients are at a higher risk from eye surgery than binocular patients. One also has to take into account the consequences of any treatment other than the surgery. Some treatments that may be used for patients with high-risk corneal grafts, such as systemic immunosuppression, come with significant risks. The management of patients needing corneal transplantation is therefore determined by an assessment of the benefits of a successful outcome, of the risk of graft failure, and the potential consequences of any supporting therapies that might be considered.

### Immune privilege and the corneal allograft response

Inflammation in the recipient graft bed, or subsequently in the graft, erodes graft rejection and predisposes to allograft rejection and graft failure. An appreciation of how inflammation erodes corneal privilege and mechanisms of corneal allograft rejection is required as a basis for proposing strategies to decrease the impact of immunological rejection on graft survival.

A number of factors contribute to immunological privilege in the cornea and anterior segment of the eye.

1. *The blood-eye barrier.* The normal cornea is somewhat remote from the intravascular space. Only the most peripheral cornea is directly dependent on circulation for nutrition and respiration. The central cornea relies on the tear-film and the aqueous humour for its maintenance. The aqueous is supported by the vascular iris, but there is no free exchange between the intravascular space and the aqueous. The constituents of the aqueous get there by a process of active secretion. This separation of the ocular tissues and the intravascular space is referred to as the blood-eye barrier.<sup>3-5</sup>
2. *Absence of blood vessels and lymphatics.* The normal cornea is devoid of blood vessels and lymphatics. The absence of blood vessels and lymphatics interferes with both the afferent and efferent arm of the immune response.<sup>6,7,25</sup>
3. *Modest expression of HLA.* There is some Class I expression on epithelial cells, stromal keratocytes, and corneal endothelial cells. There is also modest Class II expression on Langerhans cells in the peripheral epithelium and interstitial dendritic cells in the peripheral stroma.<sup>8</sup> ABO antigens are present on epithelial cells.<sup>9,10</sup> Transplantation experiments in rats demonstrate that it is the minor antigens that are important in the corneal allograft response rather than Class I or II.
4. *Scarcity of antigen processing cells.* The normal cornea contains few mature cells capable of presenting antigens to the host immune system. There are Langerhans cells in the epithelium<sup>11,12</sup> and interstitial dendritic cells in the peripheral cornea,<sup>13,14</sup> but very few become involved in the operative field with conventional corneal grafting.
5. *Constitutive expression of Fas-ligand (CD95L).* Only privileged sites constitutively express Fas-Ligand. The presence of this entity promotes apoptosis in cells bearing Fas, such as immunocytes.<sup>15-17</sup>
6. *Immunosuppressive cytokines in aqueous humour,* for example, transforming growth factor TGF $\beta$ ,<sup>18,19</sup> alpha-melanocyte-stimulating hormone  $\alpha$ MSH,<sup>20</sup> and vasoactive intestinal peptide VIP<sup>21</sup> present in normal aqueous humor.
7. *Anterior chamber-associated immune deviation.* Antigens introduced into the anterior chamber of the eye produce antigen-specific suppression of delayed hypersensitivity.<sup>22</sup>

Some of these factors that contribute to the immune privilege in the anterior eye are altered by inflammation. Inflammation breaks down the blood-eye barrier. An increase of the leakiness of blood vessels is a

fundamental aspect of inflammation. Any inflammation in the anterior segment of the eye results in egress of cells and proteins into the extravascular space.<sup>23,24</sup>

Chronic inflammation can result in the development of new blood vessels and lymphatics.<sup>25</sup> The presence of new vessels in the cornea is easily seen clinically and is associated with an increased risk of corneal allograft rejection.<sup>26</sup>

There is also an increased expression of HLA antigens in the cornea under inflammatory conditions.<sup>27,28</sup> In addition, there is an accumulation of bone-marrow-derived cells in the cornea with inflammation.<sup>22,25</sup> These cells may persist for many years after an inflammatory event. Perhaps the cornea always has higher cell counts after inflammation and never returns to normal. The number of bone-marrow-derived cells in the recipient cornea is related to the probability of corneal graft failure from rejection.<sup>29</sup> When corneal graft privilege is sufficiently eroded, allograft rejection can occur.

There is little a clinician can do to maintain corneal privilege other than suppress inflammation. This is made possible by reducing corneal trauma to a minimum, by exemplary microsurgical technique, prompt attention to episodes of intercurrent inflammation such as blepharitis or loose sutures, and the use of anti-inflammatory medication, particularly topical corticosteroids.

### Mechanisms of corneal allograft rejection

An idealized model of allograft rejection can be constructed from clinical observations and experimental

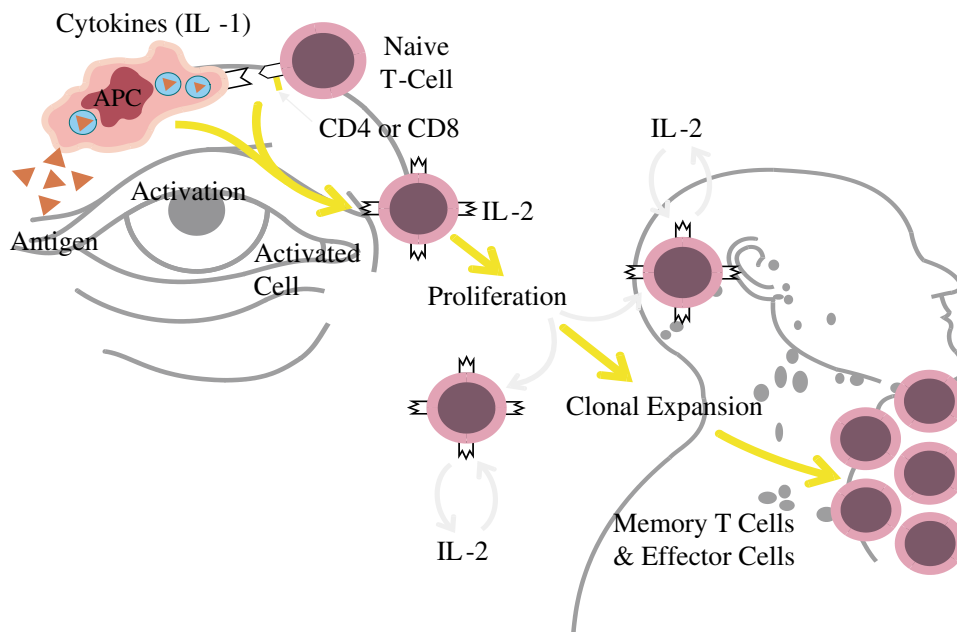
inferences. The process has some important differences from other organ systems.

Both major and minor transplantation antigens seem capable of providing the starting point for the corneal allograft response.<sup>30</sup> It is the bone-marrow-derived cells, the interstitial dendritic cells, that process alloantigens and present them to the host immunocyte. This occurs in the ocular environs and local lymph nodes.<sup>31,32</sup>

The second step in the afferent arm of the corneal allograft response is T-cell activation. This occurs when a foreign protein has been digested in fragments within a phagocytic cell and presented on the cell surface in conjunction with host HLA molecules to a host naive immunocyte. Once activated, an immunocyte can take on a number of activities related to immunity, such as regulation of immune responses, delayed-type hypersensitivity reactions, and specific lysis of cells. One of the activities of T lymphocytes is the promotion of clonal expansion. Clonal expansion occurs in draining lymph nodes, and for the cornea the relevant nodes are in the face and the neck.<sup>32</sup>

The efferent arm of the corneal allograft response is directed at all components of the cornea, but the endothelial cell monolayer is the most susceptible.<sup>33</sup> It has limited capacity for repair. Cell damage occurs as a result of mechanisms specifically aimed at cells bearing nonself antigens and through nonspecific mechanisms. A summary of the relevant aspects of the corneal allograft response is presented in Figure 1.

Since it is not possible to specifically enhance corneal privilege—only generic strategies to minimize



**Figure 1** Schematic representation of corneal allograft rejection in the eye and the draining lymph nodes.

inflammation are practical—surgeons are left with abrogating the corneal allograft response as the only feasible approach to improve the outlook for patients having high-risk corneal grafts. There are only limited options for achieving this: minimizing inflammation, reducing relevant immunogenetic differences between donor and host by antigenic matching, and by suppressing host immunoreactivity.

### Strategies for decreasing the effect of the corneal allograft response

#### *Effective anti-inflammatory measures*

Effective microsurgery can reduce postoperative inflammation and so too can the use of topical anti-inflammatory measures. The time-honoured way of achieving this is with topical corticosteroids. Anecdotal reports suggest that the outcome of corneal transplantation improved dramatically with the introduction of these agents in the 1960s. Unfortunately, the optimal dose of topical steroids for patients having corneal grafts has not been agreed upon and there is considerable variation in the way clinicians use these drugs. The unexpectedly good results reported in the Collaborative Corneal Transplantation Study (CCTS)<sup>34</sup> in both the antigen-matched and control group have been attributed to the high doses of topical corticosteroids used in the postoperative period.<sup>35</sup> This was considered to be higher than used by most surgeons in their routine practice. Even when topical corticosteroids are used at close to the maximal tolerated dose, they are only partially effective. The rejection rates for high-risk patients remain unacceptably high despite high doses of topical corticosteroids.

#### *HLA matching*

There is argument about the place of conventional HLA matching for corneal transplantation, particularly since the unexpected findings of the CCTS.<sup>34</sup> The results of this study have been controversial. They reported no advantage from Class I and II matching but a benefit from ABO matching. These findings for Class I and II matching contradict earlier studies. This has been attributed to a number of factors, including the high doses of topical corticosteroids used in the postoperative period and insufficiently accurate tissue typing. The benefit seen with ABO matching is real, surprising, and worthy of further investigation.

Despite the findings of the CCTS the weight of evidence from published studies suggests a modest effect for Class I.<sup>35–39</sup> The effect of Class II matching is more equivocal and there are reports to suggest an inverse response as well as a beneficial response.<sup>40–43</sup> (An inverse

response is not completely unexpected since indirect presentation of antigen, as occurs in the corneal allograft response, is Class II restricted.) There is also experimental evidence that minor antigens are relatively more important than in other forms of clinical transplantation. However, even if the modest benefits of matching are to be pursued, the logistics of achieving acceptable matches is complicated and time consuming. For many patients, the prolonged waiting time for a matched graft is unacceptable considering the limited benefits from the process.

#### *Systemic immunosuppression*

Although systemic immunosuppression is widely used in other forms of clinical transplantation, there are only limited reports of the effectiveness of this approach for corneal transplantation. The most convincing study demonstrated enhanced graft survival in patients who received systemic cyclosporin for a year compared to groups that received it for only 4 months and a third group that did not receive cyclosporin at all.<sup>44–45</sup> Although no major side effects were reported in this study, our experience is that virtually all patients who receive systemic immunosuppressive doses of the drug develop some drug-related complication. There is the risk of developing potentially overwhelming infection, even with short-term use, and there is the issue of neoplasia, particularly with long-term administration. Skin and hair changes are common, so too is hypertension. With long-term therapy, nephrotoxicity is troublesome.

There are no large studies to support the use of antiproliferative agents along with systemic cyclosporin, an approach used widely in solid organ transplantation. Despite the lack of hard evidence, we prefer this approach. The combination of a calcineurin blocker (cyclosporin or FK506) and an antiproliferative agent (azathioprine or mycophenolate) is widely used in transplantation and has been shown to be more effective than cyclosporin alone. There is no particular regimen that has been shown to be preferable for patients with high-risk corneal grafts. Nor has the period of time required for immunosuppression to maximize graft survival been determined. Our policy has been to use the same regimen that is used for essential organ transplantation in our institution. This facilitates prescribing as well as efficacy and toxicity surveillance. We use cyclosporin and azathioprine or mycophenolate for 1 year unless the drugs are poorly tolerated.

It must be emphasized that the documented risks associated with this approach are not acceptable for many patients having corneal transplants. Since the

**Table 3** Management of high-risk corneal grafts

<i>Intervention</i>	<i>Level of evidence</i>	<i>Recommendation</i>
Topical corticosteroids	Established treatment Indirect evidence from RCT that high dose is better than low dose	Mainstay of treatment Use highest tolerable dose, for example, prednisolone acetate eye drops 1% four times per day
Antigen matching	RCT show limited beneficial effect for Class I  Conflicting evidence for Class II matching—some evidence of inverted result for Class II ABO evidence of beneficial effect in CCTs. Needs to be confirmed by other studies	Class I—use for high-risk cases if practical in very high risk cases Class II—not advocated  ABO—not advocated
Topical cyclosporine	No evidence of effect in several RCT trials	Not advocated
Systemic steroids	Controlled studies show prolonged graft survival	Short-term administration (up to 4 months) in high-risk cases
Systemic immunosuppression with cyclosporine and antiproliferative agent	Controlled studies confirm prolonged graft survival	Intermediate-term therapy (1 year if tolerated) in high-risk cases

consequences of complications of immunosuppression may be life threatening, this approach is only acceptable for patients who are blind for the want of a functioning graft and are prepared to risk a potentially fatal outcome to achieve an improvement in vision.<sup>46</sup>

A summary of the options available to surgeons managing patients with high-risk corneal transplants is presented in Table 3.

#### ***Treatment of corneal allograft rejection—graft retrieval***

Many grafts that are subjected to an allograft response are lost. For those who recover, the prospects for long-term survival are reduced.<sup>1,2</sup> Rejection episodes are significant events in the life of a graft, and demand prompt attention and effective treatment. It has been shown that corticosteroids, delivered as an intravenous pulse, retrieve more rejection episodes than oral steroids. Whether this form of treatment reduces the tendency for subsequent rejection is unknown.<sup>47</sup>

#### ***Novel approaches to immunomodulation***

Antibody-based therapies have an established place in most branches of clinical transplantation, but have not found a place in corneal transplantation to date. Heterologous antilymphocyte serum or globulin has been used for essential solid organ grafts for many years. More recently, monoclonal antibodies have been used. OKT3 is used for the treatment of allograft rejection in solid organ transplantation. This approach has not found a place in the treatment of corneal allograft rejection although one group has reported the use of monoclonal antibodies administered by injection into the anterior chamber of the eye.<sup>48,49</sup> More recently, there have been

anecdotal reports of monoclonal antibodies, CAMPATH-1H (anti-CD52)<sup>50,51</sup> and anti-CD25,<sup>52</sup> given systemically to successfully suppress clinical corneal allograft rejection. As promising as these developments are, they bring with them the limitations of systemic administration and systemic side effects.

Desirable attributes of any novel therapies for corneal transplantation include increased specificity of immune suppression and local administration. To achieve this, any proposed interference with the allograft response should be proximal in the afferent limb—at the point of antigen processing and generation—with the hope of achieving suppression of the response to only the relevant alloantigens. Local administration of therapeutic agents as eye drops would also convey advantage. Local administration limits toxicity to the point of application, and there are the additional advantages of ease of administration and low cost. Two developments that show promise of satisfying these requirements are the development of monoclonal antibody fragments directed at targets in the immune system<sup>53</sup> and the use of gene therapy to modify the allograft response by influencing cytokine production.<sup>54</sup>

#### **Conclusion**

There is room for improvement in the outcome of corneal transplants, particularly for patients receiving grafts for conditions other than keratoconus and stromal dystrophies. Corneal transplantation has not shown the steady improvements that have been seen in other branches of clinical transplantation because the developments in clinical therapies that have brought about these improvements are not directly applicable to corneal transplantation. To achieve optimal results for

corneal transplantation, it is necessary to select cases carefully to ensure that patients have the greatest chance of improving their functional (binocular) vision at the least personal risk. For the most part, this means avoiding corneal transplantation in patients who have normal vision in the contralateral eye. More heroic measures can be considered for patients who are blind but for the need of a clear corneal graft. In all patients receiving a corneal graft, effective anti-inflammatory measures, and in particular the use of topical corticosteroids in the maximal tolerated dose in the postoperative period, are mandatory. Matching for Class I antigens is also justified where the service is available and it is reasonable for the patient to wait the time predicted to achieve a helpful match. In some patients, systemic immunosuppression is desirable. This is a small group of patients with clinical features indicating allograft rejection is likely, who are in need of a clear graft to achieve functional vision, and who are fit and understand the implications of systemic immunosuppression. Even when all these measures are possible, graft failure because of allograft rejection, and other nonimmunological processes, still occurs. More research and development is needed. Improvements in antigen matching, anti-inflammatory measures, and immunomodulation that are applicable to clinical corneal allograft rejection are required.

## References

- Williams KA, Muehlberg SM, Lewis RF, Giles LC, Coster DJ. *Report from the Australian Corneal Graft Registry* 1996. Mercury Press: Adelaide, 1997, pp 1–131.
- Williams KA, Muehlberg SM, Bartlett CM, Esterman A, Coster DJ. *Report from the Australian Corneal Graft Registry* 1999. Snap Printing: Adelaide, 2000, pp 1–137.
- Dernouchamps JP, Heremans JF. Molecular sieve effect of the blood–aqueous barrier. *Exp Eye Res* 1975; **21**: 289–297.
- Maurice D, Mishima S. Ocular pharmacokinetics. In: Sears M (ed). *Pharmacology of the Eye*. Springer-Verlag: Berlin, 1984, pp 19–116.
- Kuchle M, Nguyen NX, Naumann GO. Aqueous flare following penetrating keratoplasty and in corneal graft rejection. *Arch Ophthalmol* 1994; **112**: 354–358.
- Barker CF, Billingham RE. Immunologically privileged sites and tissues. In: Porter R, Knight J (eds). *Corneal Graft Failure Ciba. Foundation Symposium 15 (new series)*. Elsevier: Amsterdam; Excerpta Medica: North-Holland, 1973, pp 79–104.
- Medawar P. Immunity of homologous grafted skin III. The fate of skin homografts transplanted to the brain, to subcutaneous tissue, and to the anterior chamber of the eye. *Br J Exp Pathol* 1948; **29**: 58–69.
- Whitsett CF, Stulting RD. The distribution of HLA antigens on human corneal tissue. *Invest Ophthalmol Vis Sci* 1984; **25**: 519–524.
- Nelken E, Michaelson IC, Nelken D, Gurebitch J. ABO antigens in the human cornea. *Nature* 1956; **177**: 840.
- Salisbury JD, Gebhardt BM. Blood group antigens on human corneal cells demonstrated by immunoperoxidase staining. *Am J Ophthalmol* 1981; **91**: 46–50.
- Jager MJ. Corneal Langerhans cells and ocular immunology. *Reg Immunol* 1992; **4**: 186–195.
- Baudouin C, Brignole F, Pisella PJ, Becquet F, Philip PJ. Immunophenotyping of human dendriform cells from the conjunctival epithelium. *Curr Eye Res* 1997; **16**: 475–481.
- Williams KA, Ash JK, Coster DJ. Histocompatibility antigen and passenger cell content of normal and diseased human cornea. *Transplantation* 1985; **39**: 265–269.
- Catry L, Van den Oord J, Foets B, Missotten L. Morphologic and immunophenotypic heterogeneity of corneal dendritic cells. *Graefes Arch Clin Ex Ophthalmol* 1991; **229**: 182–185.
- Wilson SE, Li Q, Weng J, Barry-Lane PA, Jester JV, Liang Q *et al*. The Fas-Fas ligand system and other modulators of apoptosis in the cornea. *Invest Ophthalmol Vis Sci* 1996; **37**: 1582–1592.
- Griffith TS, Yu X, Herndon JM, Green DR, Ferguson TA. CD95-induced apoptosis of lymphocytes in an immune privileged site induces immunological tolerance. *Immunity* 1996; **5**: 7–16.
- Stuart PM, Griffith TS, Usui N, Pepose J, Yu X, Ferguson TA. CD95 ligand (FasL)-induced apoptosis is necessary for corneal allograft survival. *J Clin Invest* 1997; **99**: 396–402.
- Wilbanks GA, Mammolenti M, Streilein JW. Studies on the induction of anterior chamber-associated immune deviation (ACAID). III. Induction of ACAID depends upon intraocular transforming growth factor-beta. *Eur J Immunol* 1992; **22**: 165–173.
- D'Orazio T, Niederkorn JY. A novel role for TGF-beta and IL-10 in the induction of immune privilege. *J Immunol* 1998; **160**: 2089–2098.
- Taylor AW, Streilein JW, Cousins SW. Alpha-melanocyte-stimulating hormone suppresses antigen-stimulated T cell production of gamma-interferon. *Neuroimmunomodulation* 1994; **1**: 188–194.
- Taylor AW, Streilein JW, Cousins SW. Immunoreactive vasoactive intestinal peptide contributes to the immunosuppressive activity of normal aqueous humor. *J Immunol* 1994; **153**: 1080–1086.
- Streilein JW. Peripheral tolerance induction: lessons from immune privileged sites and tissues. *Transplant Proc* 1996; **28**: 2066–2070.
- Williams KA, Coster DJ. Rethinking immunological privilege: implications for corneal and limbal stem cell transplantation. *Mol Med Today* 1997; **3**: 495–515.
- Kuchle M, Nguyen NX, Naumann GO. Aqueous flare following penetrating keratoplasty and in corneal graft rejection. *Arch Ophthalmol* 1994; **112**: 354–358.
- Collin HB. Endothelial cell lined lymphatics in the vascularized rabbit cornea. *Invest Ophthalmol* 1996; **5**: 337–354.
- Coster DJ. Factors affecting the outcome of corneal transplantation. *Ann R Coll Surg Engl* 1981; **63**: 91–97.
- Treselet PA, Foulks GN, Sanfilippo F. The expression of HLA antigens by cells in the human cornea. *Am J Ophthalmol* 1984; **98**: 763–772.
- Pepose JS, Gardner KM, Nestor MS, Foos RY, Pettit Th. Detection of HLA class I and II antigens in rejected human corneal allografts. *Ophthalmology* 1985; **92**: 1480–1484.
- Williams KA, White MA, Ash JK, Coster DJ. Leukocytes in the graft bed associated with corneal graft failure. Analysis

- by immunohistology and actuarial graft survival. *Ophthalmology* 1989; **96**: 38–44.
- 30 Katami M, Madden PW, White DJ, Watson PG, Kamada N. The extent of immunological privilege of orthotopic corneal grafts in the inbred rat. *Transplantation* 1989; **41**: 371–376.
- 31 Egan RM, Yorkey C, Black R, Loh WK, Stevens JL, Woodward JG. Peptide-specific T cell clonal expansion *in vivo* following immunization in the eye, an immune-privileged site. *J Immunol* 1996; **157**: 2262–2271.
- 32 Yamagami S, Dana MR. The critical role of lymph nodes in corneal alloimmunization and graft rejection. *Invest Ophthalmol Vis Sci* 2001; **42**: 1293–1298.
- 33 Tuft SJ, Coster DJ. The corneal endothelium. *Eye* 1990; **4**: 389–424.
- 34 The Collaborative Corneal Transplantation Studies Research Group. The collaborative corneal transplantation studies (CCTS). Effectiveness of histocompatibility matchin in high-risk corneal transplantation. *Arch Ophthalmol* 1992; **110**: 1392–1403.
- 35 Gore SM, Vail A, Bradley VA, Rogers CA, Easty DL, Armitage WJ. HLA-DR matching in corneal transplantation. Systemic review of published evidence Corneal. Transplant Follow-up Study Collaborators. *Transplantation* 1995; **60**: 1033–1039.
- 36 Batchelor JR, Casey TA, Werb A, Gibbs DC, Prasad SS, Lloyd DF *et al*. HLA matching and corneal grafting. *Lancet* 1976; **1**: 551–554.
- 37 Volker-Dieben HJ, Kok-van Alphen CC, Lansbergen Q, Persijn GG. The effect of prospective HLA-A and -B matching and corneal graft survival. *Acta Ophthalmol (Copenhagen)* 1982; **60**: 203–212.
- 38 Foulks GN, Sanfilippo FP, Locascio III JA, MacQueen JM, Dawson DV. Histocompatibility testing for keratoplasty in high-risk patients. *Ophthalmology* 1983; **90**: 230–244.
- 39 Sanfilippo F, MacQueen JM, Vaughn WK, Foulks GN. Reduced graft rejection with good HLA-A and B matching in high-risk corneal transplantation. *N Engl J Med* 1986; **315**: 29–35.
- 40 Hoffman F, von Keyserlingk HJ, Wiederholt M. Importance of HLA DR matching for corneal transplantation in high-risk cases. *Cornea* 1986; **5**: 139–143.
- 41 Baggesen K, Lamm LU, Ehlers N. Significant effect of high-resolution HLA-DRB1 matching in high-risk corneal transplantation. *Transplantation* 1996; **62**: 1273–1277.
- 42 Munkhbat B, Hagihara M, Sato T, Tsuchida F, Sato K, Shimazaki J *et al*. Association between HLA-DPB1 matching and 1-year rejection-free graft survival in high-risk corneal transplantation. *Transplantation* 1997; **63**: 1011–1016.
- 43 Vail A, Gore SM, Bradley BA, Easty DL, Rogers CA, Armitage WJ. Influence of donor and histocompatibility factors on corneal graft outcome. *Transplantation* 1994; **58**: 1210–1216.
- 44 Hill JC. Systemic cyclosporin in high-risk keratoplasty: short *versus* long term therapy. *Ophthalmology* 1994; **101**: 128–133.
- 45 Hill JC. Systemic cyclosporin in high-risk keratoplasty: long term results. *Eye* 1995; **9**: 422–428.
- 46 Denton MD, Magee CC, Sayegh MH. Immunosuppressive strategies in transplantation. *Lancet* 1999; **353**: 1083–1091.
- 47 Hill JC, Maske R, Watson P. Corticosteroids in corneal graft rejection: oral *versus* single pulse therapy. *Ophthalmology* 1991; **98**: 329–333.
- 48 Ippoliti G, Fronterre A. Use of locally injected anti-T monoclonal antibodies in the treatment of acute corneal graft rejection. *Transplant Proc* 1987; **19**: 2579–2580.
- 49 Ippoliti G, Fronterre A. Usefulness of CD3 or CD6 anti-T monoclonal antibodies in the treatment of acute corneal graft rejection. *Transplant Proc* 1989; **21**: 3133–3134.
- 50 Newman DK, Isaacs JD, Watson PG, Meyer PA, Hale G, Waldmann H. Prevention of immune-mediated corneal graft destruction with the anti-lymphocyte monoclonal antibody, CAMPATH-1H. *Eye* 1995; **9**: 564–569.
- 51 Dick AD, Meyer P, James T, Forrester JV, Hale G, Waldmann H *et al*. Campath-1H therapy in refractory ocular inflammatory disease. *Br J Ophthalmol* 2000; **84**: 107–109.
- 52 Schmitz K, Hitzler S, Behrens-Baumann W. Immune suppression by combination therapy with basiliximab and cyclosporin in high risk keratoplasty. A pilot study. *Ophthalmologie* 2002; **99**: 38–45.
- 53 Thiel MA, Coster DJ, Standfield SD *et al*. Penetration of engineered antibody fragments into the eye. *Clin Exp Immunol* 2002; **128**: 67–74.
- 54 Klebe S, Sykes P, Coster D, Krishnan R, Williams K. Prolongation of sheep corneal allograft survival by transfer of the gene encoding ovine interleukin 10 to donor corneal endothelium. *Transplantation* 2001; **15**: 1214–1220.