Group 1 arteriovenous malformations are usually isolated findings detected on routine examination, non progressive, and associated with good visual acuity.[1] Photocoagulation treatment may be indicated if exudative maculopathy develops.[3] The differential diagnosis of congenital arteriovenous malformations includes peripapillary telangiectasia, capillary and cavernous haemangiomas, and retinovascular disease.[1]

Peripapillary telangiectatic microangiopathy is well described in LHON.[4] The microangiopathy precedes the optic neuropathy, and the telangiectatic vessels do not demonstrate leakage on angiography.[5] In nearly all families, LHON is associated with one of three mitochondrial DNA (mtDNA) mutations, at base pairs 11 778, 3460, or 14 484.[6] Mitochondrial DNA analysis in this patient was negative.

Retinal capillary haemangiomas may be sporadic or occur as a part of Von Hippel–Lindau's disease.[7] Clinically, these often present with exudative features and show arteriovenous shunting.[8] These features were absent in this patient and genetic testing was negative.

Cavernous haemangioma is a rare unilateral congenital anomaly located between two retinal veins and presenting with the typical appearance of a cluster of grapes.[9] Arteriovenous malformations should also be distinguished from acquired optic disc venous collaterals secondary to retinal venous occlusion or optic disc meningioma.[3]

The clinical and fluorescein angiogram findings, normal CT scan of the brain and orbits, and negative genetic screening all point in favour of a congenital arteriovenous malformation. The atypical features in this case are the location of the arteriovenous malformation, which was nasal to the disc, and the leakage of dye on angiography.

Acknowledgements

We acknowledge Dr PJS Dunn of the Department of Histopathology, Worcester Royal Infirmary; Dr John Harry of the Birmingham and Midland Eye Centre and the Medical Illustration Department of City Hospital; and Birmingham Midland Eye Centre, City Hospital for medical illustration.

References

1 Mansour AM, Walsh JB, Henkind P. Arteriovenous anastamoses of the retina. *Ophthalmology* 1987; **94**: 35–40.
2 Archer DB, Deutman A, Ernest JT, Krill AE. Arteriovenous communications of the retina. *Am J Ophthalmol* 1973; **75**: 224–241.
3 Gass JDM. *Stereoscopic Atlas of Macular Disease Diagnosis and Treatment*, Vol. 1. Mosby: St Louis, 1997; pp 440–442.
4 Nikoskelainen E, Hoyt WF, Nummelin K, Schatz H. Fundus findings in Leber's hereditary optic neuroretinopathy III. Fluorescein angiographic studies. *Arch Ophthalmol* 1984; **102**(7): 981–989.
5 Nikoskelainen E, Hoyt WF, Nummelin K. Ophthalmoscopic findings in Leber's hereditary optic neuropathy. II. The fundus findings in the affected family members. *Arch Ophthalmol* 1983; **101**(7): 1059–1068.
6 Chalmers RM, Schapira AH. Clinical, biochemical and molecular genetic features of Leber's hereditary optic neuropathy. *Biochem Biophys Acta* 1999; **1410**(2): 147–158.
7 Webster AR, Maher ER, Bird AC, Gregor ZJ, Moore AT. A clinical and molecular genetic analysis of solitary ocular angioma. *Ophthalmology* 1999; **106**(3): 623–629.
8 Gass JDM. *Stereoscopic Atlas of Macular Disease Diagnosis and Treatment*, Vol. 2. Mosby: St Louis, 1997, pp 850–857.
9 Kushner MS, Jampol LM, Haller JA. Cavernous hemangioma of the optic nerve. *Retina* 1994; **14**: 359–361.

S Chatterjee[1], M Hope-Ross[1], IH Clark[1] and PB Chell[2]

[1]Birmingham Midland Eye Centre
City Hospital, Dudley Rd
Birmingham, B18 7QH, UK

[2]Worcestershire Royal Hospital
Charles Hastings Way
Worcester WR1 3AS, UK

Correspondence: M Hope-Ross
Tel: 0212 5076796
Fax: 01926 843833
E-mail: monique.hope-ross@virgin.net

Sir,

A new cause for retinal haemorrhage and disc oedema in child abuse

Eye (2004) **18,** 75–77. doi:10.1038/sj.eye.6700480

Systemic hypertension in very young children is uncommon. The conditions associated with acute or intermittent hypertension include renal vascular or parenchymal disease, drugs or poisons, central or autonomic nervous syndromes, thrombosis of the aorta, and chronic lung disease.[1] Acute ocular injuries from child abuse include retinal haemorrhages, periorbital haematoma, retinal detachment, lens subluxation, subconjunctival haemorrhage, and trauma to eyelids.[2] We report the case of a child with retinal haemorrhages and show how serial fundus photography helped us to look into causes of retinal haemorrhages in child abuse other than shaking injury.

Case report

A $3^{1/2}$ year-old boy was transferred to our paediatric unit from a district general hospital (DGH) following an

episode of collapse. He was described as lying on his back with his eyes staring without any obvious limb jerking. This lasted approximately 5 min. As far as we know, he was born full term weighing 1.7 kg. He had been reported as being fit and well, but was investigated in the past for failure to thrive. This, however, was attributed to being born with significant intrauterine growth retardation. He was fully immunized and on admission he was on no medication.

At the time of admission, he was very thin and small for his age, weight 11.2 kg (below 5th percentile)[1] and height 98.5 cm (90th percentile).[1] He was conscious but mute with a withdrawn and frightened appearance. There was extensive bruising all over the body, head, and limbs, scratches and scabs around nose and mouth, and petechiae on the tongue and cheeks. Cardiovascular system examination was unremarkable but for his blood pressure (BP) of 146/80 mmHg. This was high for his age (normal range for the age group at 90th percentile is 105/69–109/69 mmHg).[1] Neurological examination appeared to be normal, but retinal haemorrhages were suspected in the right fundus. A review of the radiographs from the DGH showed healing fractures of several bones including metatarsals and phalanges of the right foot and compression fractures of T8/9 vertebrae. CT of the brain showed a thin subdural collection of fluid with mild hydrocephalus. In view of the extensive bruising, full blood count, electrolytes, and coagulation studies were performed. These were within the normal range.

On referral to the ophthalmic unit, bilateral retinal haemorrhages were confirmed (Figure 1a and b). These were multiple, small superficial flame-shaped haemorrhages covering and surrounding the right eye optic disc that was mildly swollen. In the left eye, there were smaller scattered superficial nerve fibre layer haemorrhages. There were a few small dot and blot haemorrhages temporal to the right fovea. In the context of this hospital admission, it was felt that these retinal haemorrhages were possibly caused by shaking injury. However, they were not of the preretinal type (boat or globular shape) seen following severe shaking in infants.

Serial photographs of the fundi of the eyes were taken every week to assess the progress of the condition. Those taken 2 weeks after the admission showed worsening of the bilateral optic disc swelling (right more marked than the left) with fresh haemorrhages at the optic disc margins (Figure 1c and d). Under controlled conditions in the ward, there was no reason to suspect a shaking injury. Hence, the new finding called us to question the validity of the original diagnosis.

While in the hospital it was observed that his BP continued to be high to a maximum level of 150/110 mmHg. He was constipated, failed to pass urine, and

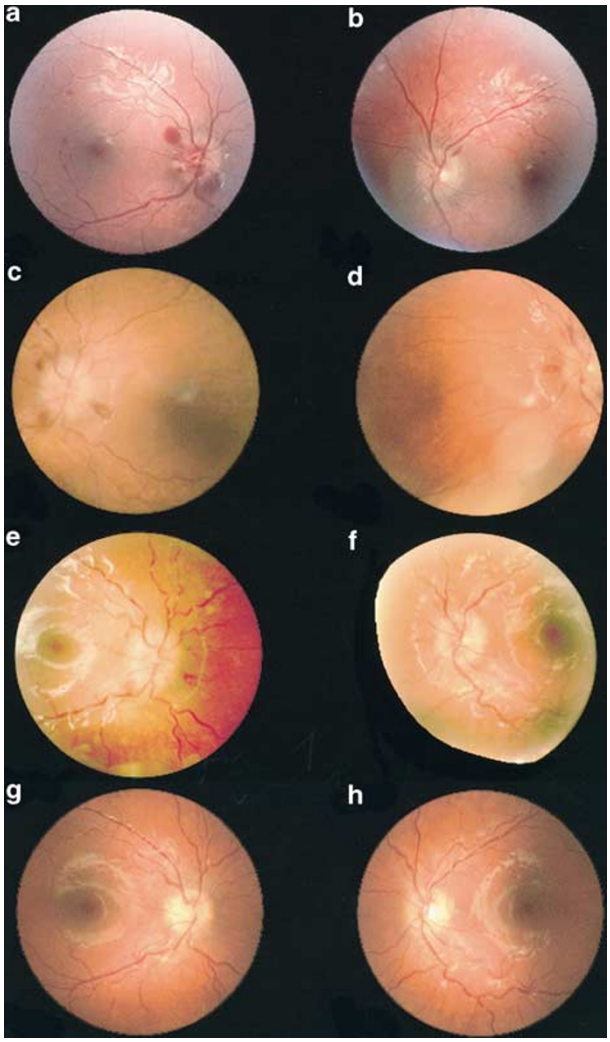

Figure 1 Funds photographs of the right and left eyes. (a,b) Week-1: There are multiple superficial flame-shaped haemorrhages covering and surrounding the optic discs. (c,d) Week-3: There are fresh haemorrhages at the optic disc margins with worsening of the optic disc swelling. (e,f) Week-4: Photographs taken 3 days after controlling the hypertension show that there is gradual resolution of the optic disc swelling and complete resolution of retinal haemorrhages. (g,h) At 3 months after discharge, the pictures showed asymmetrical optic atrophy.

was found to be in acute urinary retention. Ultrasound scans of the abdomen showed a distended bladder, but did not show any abnormality within the kidneys or the renal arteries. He was catheterized four times while in the hospital until he was able to pass urine by himself, but not in full control requiring a nappy all the time. He received treatment for constipation with laxatives.

With the new ocular findings, further CT of the brain was performed. This did not show any signs of raised intracranial pressure or fresh intracranial bleeding, although there was evidence of previous haemorrhage

as suggested by thin collection of parafalcine subdural fluid. A thorough and detailed investigation to find out the causes of systemic hypertension revealed no specific disease. Thus, it was felt that the systemic hypertension itself most likely resulted from extreme anxiety state, constipation, and urinary retention. The hypertension was treated successfully with atenolol 10 mg daily orally, which controlled the BP to an average level of 100/60 mmHg. He was discharged to the DGH 8 weeks after the admission, with significant improvement in his general health, blood pressure, and ophthalmic findings. He had gained weight by 1.5 kg to 12.7 kg (still below 5th percentile), and his behaviour had become more outgoing and normal. We concluded that the most likely cause for the retinal and optic disc haemorrhage and persistent disc oedema was systemic hypertension.

His visual acuity responses were unreliable at first, but by using Cardiff Cards (vanishing optotypes), a binocular visual acuity of 0.8 was obtained on the eighth day after admission. Subsequent monocular acuity tests suggested better vision in the left eye, and by 3 months the visual acuity improved to 6/6 in each eye with Kay single picture card.

Photographs were taken 3 days after controlling the systemic hypertension with treatment. They showed gradual resolution of the optic disc oedema and complete resolution of retinal haemorrhages (Figure 1e and f). There was, however, asymmetrical optic disc atrophy when reviewed 3 months after discharge (Figure 1g and h).

Comment

Child abuse is a general term that is used to cover various forms of damage inflicted on children, including emotional abuse, neglect, induced illness, sexual abuse, and physical injury.[3] An estimated 1.5–2% of children are reported to be abused or neglected per year. About half of these are aged 0–4 years of age. Nonaccidental injury (NAI) has become a significant problem with important medical, social, and legal implications. Approximately 30% of NAI cases are found to have ocular signs, which form the presenting features in 4–6% of cases. Retinal haemorrhages are the most common findings.[2,4]

Adelman *et al*[5] reported a case of child abuse presenting as unexplained severe systemic hypertension with no ocular findings, associated with femoral fracture. The high BP was observed with adequate pain control using morphine and during sleep. Ekeberg *et al*[6] studied a group of 50-year-old men with systemic hypertension. This study revealed an association of childhood traumas and other psychological problems with the development of hypertension later in adult life.

In this child, we believe that it was the emotional aspect of the child abuse that caused fear and anxiety associated with constipation and urinary retention, and the development of hypertension with retinopathy. We consider this as the first case report of another cause for retinal haemorrhages in child abuse than shaking injury. This case also illustrates how serial fundus photography is extremely useful in the documentation, detection, and diagnosis in suspected NAI in detailing the features of a condition that may otherwise be missed on clinical examination.

References

1 Behrman RE, Kleigman RM, Jenson HB. *Nelson Text book of Paediatrics*, 16th Ed. WB Saunders: London, 2000, pp 1348, 1450–1452.
2 May K, Doran RML. Non-accidental injury and the eye. *Oxford Text Book of Ophthalmology*, 1st Ed., Vol 2. Oxford Medical Publications, Oxford University Press: Oxford, 1999, pp 1091–1094.
3 Taylor D, Bonshek R, Brosnahan D, Carter N, Doran RML, Dutton G. Child abuse and the eye. *Eye* 1999; **13**: 3–10.
4 Carty H, Ratcliffe J. The Shaken baby syndrome. *BMJ* 1995; **310**: 344–345.
5 Adelman RD, Fink RA, Restaino IG. Child abuse in an infant presenting as unexplained acute systemic hypertension. *Paediatr Nephrol* 2000; **14**(8–9): 811–812.
6 Ekeberg O, Kjeldsen SE, Eide I, Leren P. Childhood traumas and psychosocial characteristics of 50-year-old men with essential hypertension. *J Psychosom Res* 1990; **34**: 643–649.

S Raman and RML Doran

Department of Ophthalmology
Clarendon Wing, Leeds General Infirmary
Leeds LS2 9NS, UK

Correspondence: S Raman
69, The Cornfields, Hebburn NE31 1YJ, UK
Tel: +44 113 392 2531
Fax: +44 113 292 6239
E-mail: somanraman310@msn.com

Sir,

Pleomorphic adenoma of the lacrimal gland in a teenager, a case report

Eye (2004) **18,** 77–79. doi:10.1038/sj.eye.6700484

Pleomorphic adenoma is the most common epithelial tumour of the lacrimal gland, accounting for half of all epithelial lesions in the lacrimal fossa.[1] It is extremely rare in childhood. Only eight cases are previously reported in the literature.[2–7] We report a further case in a young teenager whose presentation mimicked that of an inflammatory or infectious dacryoadenitis rather than a neoplastic process.