Eye (2002) 16, 440–446

www.nature.com/eye

CAMBRIDGE OPHTHALMOLOGICAL SYMPOSIUM

Visual recovery after macula-off retinal detachment

WH Ross

Abstract

With modern surgical techniques to repair retinal detachments, a greater than 90% primary anatomic success rate can be expected.[1–9] Despite this high level of anatomic success, visual results remain compromised mainly because of permanent functional damage once the macula becomes detached.[10] The most important predictor of visual recovery after retinal detachment surgery is preoperative visual acuity.[8,9,11,12] Preoperative acuity appears to be directly related to the height of macular detachment.[13] Shorter duration of detachment and younger age are also important in visual recovery. This paper will review the current literature that helps to improve our understanding of visual recovery after macula-off retinal detachments.
Eye (2002) **16,** 440–446. doi:10.1038/sj.eye.6700192

Keywords: visual recovery; macula off detachment < 7 days

Department of Ophthalmology
University of British Columbia
British Columbia
Canada

Correspondence:
WH Ross, MD, FRCSC
400–805 West Broadway
Vancouver, British Columbia
Canada, V5Z 1K1
Tel: 001 604 874 0404
Fax: 001 604 874 0099
E-mail: kbeckner@providencehealth.bc.ca

In 1982, Burton[10] published an important article on visual recovery of macula-off retinal detachments. He reported that 53% (46/87) of patients who underwent surgery by 9 days achieved 20/20 to 20/50 acuity. The proportion attaining 20/20 to 20/50 acuity diminished to 34% (27/70) in those patients operated on from 10–19 days and to 29% (14/48) in those patients operated on after 19 days. He concluded that patients with macular detachment of 9 days or less had a statistically significant better chance of obtaining a final vision of 20/50 or better than those with macular detachment of 10–19 days and longer than 20 days duration ($P < 0.05$).

Burton showed a progressive decline in visual acuity recovery over a 1–79 day period. The first break in his data occurred at day 5, at which the average level of visual recovery was 20/50. After day 5, the vision declined at a rate of one Snellen line per week up to 1 month. After 4 weeks of macular detachment, approximately one line of vision was lost for each additional 10–11 days until 7 days. This study demonstrated that visual recovery in relation to increasing duration of detachment declines in an exponential fashion (Figure 1). Despite Burton's results, it remained unknown whether surgical delay within the first week of macula-off retinal detachment altered final postoperative visual acuity.

In 1998, Ross and Kozy[14] published an article to help clarify this question. The purpose was to determine the visual results of macula-off retinal detachments operated on within 7 days of macular involvement. In this prospective study, 303 consecutive patients with rhegmatogenous retinal detachments seen during a 30-month period (August 1, 1994 through January 31, 1997) were interviewed and examined to determine the status of macular detachment. Eighty-five patients had macula-on detachments and were excluded from the study. The remaining 218 patients were carefully interviewed to pinpoint the onset of macular detachment to a specific 24-hour period within the first week. Ninety-one patients had macula-off detachments of longer than 7 days' duration and were excluded. An additional 23 patients with macula-off detachments of less than 1 week's duration were excluded because of previous retinal surgery (9 patients), proliferative vitreo-retinopathy more advanced than grade C3 in patients who had undergone initial combined vitrectomy and buckling surgery (4 patients), or ocular disease that precluded a good return of central vision (10 patients: macular degeneration in two, macular hole in two, degenerative myopia in two, optic atrophy in one, end-stage glaucoma in one, and amblyopia in two).

One hundred and four patients remained, and all underwent surgical repair of detachments within 24 hours of initial

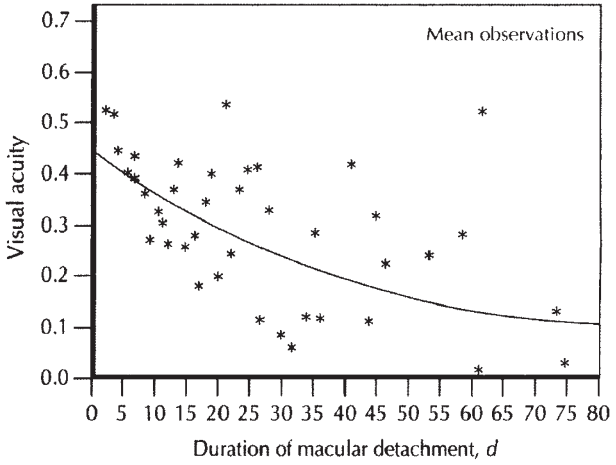

Figure 1 Non-linear regression curve superimposed on means of postoperative visual acuities. Equation $y = ae^{-bx}$ describes negative exponential relationship between visual recovery and duration of macular detachment (n = 205). From Burton.[10]

examination. There were four primary failures, and these were also excluded from the study. Therefore, 100 patients remained with macula-off detachments of 7 days' duration or less, who had no pre-existing ocular disease and had successful repair with one procedure.

The preoperative acuity was documented by the examining retinal surgeon. The best corrected postoperative vision was determined by the referring ophthalmologist at a point 6 months post-surgery or beyond. Snellen visual acuities were converted to logMAR units to create a linear scale of visual acuity. To apply parametric statistical testing, the patients were divided into three groups based on duration of macular detachment, with group 1 consisting of patients with macular detachment of 1–2 days' duration (n = 30), group 2, 3–4 days' duration (n = 32), and group 3, 5–7 days duration (n = 38) There were sufficient numbers in each group to demonstrate a difference of 0.28 logMAR units (approximately three Snellen acuity lines) among the three groups or a doubling of the visual angle. This difference was similar to that used in the Early Treatment of Diabetic Retinopathy Study (ETDRS).

The patient's age at the time of presentation, preoperative visual acuity, status of the crystalline lens, location of the detachment, and drainage or nondrainage of subretinal fluid were analyzed as to their effect on postoperative visual acuity. The surgical repair was either a circumferential solid silicone element with an encircling band or a radial silicone sponge with an encircling silicone band. Drainage of subretinal fluid wad done at the discretion of the surgeon. Air, sulfur hexafluoride, or perfluoro propane gas was used as needed for temporary internal tamponade. Statistical analysis was done using the Minitab for Windows software (Microsoft).

The mean age of the patients was 59.4 years (range 16–88 years). The mean duration of macular detachment was 3.98 days (range 107 days). Patients were followed for 6–38 months with a mean follow-up of 10.8 months.

The mean preoperative visual acuity in all three groups was 1.46 logMAR (20/580 Snellen acuity). The mean preoperative acuities in the three comparison groups were statistically similar (analysis of variance P = 0.369, Figure 2). The distributions of preoperative acuities in the three groups were also similar (Figure 3). The mean postoperative visual acuity for all three groups was 0.48 logMAR (20/60 Snellen acuity; Figure 4). The postoperative acuity demonstrated considerable variability in the results, regardless of the duration of macular detachment (Figure 5). An analysis of variance test indicated that the postoperative acuities for the

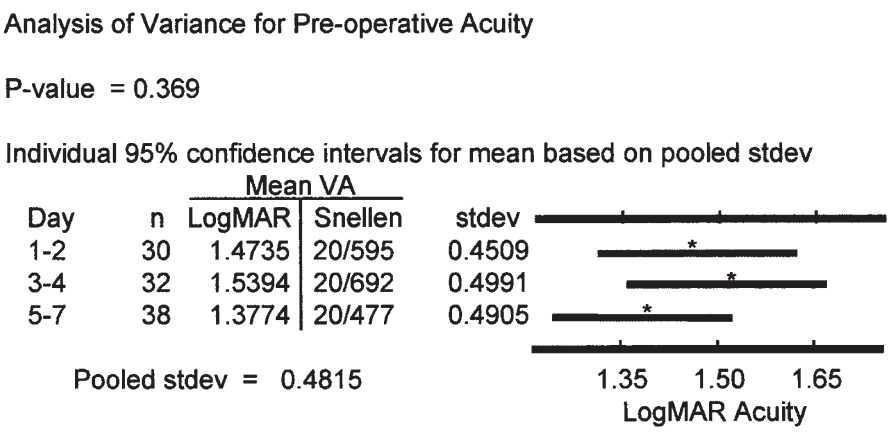

Figure 2 Analysis of variance for preoperative acuity P-value = 0.369. Individual 95% confidence intervals for mean based on pooled SD.

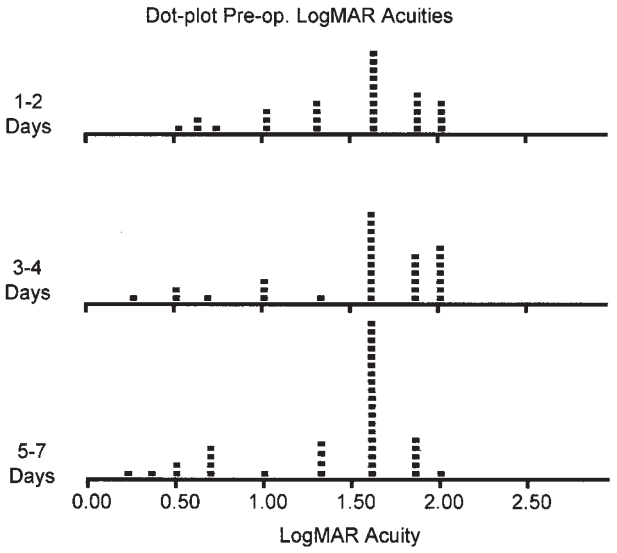

Figure 3 Dot-plot of preoperative LogMAR acuities.

three groups was statistically the same with no difference in the mean acuity, despite the difference in the timing of the detachment repair after macular involvement ($P = 0.533$; Figure 4). The mean age of the comparison groups was identical at 59 years. Thus, the patient's age did not influence the results regarding the duration of macular detachment and postoperative best corrected acuity.

Subretinal fluid was drained via an external sclerotomy in the bed of the buckle in 49% of patients. Conversely, 51% of patients did not have the fluid drained. The subgroups did not differ statistically in their preoperative acuity ($P = 0.76$, two-sample *t*-test), but the postoperative acuity in the nondrainage group was better than that in the drainage group (20/71 *vs* 20/53) and approached statistical significance ($P = 0.062$, Student's *t*-test). This mirrors the findings of the pneumatic retinopexy study[15] in which visual acuity was superior in patients who underwent pneumatic retinopexy procedures than in those who underwent scleral buckling operations with drainage of subretinal fluid. It has been suggested that the slow gentle reposition of the photoreceptors to the retinal pigment epithelium in non-drainage cases allows for more accurate alignment of this complex, and therefore better final visual acuity.

Finally, 59% of patients were phakic and 41% were pseudophakic or aphakic. Those patients who were aphakic or pseudophakic had worse postoperative vision when compared to their phakic counterparts ($P = 0.0045$), but they also were statistically older, as expected ($P = 0.035$).

The data presented in this paper support the contention that good preoperative vision does portend a better postoperative result. Of those patients in this series who had acuities of 1.00 logMAR or better (20/100), the mean postoperative visual acuity was 0.275 logMAR (20/38). Converseley, those with visual acuity worse than 1.00 logMAR at initial examination had mean postoperative visual acuity of 0.542 logMAR 20/70 ($P < 0.0001$, Student's *t*-test).

The main finding in this series is that the recovery of vision was equal in the 1–2, 3–4, and 5–7 days of macular detachment. Approximately 60% in all three groups regained 20/50 or better vision, 35% regained 20/60 to 20/200 vision, and 5% had less than 20/400 vision (Table 1). Although some series have reported similar results,[10,16,17] most large series of macula-off detachments report a recovery of 20/60 visual acuity in only approximately 42% of patients.[4,6,18,19] This difference in recovery of central vision could be explained by not excluding patients with preoperative ocular pathology, drainage of subretinal fluid in the vast majority of patients, a delay of surgery greater than 7 days and a shorter follow-up period.[10,20–24]

The main conclusion of this study is that duration of macular detachment within the first week did not influence postoperative acuity. The implications are that, despite intuitive notions regarding outcomes in macula-off detachment, there is no improvement in final visual acuity, even with more expedient repair within the first week. Macula-off detachments can therefore be treated with less urgency and can wait for the next scheduled available operating room time.



Figure 4 Analysis of variance for postoperative acuity *P*-value = 0.533. Individual 95% confidence intervals for mean based on pooled SD.

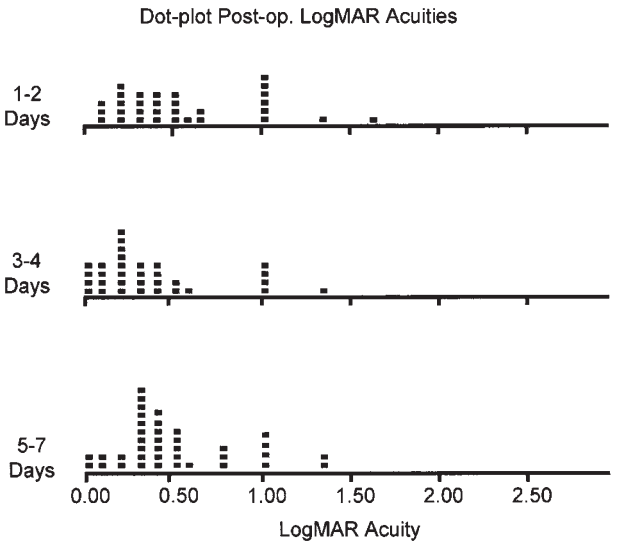

Figure 5 Dot-plot of postoperative LogMAR acuities.

Table 1 Recovery of Snellen visual acuity in the three groups

Group	⩾20/50	20/60–20/200	<20/200
1–2 days	52%	42%	6%
3–4 days	65%	32%	3%
5–7 days	61%	34%	5%

Elective retinal detachment repair is also supported by the findings and recommendations of Hartz *et al*.[25] In their study, which compared emergency *vs* scheduled retinal detachment surgery, there was no evidence that delaying the surgery contributed to a worse visual outcome regardless of the status of the macula. Patients who underwent scheduled or emergency surgery had similar outcomes, but the cost of emergency surgery was 25% more costly than that of scheduled surgical procedures.

Although most patients who undergo retinal detachment surgery have stable vision 3–6 months after surgery, vision continues to improve in a subgroup of patients up to 5 years after surgery. Postoperative recovery of vision has been studied previously by Gundry and Davies[21] and by Kreissig.[22] A recent publication by Liem *et al*[26] using foveal densitometry has shown recovery of cone photo-pigments after reattachment. The improved foveal cone photo-pigments might be attributed to: (1) regrowth and realignment of photoreceptor outer segments; and (2) metabolic recovery of the pigment epithelium photoreceptor complex.

In 1998, Kusaka *et al*[27] published an interesting article in the Japanese literature on long-term visual recovery. They retrospectively investigated the long-term visual recovery in 32 macula-off retinal detachments that had been followed up for more than 5 years after surgery. They found that the best corrected visual acuities were better at 5 years than at 3 months by two lines or more in 17 eyes (53%). In these 17 eyes, visual acuity continued to improve for up to 10 years after surgery. The remaining 15 eyes demonstrated best corrected acuities that remained within one line of the 3-month values. The eyes that demonstrated long-term improvement in the postoperative period were found to be statistically correlated with younger age, no or mild myopia (less than −5.00 D), and shorter duration of macular detachment (30 days or less). Surgeons involved in retinal detachment surgery should be aware that function based on acuity testing may continue to improve over the long term, most notable when these factors are present.

The variability of postoperative visual results leads us to speculate as to the etiology of these results. As our data indicate, some patients with macula-off detachments for 1–2 days did not regain visual acuity of greater than 20/50, whereas other patients whose macula was off 5–7 days regained 20/20 visual acuity. This difference in recovery of vision could be explained by the height of the macular detachment at the time of retina surgery. Clinical studies, animal experiments, and recent optical coherence tomography studies support this hypothesis. Previous clinical studies have shown a positive relationship between the extent of the retinal macular elevation and final visual acuity. In the article by Tani *et al*,[28] a study of specific morphologic changes in the macula was undertaken to learn whether they had any predictive value regarding final visual acuity. The extent of retinal elevation at the fovea, cystoid macular edema, and preretinal fibrosis was graded. These factors were studied by multivariate regression analysis. Only the extent of macular retinal elevation showed a positive relationship to final visual acuity. Davidorf, Havener, and Lang[29] also showed that macular elevation was an important factor in predicting final visual acuity. Animal experiments also support this concept. In experimental detachments in owl monkeys, Machemer[30] found that photoreceptor cell degeneration increased as the distance between the pigment epithelial layer and the photoreceptors increased.

A recent publication by Hagimura *et al*[13] used optical coherence tomography (OCT) to study the macula in 25 patients with macula-off rhegmatogenous retinal detachments. In patients with minimal elevation of the retina at the macula, there was less disruption of the neurosensory retina. The detached retina was thicker but showed no intraretinal abnormalities. With more elevated detachments, the macula showed intraretinal

separation of the neurosensory retina and an undulated separated outer retina. A negative correlation was observed between the preoperative best corrected visual acuity and the height of retinal detachment at the central macula. The fact that the best corrected acuity was more impaired in the highly detached retinas, suggests that irreversible nutritional damage to the macula occurs in highly elevated detachments of short duration. This could explain why some macular detachments of only 1–2 days duration do not regain better than 20/60 vision.

During the past 20 years, the anatomic success rate and visual recovery in patients with macula off retinal detachments has improved considerably. Today, we can expect a 90% or greater primary success rate and a final reattachment rate of over 95% with detachment surgery. Return of central vision to 20/50 or better in macula off detachments has also increased from approximately 42% to between 60% and 80% of cases.

Pneumatic retinopexy, scleral buckling and primary vitrectomies with or without buckles have all been proven to be effective in repairing retinal detachments. The best approach to surgery is to start with the simplest method of repair and to proceed to more invasive surgery as the pathology dictates.

In 1986, Hilton and Grizzard[31] reported the first series of detachments successfully treated with pneumatic retinopexy. The main advantage of pneumatic retinopexy surgery is that it can be done in an outpatient setting using subconjunctival or retrobulbar anesthesia. In patients who present with retinal detachments with break(s) not exceeding 1 clock hour, within the superior 8 clock hours of the retina and without signs of proliferative vitreoretinopathy, pneumatic retinopexy can be used as the initial procedure whether the patient is phakic or pseudophakic. In a multicentre randomized controlled clinical trial,[15] a primary anatomic success rate was achieved in 75% of phakic eyes and 67% in pseudophakic eyes. A visual acuity of 20/40 or better was achieved in 65–80% of patients who underwent repair of macula off detachments within a 14-day period. If the detachment does not respond to the initial procedure, the ultimate anatomic success with more conventional buckling or vitrectomy surgery is not adversely affected. An overall 95% success rate of pneumatic retinopexy patients who required scleral buckling and/or vitrectomy surgery in subsequent procedures was reported.[32] This compared favorably with the multiple operations success rate of failed initial buckling surgery. The main disadvantage of retinopexy surgery is the development of new retinal breaks which has been reported in up to 23% of patients. Therefore, these patients require close follow-up until the gas bubble reabsorbs. Another disadvantage is the need for postoperative positioning which can be difficult for elderly patients.

Scleral buckling has stood the test of time and remains the method of choice in repairing retinal detachments. An initial 93–96%[14,33] anatomic success rate can be expected whether the patient is phakic or pseudophakic. When scleral buckling surgery is performed, nondrainage of subretinal fluid is preferable to drainage.[14] With the use of one or two anterior chamber paracentheses, a good indentation with silicone explants can be achieved for up to 270 degrees of detachment in both phakic and pseudophakic patients with intact capsules. In pseudophakic patients with open capsules, a 360 degree buckle can be obtained using this technique. When indicated, the injection of a short acting gas can also be used for the internal tamponade of retinal breaks. When drainage of subretinal fluid is necessary, it should be performed in the bed of the scleral buckle so that the potential complications of retinal incarceration and subretinal hemorrhage can be managed effectively.

In the past 5 years, primary pars plana vitrectomy with or without a scleral buckle has been found to be effective in repairing pseudophakic retinal detachments. High speed vitrectomy cutters, wide angle panoramic viewing systems, the general availability of endolaser and indirect ophthalmoscopic laser delivery systems and the availability of liquid perfluorocarbons and gas tamponades, have been responsible for this development. Primary vitrectomy allows for the removal of retained cortical lens material, vitreous opacities and a better view of the peripheral retina. It also allows for controlled drainage of subretinal fluid through a posterior retinotomy or posterior break or with the use of liquid perfluorocarbons through a peripheral retinal tear. Laser photocoagulation can be easily applied to retinal breaks and to the peripheral retina in an air-filled eye.

In a series of 78 pseudophakic or aphakic eyes, Speicher *et al*[34] reported a 90% initial reattachment rate after one procedure. In patients with a macula-off detachment, 80% achieved 20/50 or better vision. Campo *et al*[35] reported an initial success rate of 86% of 275 patients who underwent primary vitrectomy for pseudophakic or aphakic detachments and 65% of patients who presented with macula-off detachments regained 20/50 or better vision. With combined vitrectomy and scleral buckling surgery, Desai and Strassman[36] and Devenyi[37] achieved 100% primary success rate. Bartz-Schmidt[38] and Pournaras[39] reported a 94 and 92% primary success rate respectively using combined surgery. Both Devenyi and Bartz-Schmidt

used liquid perfluorocarbons to drain sub-retinal fluid through anterior retinal breaks in their series.

In patients who present with extensive retinal detachments complicated by advanced proliferative vitreoretinopathy, a combined pars plana vitrectomy and scleral buckling procedure will result in a higher initial anatomic reattachment rate. In these cases of severe proliferative vitreoretinopathy (PVR), the use of long acting C3F8 gas or silicone oil has been found to be very effective.

In summary, in the past 20 years, we have witnessed major progress in the management of retinal detachments. The use of intravitreal gas, wide angle viewing systems, silicone oil and liquid perfluorocarbons have all contributed to an increased anatomic success rate and a better functional visual result.

References

1 Chignell AH, Fison LG, Davies EWG *et al*. Failure in retinal detachment surgery. *Br J Ophthalmol* 1973; **57**: 525.
2 Burton TC. Preoperative factors influencing anatomic success rates following retinal detachment surgery. *Trans Am Acad Ophthalmol Otolaryngol* 1977; **83**: OP499.
3 Lincoff H. Should retinal breaks be closed at the time of surgery? In: Brockhurst RJ, Boruchoff SA, Hutchinson BT, Lessell S (eds). *Controversy in Ophthalmology*. WB Saunders: Philadelphia, 1977, pp 582–598.
4 Hilton GF, McLean EB, Norton EWD. *Retinal Detachment*, 3rd edn. American Academy of Ophthalmology: Rochester, 1979.
5 Rachal WF, Burton TC. Changing concepts of failure after retinal detachment surgery. *Arch Ophthalmol* 1979; **97**: 480.
6 Wilkinson CP, Bradford RH Jr. Complications of draining subretinal fluid. *Retina* 1984; **4**: 1.
7 Cowley M, Conway BP, Campochiara PA *et al*. Clinical risk factors for proliferative vitreoretinopathy. *Arch Ophthalmol* 1989; **107**: 1147.
8 Sharma T, Challa JK, Ravishankar KV *et al*. Scleral buckling for retinal detachment. Predictors for anatomic failure. *Retina* 1994; **14**: 338.
9 Grizzard WS, Hilton GF, Hammer ME *et al*. A multivariate analysis of anatomic success of retinal detachments treated with scleral buckling. *Graefes Arch Clin Exp Ophthalmol* 1994; **232**: 1.
10 Burton TC. Recovery of visual acuity after retinal detachment involving the macula. *Trans Am Ophthalmol Soc* 1982; **80**: 475.
11 Burton TC, Lambert RW Jrt. A predictive model for visual recovery following retinal detachment surgery. *Ophthalmology* 1978; **85**: 619.
12 Tani P, Robertson DM, Langworthy A. Prognosis for central vision and anatomic reattachment in rhegmatogenous retinal detachment with macula detached. *Am J Ophthalmol* 1981; **92**: 611–616.
13 Hagimura N *et al*. Optical coherence tomography of the neurosensory retina in rhegmatogenous retinal detachment. *Am J Ophthalmol* 2000; **129**: 186–190.
14 Ross WH, Kozy DW. Visual outcome in macula-off rhegmatogenous retinal detachments. *Ophthalmology* 1998; **105**: 2149–2153.
15 Tornambe PE, Hilton GF. The Retinal Detachment Study Group: Pneumatic retinopexy. A multicenter randomized controlled clinical trial comparing pneumatic retinopexy with scleral buckling. *Ophthalmology* 1989; **96**: 772–784.
16 Hilton GF, Norton EWD, Curtin VT *et al*. Retinal detachment surgery: a comparison of diathermy and cryosurgery. *Mod Probl Ophthalmol* 1969; **8**: 440–448.
17 Gruppossо SS. Visual acuity following surgery for retinal detachment. *Arch Ophthalmol* 1975; **93**: 327.
18 Norton EWD. Retinal detachment in aphakia. *Tran Am Ophthalmol Soc* 1963; **61**: 770–789.
19 Johnston GP, Arribas NP, Okun E, Boniuk I. Visual prognosis following successful retinal detachment surgery. In: Pruett RC, Regan CD (eds). *Retina Congress*. Appleton-Century-Crofts: New York, 1972, p 617.
20 Davies EWG. Factors affecting recovery of visual acuity following detachment of the retina. *Trans Ophthalmol Soc UK* 1972; **92**: 335.
21 Gundry MF, Davies EWG. Recovery of visual acuity after retinal detachment surgery. *Am J Ophthalmol* 1974; **77**: 310.
22 Kreissig I. Prognosis of return of macular function after retinal reattachment. *Mod Probl Ophthalmol* 1977; **18**: 415.
23 Jay B. The functional cure of retinal detachments. *Trans Ophthalmol Soc UK* 1965; **85**: 101–110.
24 Marquez FM. Functional results of retinal detachment surgery. *Mod Probl Ophthalmol* 1979; **20**: 330–332.
25 Hartz AJ, Burton TC, Gottlieb MS *et al*. Outcome and cost analysis of scheduled versus emergency scleral buckling surgery. *Ophthalmology* 1992; **99**: 1358–1363.
26 Liem ATA, Keunen JEE, vanMeel JG, vanNorren Dirk. Serial foveal densitometry and visual function after retinal detachment surgery with macular involvement. *Ophthalmology* 1994; **101**: 1945–1952.
27 Kusaka S, Toshino A, Ohashi Y, Sakaue E. Long-term visual recovery after scleral buckling for macular-off retinal detachments. *Jpn J Ophthalmol* 1998; **42**: 218–222.
28 Tani P, Robertson DM, Langworthy A. Rhegmatogenous retinal detachment without macular involvement treated with scleral buckling. *Am J Ophthalmol* 1980; **90**: 503–508.
29 Davidorf FH, Havener WH, Lang JR. Macular vision following retinal detachment surgery. *Ophthalmol Surg* 1975; **6**: 74.
30 Machemer R. Experimental retinal detachment in the owl monkey. Histology of retina and pigment epithelium. *Am J Ophthalmol* 1968; **66**: 396.
31 Hilton GF, Grizzard WS. Pneumatic retinopexy – a two-step outpatient operation without conjunctival incision. *Ophthalmology* 1986; **93**: 626–640.
32 Thornambe PE. Pneumatic retinopexy. *Surv Ophthalmol* 1988; **32**: 270–281.
33 Wilkinson CP. Pseudophakic retinal detachments. *Retina* 1985; **5**: 1–4.
34 Speicher MA, Fu AD, Martin JP, Von Fricken MA *et al*. Primary vitrectomy alone for repair of detachments following cataract surgery. *Retina* 2000; **20**: 459–464.
35 Campo RV, Sipperley JO, Sneed SR, park DW, Dugel PU, Jacobsen J *et al*. Pars plana vitrectomy without scleral buckle for pseudophakic retinal detachments. *Ophthalmology* 1999; **106**: 1811–1816.
36 Desai UR, Strassman IB. Combined pars plana vitrectomy and scleral buckling for pseudophakic and aphakic retinal

detachments in which a break is not seen preoperatively. *Ophthalmic Surg Lasers* 1997; **28**: 718–722.
37 Devenyi RG, Nakamura HC. Combined scleral buckle and pars plana vitrectomy as a primary procedure for pseudophakic retinal detachments. *Ophthalmic Surg Lasers* 1999; **30**: 615–618. 1997; **28**: 718–722.
38 Bartz-Schmidt KU, Kirchof B, Heiman K. Primary vitrectomy for pseudophakic retinal detachment. *Br J Ophthalmol* 1996; **80**: 346–349.
39 Pournaras CJ, Donati G, Sekkat L, Kapetanios AD. Pseudophakic retinal detachment: treatment by vitrectomy and scleral buckling. Pilot study. *J Fr Ophthalmol* 2000; **20**: 1006–1011.