

## Letter to the Editor

# Muir Torre syndrome and MSH2 mutations: the importance of dermatological awareness

M Tischkowitz<sup>\*1</sup>, A Gologan<sup>2</sup>, H Srolovitz<sup>2</sup>, M Khanna<sup>3</sup> and WD Foulkes<sup>1</sup>

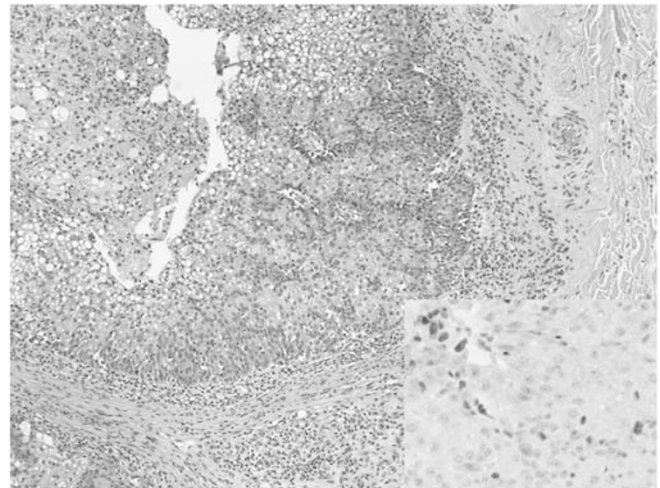
<sup>1</sup>Cancer Prevention Centre, Sir MB Davis Jewish General Hospital, McGill University, Montreal, QC, Canada; <sup>2</sup>Department of Pathology, Sir MB Davis Jewish General Hospital, McGill University, Montreal, QC, Canada; <sup>3</sup>Division of Dermatology, Department of Medicine, Sir MB Davis Jewish General Hospital, McGill University, Montreal, QC, Canada

British Journal of Cancer (2006) 95, 243–244. doi:10.1038/sj.bjc.6603228 www.bjcancer.com  
Published online 20 June 2006  
© 2006 Cancer Research UK

Sir,

We would like to give an update on a family with Lynch syndrome (hereditary non-polyposis colorectal cancer, HNPCC) that we have previously reported with germline truncating mutations in *MSH2* (exon 8 deletion) and *BRCA2* (542G>T) (Thiffault *et al*, 2004). This was a 26-member kindred with five cases of colorectal cancer and five cases of breast cancer, all but one of the cancers occurring below the age of 45 years. We reported that one of the individuals who had been diagnosed with rectal cancer (III.10 in original pedigree) also had a keratoacanthoma. This type of skin lesion is seen in some families with *MSH2* or, less commonly, *MLH1* mutations when it is termed Muir–Torre Syndrome (MTS) (Ponti and Ponz de Leon, 2005). Immunohistochemistry (IHC) at the time showed normal *MSH2* expression, so we felt that this family did not belong to the MTS group. Subsequently, the individual was diagnosed with two separate sebaceous carcinomas on each arm. Immunohistochemistry analysis of these lesions shows loss of *MSH2* expression in both cases, one of which is shown in Figure 1, confirming that this is in fact an MTS family.

This new development illustrates two points. Firstly the Lynch syndrome and MTS phenotypes are pleiotropic and Lynch syndrome can evolve into MTS in the same family. Lynch syndrome is usually suspected when the Amsterdam Criteria are fulfilled or the less-specific Bethesda guidelines are met. The individual described here had an anal canal squamous carcinoma, a cancer type not associated with Lynch syndrome, which was microsatellite stable. His father, who was an obligate *MSH2* mutation carrier, had a rectal cancer which is also unusual (Hoogerbrugge *et al*, 2003), and an astrocytoma, raising the possibility of overlap with another variant, Turcot syndrome. Although Turcot syndrome was classically thought of as a combination of brain tumours and polyposis and has been mainly associated with mutations in the *APC* gene (Galiatsatos and Foulkes, 2006), a minority are also due to mutation in the Lynch syndrome genes, particularly biallelic PMS mutation carriers (De Vos *et al*, 2006). Secondly, the case emphasises the importance of continuing dermatological vigilance in *MSH2* families. The same



**Figure 1** Sebaceous carcinoma: haematoxylin and eosin ( $\times 100$ ): multilobulated expansile intradermal tumour showing large polygonal cells with differentiation into sebaceous cells, altered nuclear/cytoplasmic ratio, evidence of apoptosis and high mitotic count. Insert: *MSH2* immunohistochemical stain ( $\times 400$ ): Absence of nuclear staining for the *MSH2* mismatch repair protein in the tumour cells (the tumour infiltrating lymphocytes show normal expression of *MSH2*).

*MSH2* mutations are found in both MTS and Lynch families (Ponti and Ponz de Leon, 2005), so it is not possible to predict which families are more likely to develop MTS. The sebaceous cancers in MTS are possibly less aggressive than sporadic types (Ponti and Ponz de Leon, 2005), but little is known about survival in MTS.

## REFERENCES

De Vos M, Hayward BE, Charlton R, Taylor GR, Glaser AW, Picton S, Cole TR, Maher ER, McKeown CM, Mann JR, Yates JR, Baralle D, Rankin J,

Bonthron DT, Sheridan E (2006) PMS2 mutations in childhood cancer. *J Natl Cancer Inst* 98: 358–361  
Galiatsatos P, Foulkes WD (2006) Familial adenomatous polyposis. *Am J Gastroenterol* 101: 385–398

\*Correspondence: Dr M Tischkowitz; E-mail: marc.tischkowitz@mcgill.ca  
Published online 20 June 2006

- Hoogerbrugge N, Willems R, Van Krieken HJ, Kiemeneij LA, Weijmans M, Nagengast FM, Arts N, Brunner HG, Ligtenberg MJ (2003) Very low incidence of microsatellite instability in rectal cancers from families at risk for HNPCC. *Clin Genet* **63**: 64–70
- Ponti G, Ponz de Leon M (2005) Muir-Torre syndrome. *Lancet Oncol* **6**: 980–987
- Thiffault I, Hamel N, Pal T, McVety S, Marcus VA, Farber D, Cowie S, Deschenes J, Meschino W, Odefrey F, Goldgar D, Graham T, Narod S, Watters AK, MacNamara E, Du Sart D, Chong G, Foulkes WD (2004) Germline truncating mutations in both MSH2 and BRCA2 in a single kindred. *Br J Cancer* **90**: 483–491