IN BRIEF

- Local dental infections may spread rapidly and cause serious and even life threatening disease.
- The importance of prompt accurate diagnosis and management is discussed.
- Pathways of spread of oral and dental infections are analysed.

Mediastinitis from odontogenic infection. A case report

H. Pappa[1] and D. C. Jones[2]

We report a case of mediastinitis complicating a dental infection in a 40-year-old male. Despite drainage of the localised neck abscess and the administration of systemic antibiotics, his submandibular abscess extended to involve the pericardial and pleural cavities. Drainage procedures and thoracotomies were required to treat the empyema and purulent pericarditis. Computed tomography was used to follow the progression of disease and assess the efficacy of treatment.

INTRODUCTION

Acute mediastinitis is a life-threatening infection involving the mediastinal connective tissue that fills the interpleural space and surrounds the adjacent thoracic organs. The majority of cases result from oesophageal perforation, or as a consequence of a post-operative infection after sternotomy.

Acute purulent mediastinitis is a rare complication of oropharyngeal infection in which case it is termed descending necrotising mediastinitis (DNM). Despite the presently available broad-spectrum antibiotic therapy, DNM remains a very serious disease with a reported 30-40% mortality rate.[1]

Several factors contribute to this high mortality, including the rapid spread of the infection, delay in making the diagnosis, poor general health, generalised sepsis and major respiratory and cardiac complications. Proper mediastinal drainage, aggressive long-term combination antibiotics and adequate nutritional support constitute the cornerstones of management.

[1*]Craniofacial Fellow, Alder Hey Children's Hospital, Eaton Road, Liverpool, L12 2AP; [2]Consultant Maxillofacial Surgeon, University Hospital Aintree, Lower Lane, Liverpool, L9 7AL.
Correspondence to: Dr Helena Pappa
Email: pappaelena@hotmail.com

Refereed Paper
Received 18.03.04; Accepted 15.11.04
doi: 10.1038/sj.bdj.4812302

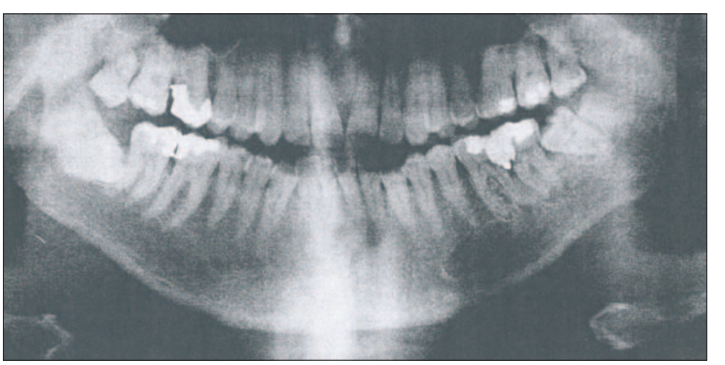

Fig. 1 Chronic periapical infection from the lower left first and second molars

CASE REPORT

A 40-year-old man was admitted with a diagnosis of submandibular abscess, as a complication of dental treatment of the mandibular molars. He had had restorations placed in his lower left first and second molars six months previously. Five days before his admission he experienced toothache and his dentist removed the fillings, placed temporary dressings and prescribed antibiotics. Over the following few days, his symptoms became more severe and he self-referred to hospital. On examination there was swelling in the left submandibular region extending down the neck. The patient complained of hoarseness of his voice, numbness of his lower lip, dysphagia and marked trismus. He was pyrexic and tachycardic. Radiographs showed evidence of chronic periapical infection from the lower left first and second molars. (Fig. 1) Laboratory investigations revealed leucocytosis with neutrophilia and a raised C-reactive protein.

His medical history included severe ankylosing spondylitis with bilateral hip replacement three months earlier. His medication included non-steroidal anti-inflammatories and analgetics, which were not considered likely to cause compromise of his immunology profile which was normal.

Despite the drainage of the submandibular abscess, the extractions of first and second mandibular molars and the intravenous administration of antibiotics, the patient remained systemically unwell and the

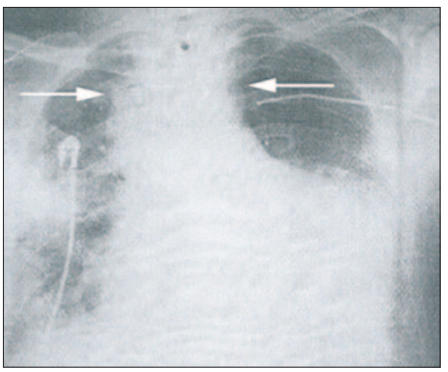

Fig. 2 Chest radiograph showing a widened mediastinal configuration

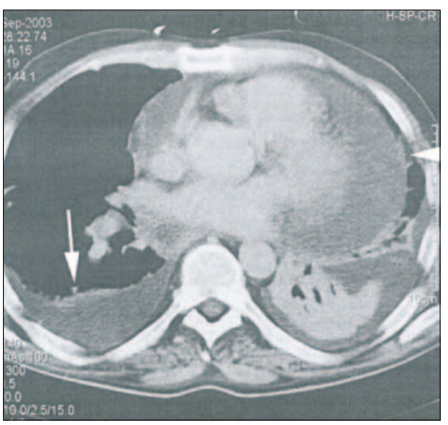

Fig. 3 CT scan thorax shows bilateral pleural effusions and a large pericardial effusion

swelling extended to the anterior neck. He developed respiratory distress and was taken to theatre where his airway was secured by the means of a tracheostomy. The parapharyngeal, submandibular, submasseteric, and extramasseteric spaces were explored and further collections of pus drained. Three drains were inserted and the lower left third molar removed. Post-operatively he was transferred to the intensive care unit.

Culture and sensitivity of the drained pus revealed mixed aerobic and anaerobic flora. Clindamycin was added into his existing antibiotic regime of Benzyl Penicillin, Metronidazole, and Cefotaxime. However, his condition continued to deteriorate and he developed atrial flutter and signs of systemic sepsis.

A chest radiograph showed widening of the mediastinum (Fig. 2) and computerised tomography (CT) demonstrated air spaces in the neck, bilateral pleural and pericardial effusions and partial collapse of the left lower lobe (Fig. 3).

The patient was transferred to the regional cardiothoracic unit where the pericardial effusion was drained through a subxiphoid incision. The mediastinal abscess and the right pleural effusion were drained by a right anterior mediastinotomy. A left intercostal tube was inserted to drain the left side of the chest. The thoracic cavity was irrigated with povidone iodine solution.

Five days following this procedure, a repeat CT scan showed persistent collection within the mediastinum (Fig. 4). Right thoracotomy was performed and the residual collection of pus at the apex of the chest and mediastinum was drained. His subsequent recovery was slow but uneventful. He was discharged 45 days after initial admission.

DISCUSSION

Estrera has proposed three criteria for the diagnosis of mediastinitis of odontogenic origin:[1]

1. Clinical evidence of severe oropharyngeal infection.
2. Characteristic radiological features of mediastinitis (radiographs of the chest will generally show gas in the tissues, air fluid levels, and mediastinal widening).
3. Establishment of the relationship between mediastinitis and the oropharyngeal process. There are three primary routes of the infection spreading from the neck to the mediastinum (Fig. 5):
   a) Via the pretracheal space which descends into the anterior mediastinum. Its fascia fuses with the pericardium and the parietal pleura. This explains the occurrence of empyema and pericardial effusion in our case.
   b) Via the viscerovascular space, and
   c) Via the retropharyngeal space. This is the most frequent route for descending mediastinitis to spread into the posterior mediastinum and the diaphragm.

Bacteriologically, mediastinitis from odontogenic infection is most frequently a polymicrobial process with anaerobes playing a major role. The synergistic action of aerobic and anaerobic organisms may explain the virulence of the infection. Howell *et al.*[2] have described numerous complications of mediastinal infection such as empyema, erosion of the aorta, costal osteomyelitis, aspiration pneumonia, and recurrent abscesses. Four approaches for mediastinal drainage have been reported: transcervical,[3] standard thoracotomy,[4] and transthoracic via a subxiphoid[5] or clamshell incision.[6]

Roberts *et al.*[7] reported a case of thoracoscopic drainage and debridement of a posterior mediastinal abscess and emphasised the decreased morbidity of this approach compared with thoracotomy, and the improved drainage compared with cervical drainage alone.

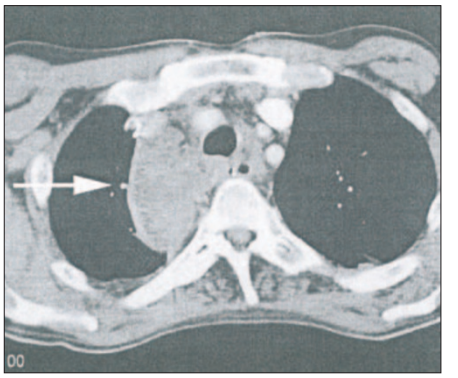

Fig. 4 CT scan thorax shows persistent right mediastinal collection

CONCLUSION

Descending mediastinitis is a rare but extremely serious complication of an oropharyngeal infection. Dental practitioners should be aware that early diagnosis and aggressive management are required to reduce the morbidity and mortality of the disease. Effective management requires appropriate airway management and drainage of the regions affected by the disease. Antibiotic treatment should be with broad-spectrum agents and guided by culture of drained pus. CT scanning in addition to clinical findings aids assessment of disease progression.

1. Estrera A S, Landay M J, Grisham J M, *et al.* Descending necrotising mediastinitis. *Surg Gynecol Obstet* 1983; **157:** 542-552.
2. Howell H S, Prinz R A, Pickleman J R. Anaerobic mediastinitis. *Surg Gynecol Obstet* 1976; **143:** 353-359.
3. Levine T M, Wurster C F, Krespi Y P. Mediastinitis occurring as a complication of odontogenic infections. *Laryngoscope* 1986; **96:** 747.
4. Marty-Ane C H, Alauzen M, Alric P, *et al.* Descending necrotising mediastinitis: Advantage of mediastinal drainage with thoracotomy. *J Thorac Cardiovasc Surg* 1994; **107:** 55.
5. Wheatley M J, Stirling M C, Kirsh M M, *et al.* Descending necrotising mediastinitis: Transcervical drainage is not enough. *Ann Thorac Surg* 1990; **49:** 780.
6. Ris H B, Banic A, Furrer M, *et al.* Descending necrotising mediastinitis: Surgical treatment via clamshell approach. *Ann Thorac Surg* 1996; **62:** 1650.
7. Roberts J R, Smythe R, Weber R W, *et al.* Thorascoplc management of descending mediastinitis. *Chest* 1997; **117:** 850.

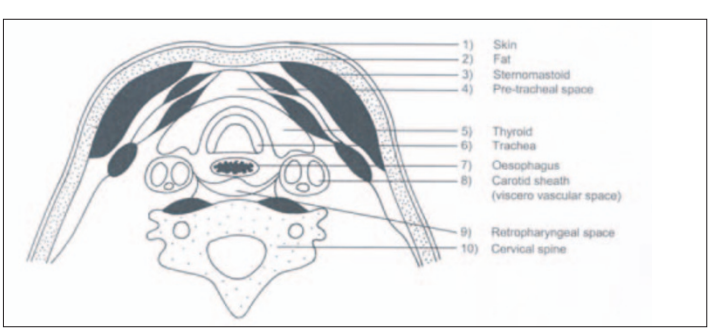

Fig. 5 Anatomy of the neck and spaces that facilitate the spread of the infection to the mediastinum