

IN BRIEF

- Experience gained through a study of a case series of 40 large dentigerous cysts treated during an 11-year period from 1991 to 2002 is presented along with the clinical presentations and treatment modalities.
- Several modalities were indicated based on criteria such as patient age, cyst site, cyst size, involvement of vital structures by the cyst, and the strategic significance of the impacted tooth involved.
- In this series, cyst enucleation along with extraction of the impaction(s) was indicated in 34 patients. Cyst enucleation with preservation of the impacted tooth was indicated in six patients and these teeth erupted normally when root formation was incomplete. Orthodontics was used in cases requiring forced eruption or alignment.
- Decompression and cyst enucleation with tooth preservation are two treatment modalities indicated in growing children and adolescents.

Management of extensive dentigerous cysts

M. H. K. Motamedi¹ and K. T. Talesh²

Dentigerous cysts are usually easy to treat when small. However, extensive cysts are more difficult to manage requiring cyst enucleation and extraction of associated teeth. We advocate the use of assessment criteria to dictate the treatment modality indicated in each individual case such as cyst size and site, patient age, the dentition involved, and the involvement of vital structures. Cyst enucleation without extraction of the impaction, and decompression are two treatment modalities indicated in growing children and adolescents to salvage the involved dentition.

The dentigerous cyst is the second most common cyst of the jaws comprising 14–20 per cent of all jaw cysts, and they are more frequent in males and more common in the mandible.^{1–4} By definition, this lesion is attached to the cervix of an impacted tooth and results from proliferation of reduced enamel epithelium after the enamel formation. Dentigerous cysts are usually discovered on routine radiographic examination or when films are taken to determine the reason for failure of a tooth to erupt. They are always radiolucent and usually unilocular, although large lesions occasionally show a scalloping multilocular pattern.^{3–6}

Third molars followed by maxillary canines (the most commonly impacted teeth) and occasionally supernumerary teeth or odontomas are involved in cyst formation. Their pathogenesis remains unknown.

Proliferation of the epithelium in a fluid-filled sac may be induced by osmotic pressure during the extended period of time the tooth is impacted. Were the tooth to erupt, the dentigerous cyst would burst and cease to be a pathologic entity, as is usually the case in small eruption cysts.^{1–4} Small cysts are also easy to treat surgically.

However, dentigerous cysts occasionally become extensive since lesions are asymptomatic even when reaching considerable size and then treatment is more difficult as associated teeth are often impacted and displaced a considerable distance due to cyst pressure; surgery may require removal of several teeth or tooth buds or endanger vitality of adjacent teeth. Nevertheless, because of the many damaging sequelae, dentigerous cysts must be surgically eliminated.

Methods employed for elimination have included decompression, marsupialisation, and enucleation.^{1–4} However, the criteria for selecting these treatment modalities (indications and contraindications) are not clearly defined. Moreover, large study series and long-term follow-up to assess various treatment results, recurrence, and to compare demographic data, are lacking in the literature.

CASE SERIES

During an 11-year period from 1991–2002, 40 cases of extensive (involving three or more teeth) dentigerous cysts of the maxilla and mandible were referred to us.

Presentation

The common presentation in our patients was either swelling (15 patients), pain and infec-

¹Associate Professor of Oral and Maxillofacial Surgery, Trauma Research Center Faculty, Baqiyatallah Medical Sciences University, and Attending Surgeon, Department of OMS, Azad University of Medical Sciences, Tehran, Iran;
²Assistant Professor of Oral and Maxillofacial Surgery, Attending Surgeon, Department of Oral and Maxillofacial Surgery, Tabriz University of Medical Sciences, Tabriz, Iran
*Correspondence to: Dr Motamedi, Africa Expressway, Golestan St, Giti Blvd. No. 11 Tehran, 19667, IR Iran
Email: motamedical@lycos.com

Refereed Paper

doi: 10.1038/sj.bdj.4812082

Received 29.05.03; Accepted 04.02.04

© British Dental Journal 2005; 198: 203–206

Fig. 1 Gender distribution of dentigerous cysts in 40 patients

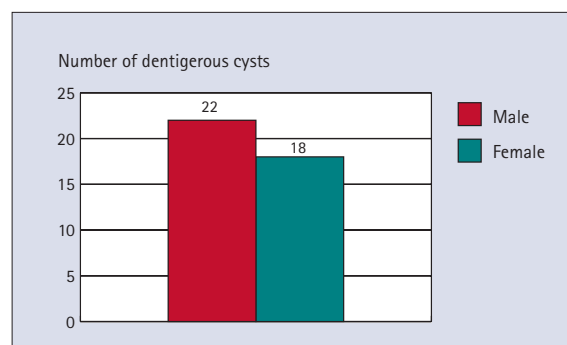


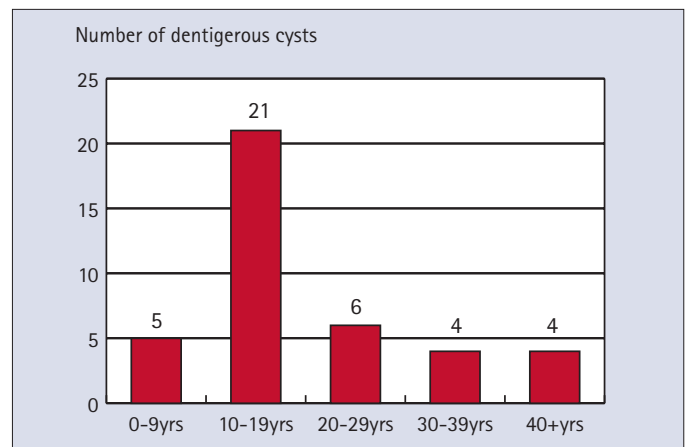
Table 1 Demographic data and treatment modalities of 40 patients with dentigerous cysts

Patient	Sex	Age (Yr)	Lesion site	Type of treatment	Teeth extraction	Follow up	Recurrence	Comments
1	F	12	21 1234	enucleation	none	3 yrs	no	exposed imp 13 + ortho
2	F	11	R← 8765	decompress	none	2 yrs	no	imp 8 all teeth erupted
3	M	10	5432	enucleation	none	4 yrs	no	imp 3 all teeth erupted
4	M	18	678→R	enucleation	8	4 yrs	no	imp 8 (multilocular)
5	M	22	5678	enucleation	8	9 yrs	no	imp 8
6	F	8	65432	enucleation	3	6 yrs	no	imp 3
7	F	20	321 1234	enucleation	3	2 yrs	no	imp 3
8	F	11	654321	enucleation	none	5 yrs	no	exposed imp 3 + ortho
9	M	18	2345	enucleation	3	11 yrs	no	imp 3
10	M	5	345	enucleation	3	9 yrs	no	imp 3
11	M	25	876	enucleation	8	8 yrs	no	imp 8
12	M	30	678	enucleation	8	7 yrs	no	imp 8
13	M	8	23456	enucleation	234	4 yrs	no	imp 234
14	M	34	6534	enucleation	5	4 yrs	no	imp 5
15	F	8	3456	enucleation	4	4 yrs	no	imp 4
16	F	40	876	enucleation	8	4 yrs	no	imp 8
17	F	47	876	enucleation	8	4 yrs	no	imp 8
18	F	12	876	enucleation	7	3 yrs	no	imp 7
19	F	12	876543	enucleation	54	3 yrs	no	imp 54
20	F	18	345678	enucleation	45	3 yrs	no	imp 45
21	M	12	543	enucleation	none	2 yrs	no	imp 3 all teeth erupted
22	M	20	345	enucleation	3	3 yrs	no	imp 3
23	F	22	876543	enucleation	3	2 yrs	no	imp 3
24	F	9	345678	enucleation	34	5 yrs	no	imp 34
25	M	18	876	enucleation	8	4 yrs	no	imp 8
26	F	16	432	enucleation	none	2 yrs	no	exposed imp 3 + ortho
27	M	28	678	enucleation	8	7 yrs	no	imp 8
28	M	18	234	enucleation	3	4 yrs	no	imp 3
29	M	18	432	enucleation	3	3 yrs	no	imp 3
30	M	11	234	enucleation	3	2 yrs	no	imp 3
31	F	17	234	enucleation	3	2 yrs	no	imp 3
32	M	12	345	enucleation	345	4 yrs	no	imp 45
33	M	14	678 →R	enucleation	8	2 yrs	no	imp 8
34	M	36	678	enucleation	7	2 yrs	no	imp 7
35	F	16	321 123	enucleation	3	3 yrs	no	imp 3
36	M	15	678	enucleation	67	3 yrs	no	imp 7 (multilocular)
37	M	35	678	enucleation	8	3 yrs	no	imp 8
38	M	18	678	enucleation	78	9 yrs	no	imp 8 (multilocular)
39	F	50	432	enucleation	3	9 yrs	no	imp 3
40	F	59	345	enucleation	4	2 yrs	no	imp 4

Note: imp = impacted, ortho = orthodontics, R = ramus

tion (1 patient), or failure of a tooth to erupt (24 patients). Radiographically, an impacted tooth with an associated radiolucency was apparent and often the cyst had caused displacement or impaction of several adjacent teeth. Unilocular radiolucencies were present in 37 patients (92.5%). Multilocular radiolucencies were seen in 3 patients (7.5%). Cortical expansion was often present. More than half of the cases were found in the 10 to 19-year age group. The majority of cases involved the anterior and body portions in both jaws. Likewise, impacted canines were involved more than impacted third molars. All were treated surgically (Table 1). The gender and age-group distributions are shown in Figures 1 and 2. There were 22 males (55%) and 18 females (45%) aged 5 to 59 years with

Fig. 2 Age group distribution of dentigerous cysts in 40 patients (avg. 20.3 yrs)



an average age of 20.3 years. There were 23 mandibular lesions (57.5%) and 17 maxillary lesions (42.5%). Fifteen cases (37.5%) were in the mandibular angle-ramus region and eight (20%) in the body and symphysis area of the mandible. There were 13 cases in the anterior maxilla (32.5%) and four in the posterior maxilla (10%). Twelve (30%) were associated with impacted third molars while 18 (45%) were associated with impacted canines and 10 (25%) with other teeth (Fig. 3). Thirty-seven (92.5%) were unicystic while three (7.5%) were multilocular (radiographically and intraoperatively).

Diagnosis

Aspiration with a 16 or 18 gauge needle was first done in all cases because these large lesions may well have been tumours and not cysts. These cysts reveal various amounts of fluid on aspiration. Next, an incisional biopsy prior to definitive treatment was carried out to differentiate the type of cyst because other cysts such as a keratocyst or cystic ameloblastoma may have similar presentations but are more aggressive and necessitate more extensive treatment and the sacrificing of vital structures, bone, and teeth.^{7,8}

Management

Cyst size and site, patient age, the dentition involved, and involvement of vital structures, were criteria which were considered and used to dictate the treatment modality indicated in each case.

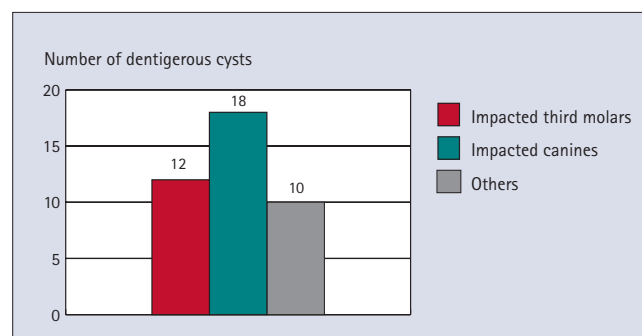
Cyst enucleation and extraction of the impaction. Cyst enucleation and extraction of the impaction was indicated in 34 of the 40 patients (Table 1). In these patients undergoing enucleation, the impacted tooth was deemed useless or lacked space for eruption and was thus extracted.

Cyst enucleation and preservation of the impaction. Surgical cyst removal without extracting the impaction was indicated and used in six patients; five young patients (10-16 years of age) were treated by enucleation of the cyst while preserving the impacted strategic maxillary or mandibular canine tooth. One case was treated by decompression.

Decompression. Decompression of the cyst with maintenance of surgical access was carried out in an 11-year-old female with an extensive cyst of the mandibular body and angle that impinged on the alveolar nerve and tooth germs. The vitality of adjacent teeth would have needlessly been placed at risk if curettage was performed. Excision of the cyst was performed after shrinkage several months later without damaging these structures.

Both enucleation and decompression of dentigerous cysts allow for alleviation

Fig. 3 Association of dentigerous cysts with impactions in 40 treated patients



of cyst pressure to permit the retained teeth to erupt normally if root formation is incomplete. Otherwise teeth are aided via orthodontics (required in three of our cases). Cases were recalled at 3, 6 and 12 month intervals to check bone formation. Patients were followed from 2 to 11 years (avg. 4.3 yrs). No associated pathologies were found in our cases. Bone formation occurred in all defects within 6-12 months regardless of treatment modality and no cases required grafts. No recurrences or infections occurred during the follow-up period.

DISCUSSION

In this study, contrary to several studies,^{1,2,4} more cases (45%) in our series were associated with impacted canines rather than with impacted third molars (30%), and more often this was found in the anterior rather than the posterior regions of the jaws. It

should be borne in mind that radiographic findings are not diagnostic for dentigerous cysts because odontogenic keratocysts, unilocular ameloblastomas, and many other odontogenic and non-odontogenic tumours have radiographic features essentially identical to those of a dentigerous cyst. These are ruled out after negative biopsy and histologic examination.^{2,4} Thus, in large dentigerous cysts an incisional biopsy from an accessible site is done to rule out other lesions which mandate separate, more aggressive, treatment protocols.

Microscopic examination

Microscopic examination of dentigerous cysts reveals a thin, nondistinctive, nonkeratinised, fluid filled, epithelium lined, sac.² The epithelial lining consists of two to four layers of cuboidal epithelial cells, and the epithelium-connective tissue interface is flat.¹⁻⁴ It is possible for the

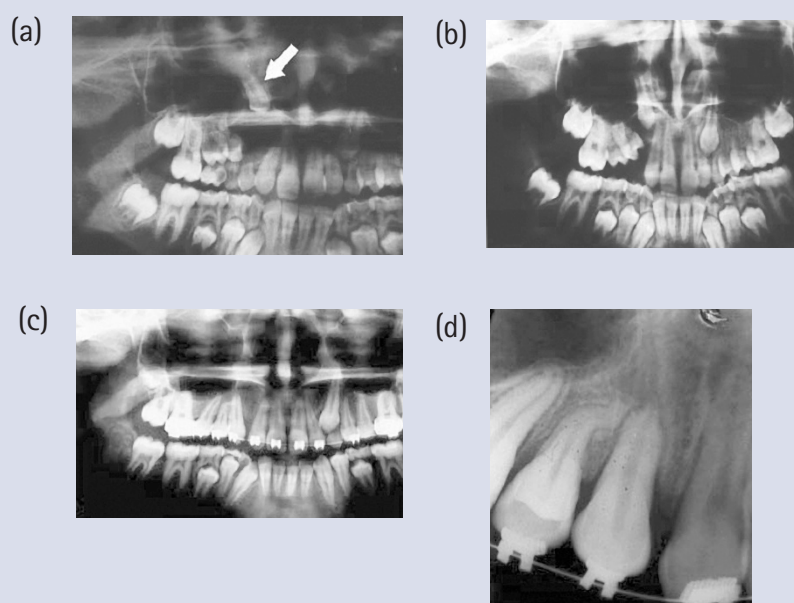


Fig. 4 a) Orthopantomogram of an impacted canine displaced to the floor of the orbit by a large dentigerous cyst of the maxilla extending from the left central incisor to the right first molar tooth encroaching on the sinus. b) The tooth was exposed and the cyst was excised while preserving the tooth. One year after surgery the tooth has started to erupt and the adjacent malposed teeth have begun to align. c) The tooth has been brought into occlusion after surgical exposure, forced eruption, and orthodontic guidance, adjacent teeth have also aligned. d) Periapical radiograph reveals solid bone formation and pneumatization of the maxillary sinus (2 years post-operative)

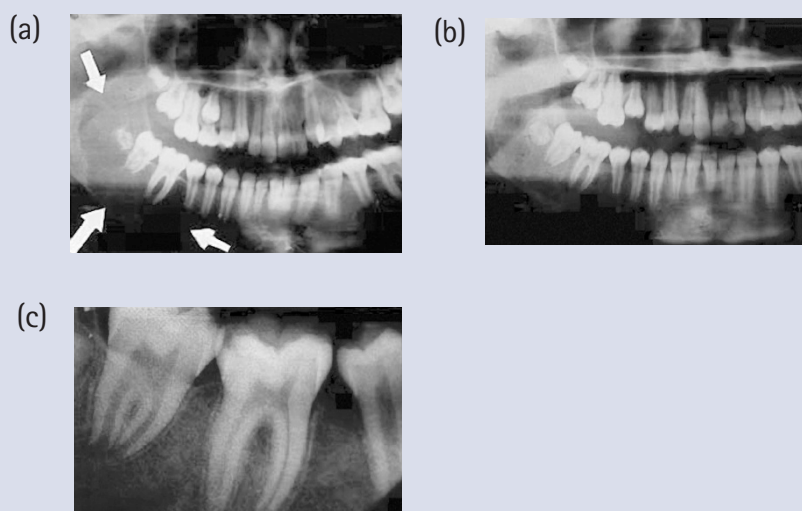


Fig. 5 a) Orthopantomogram of an extensive multilocular appearing dentigerous cyst associated with an impacted mandibular third molar in a 11-year-old extending from the first premolar to the midramus. In such a case surgical removal will endanger the vitality of the posterior teeth thus, decompression was indicated. b) Postoperative orthopantomogram c) Periapical radiograph, note reformation of the lamina dura and bone (6 months post-operative)

lining of a dentigerous cyst to undergo neoplastic transformation to an ameloblastoma and this has been reported.¹⁻⁴ Squamous cell carcinoma may also arise in the lining of a dentigerous cyst.² The frequency of such neoplastic transformation is very low.

Surgery

Surgery is commonly recommended for dentigerous cysts because they often block eruption of teeth, become large, displace teeth, destroy bone, encroach on vital structures (ie encompass or displace the alveolar nerve, shrink the maxillary sinus) and occasionally even lead to pathologic fracture.¹⁻⁴ This treatment has however, classically consisted of cyst enucleation and extraction of the tooth or teeth embedded in it, or impacted by it.¹⁻¹² This treatment option although favourable in cases involving a single impaction such as a useless wisdom tooth in an adult, will however in extensive cysts, lead to a loss of several teeth. When the teeth involved with the cyst are extracted (especially in children), functional, cosmetic, and psychological consequences may follow. In addition, the problems of how to replace such teeth in a growing child are also of concern. Thus, based on the fact that dentigerous cysts are benign, we feel that several factors or evaluation criteria may help dictate which treatment option is indicated:

Cyst size. Cyst size is an important factor when formulating a treatment plan. Small cysts may easily be enucleated and submitted for pathologic examination

(excisional biopsy), while preserving the strategic tooth or teeth involved.

Patient age and proximity of vital structures. Patient age and the proximity of vital structures are other factors requiring consideration. In children with extensive cysts, tooth germs may be damaged and teeth devitalised by enucleation, thus, an initial phase of decompression of the lesion to diminish the size of the osseous defect followed by surgical enucleation at a later date may be indicated.

Significance of the impacted tooth. The significance of the associated impacted tooth should also be considered prior to surgery. For instance an upper or lower canine tooth has enough merits with regard to aesthetics and occlusion to warrant its retention, thus, cyst removal with tooth preservation is indicated. The other extreme is an impacted third molar tooth which often warrants extraction with cyst enucleation.

Several recent articles mention the acceptance of cyst decompression in children with dentigerous cysts, describing case reports where the cysts were opened to the oral cavity and stents (either a rubber tube, removable devices, or gauze packing) were used to keep the opening patent to permit shrinkage of the cyst enucleated at a later date with a less extensive and safer surgical procedure.⁹⁻¹² However, reports regarding treatment of extensive dentigerous cysts via enucleation while salvaging the involved tooth or teeth, using orthodontic treatment to assist eruption and align the dentition are sparse. This was done effectively in three of our more recent cases (Figs 4 and 5).

In consideration of the fact that children have a much greater and quicker capacity to regenerate bone than do adults, and that teeth with open apices have a great eruptive potential, large dentigerous cysts in children should be treated differently from those in adults, with regard to bone formation, and the lesser reported potential for associated pathologic lesions within these cysts, indicating that conservative treatment with tooth preservation may be considered in this age group.

With regard to the surgical flap, common mucoperiosteal or osteoplastic flaps were used to access the lesions. If the residual buccal cortical bone is expanded and thin due to cyst enlargement, it may be incorporated into the flap by fracturing it outward as an osteoperiosteal flap thus preserving cortical bone. This may further aid in bone formation when enucleation of large cysts is planned.^{1,13} We used this flap in five patients. However, the benefits of this flap with regard to bone formation and healing remain to be documented. In our series, all treatment modalities were curative and bone formation was complete regardless of the flap used.

The authors would like to thank Drs Jabari and Seifi for the orthodontic management of the patients.

- Assael LA. Surgical management of odontogenic cysts and tumors. In Peterson LJ, Indresano TA, Marciani R D, Roser S M. *Principles of Oral and Maxillofacial Surgery*. Philadelphia: JB Lippincott, 1992, Vol 2, pp685-688.
- Neville B W. Odontogenic cysts and tumors. In Neville B W, Damm D D, Allen C M, Bouquot J E. *Oral and Maxillofacial Pathology*. Philadelphia: WB Saunders, 1995, pp493-496.
- Regezi J A. Cyst and cystlike lesions. In Regezi J A, Sciubba J, Pogrel M A. *Atlas of Oral and Maxillofacial Pathology*. Philadelphia: WB Saunders, 2000, pp88.
- Martínez-Pérez D, Varela-Morales M. Conservative treatment of dentigerous cysts in children: report of four cases. *J Oral Maxillofac Surg* 2001; **59**: 331-334.
- Dammer R, Niederellmann H, Dammer P, et al. Conservative or radical treatment of keratocysts: A retrospective view. *Br J Oral Maxillofac Surg* 1997; **35**: 46.
- Aguiló L, Gandía J L. Dentigerous cyst of mandibular second premolar in a five-year-old girl, related to a non vital primary molar removed one year earlier: A case report. *J Clin Pediatr Dent* 1998; **22**: 155.
- Motamedi M H K, Khodayari A. Cystic ameloblastomas of the mandible. *Med J Islamic Rep Iran* 1992; **6**: 75-79.
- Motamedi M H K: Periapical ameloblastoma: a case report. *Br Dent J* 2002; **193**: 443-447.
- Sain D R, Hollis W A, Togrye A R. Correction of a superiorly displaced canine due to a large dentigerous cyst. *Am J Dentofac Orthop* 1992; **102**: 270.
- Clauser C, Zuccati G, Barone R et al. Simplified surgical orthodontic treatment of a dentigerous cyst. *J Clin Orthod* 1994; **28**: 103.
- Ziccardi V B, Eggleston T I, Schneider R E. Using a fenestration technique to treat a large dentigerous cyst. *J Am Dent Assoc* 1997; **128**: 201.
- Takagi S, Koyama S. Guided eruption of an impacted second premolar associated with a dentigerous cyst in the maxillary sinus of a 6 year-old child. *J Oral Maxillofac Surg* 1998; **56**: 237.
- Motamedi M H K. Application of the osteoplastic flap in oral and maxillofacial surgery. *J Oral Med Oral Surg Oral Pathol* 1999; **87**: 647-648.