

# Vertical-split fracture of mandibular condyle and its sequelae

J. F. Hackett,<sup>1</sup> and D. J. Sleeman,<sup>2</sup>

**A case of vertical-split fracture of the right mandibular condyle and its sequelae is presented. The patient was a 16-year-old female being assessed for orthodontic treatment. Orthopantomograph and plain joint view radiographs showed a remodelled condyle which had suffered trauma 10 years previously. This type of fracture is unusual in nature but has not led to any secondary lack of growth, restriction of movement or facial asymmetry.**

A 16-year-old female attended for initial consultation. The medical questionnaire revealed no medical problems or medication. On examination, her dental and oral health were excellent. She was interested in undergoing orthodontic treatment and a panoramic radiograph (OPG) was taken as a preliminary investigation. This revealed an irregular head of the right mandibular condyle ( Figs 1, 2 ).

The consultant radiologist's report stated that this was a 'partially healed intracapsular vertical-split fracture of the head of the right mandibular condyle.'

On questioning, the patient's mother volunteered that she had fallen from her bicycle at 6 years of age. She had injured her chin and was taken to the Accident and Emergency unit of the local hospital where sutures were inserted. However, the following day the right side of her face became very swollen and painful. She was unable to open her mouth and she was referred to a maxillofacial unit and admitted for observation and radiographic examination.

The latter diagnosed a fracture of the right condylar head and the surgeon felt that because she was able to achieve a normal dental occlusion that surgical intervention was not necessary. The symptoms and signs abated over the following week.

She was discharged from the hospital with minimal swelling and a good range of mandibular movement.

During the 10 years since the trauma her facial growth has been normal and she has not experienced any dysfunction-type sequelae. In view of the fact that she was about to begin orthodontic treatment a specialist maxillofacial and orthodontic opinion was sought on the possible effects of such treatment on the pre-existing injury. The consensus was that orthodontic therapy should not affect the stability of the condyle and joint.

The orthodontic treatment was completed successfully without any complications.

## Comment

The incidence of facial fractures in the paediatric population is 1.4–15% of all maxillofacial trauma. Forty-one per cent of facial fractures involve the mandible. The condyle is affected in 20–30% of these mandibular fractures.<sup>1–2</sup>

Conventional radiographs are accurate enough to diagnose condylar fractures. However, one prospective study in Germany involving 182 patients with 249 fractures of the mandibular condyles underwent conventional and computed tomography scans as diagnostic procedures. It was found that all clinically identified fractures were detected by means of both conventional and computed tomography imaging. However, only computed tomography scanning could correctly classify high condylar neck fractures.<sup>3</sup>

Management of condylar fractures is either surgical or non-surgical. An Austrian study comparing surgical and non-surgical treatment found no significant difference in mobility, joint problems, occlusion, muscle pain or nerve disorders between the two. The only significant difference was in subjective discomfort. Surgically treated patients reported more 'weather sensitivity' and pain on maximum opening.<sup>4</sup> In another study, 25 patients were followed over a period of 15 years having been treated by instruction, exercises and observation. It concluded that non-surgical treatment of condylar fractures in children was still the method of choice.<sup>5</sup>

This particular case is unusual in that the trauma caused an intracapsular vertical split fracture of the condyle head. Interestingly a retrospective study of paediatric condylar fractures in Finland found that intracapsular fractures were more common in 6-year-olds and under than any other type of condylar fracture.<sup>6</sup>

In the literature condylar fractures are frequently associated with long-term sequelae eg pain, restricted mandibular

## In brief

- The use of panoramic radiography is becoming increasingly common in general dental practice. This report reminds the practitioner to assess all aspects of the radiograph including joints
- In this patient's case there was no long-term morbidity. However there is a significantly increased risk of the development of premature osteoarthritis in the presence of post-traumatic articular surface changes
- Orthodontic tooth movement may precipitate dysfunctional symptoms (facial arthromyalgia + or – internal temporomandibular joint dysfunction) in a previously normal individual. This is more likely in a masticatory mechanism which has compensated following injury

<sup>1</sup>General Dental Practitioner, Waterford, Ireland,

<sup>2</sup>Professor of Maxillofacial Surgery, University College, Cork, Ireland

\*Correspondence to: J. F. Hackett, St. Catherine's Hall, Catherine Street, Waterford, Ireland

REFEREED PAPER

Received 16.02.01; Accepted 22.05.01

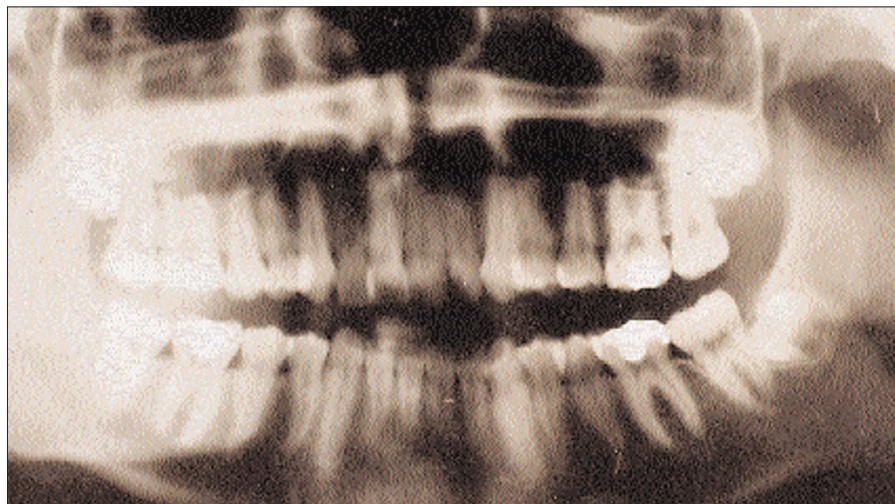
© British Dental Journal 2001; 191: 557–558

movement, muscle spasm and facial asymmetry.<sup>7-9</sup>

Follow-up is therefore extremely important but can be difficult because of poor attendance.<sup>10</sup>

Ten years post-trauma the patient in this report has had no symptoms or signs of dysfunction but we will continue to monitor the situation. This case is important for two reasons. Firstly, it is important to scrutinise all aspects of panoramic radiographs carefully because the condyles are usually visible, although in outline only.

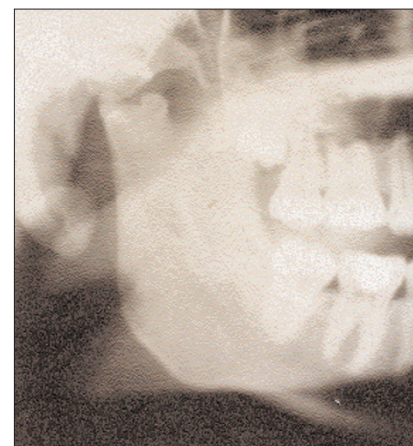Secondly, despite significant structural damage to a vital component of the articulatory system this young patient is functionally and aesthetically normal.



**Fig. 1 Orthopantomograph (OPG) revealing irregular head of the right mandibular condyle**

- 1 Demianczuk A N, Verchere C, Phillips J H. Effect on facial growth of paediatric mandibular fractures. *J Craniofacial Surg* 1999; **10**: 323-328.
- 2 Cascone P, Sassano P, Spallacia F, Rivaroli A, Di Paolo C. Condylar fractures during growth: follow-up of 16 patients. *J Craniofacial Surg* 1999; **10**: 87-92.
- 3 Schimming R, Eckelt U, Kittner T. Value of coronal computed tomograms in fractures of the mandibular condylar process. *Oral Surg, Oral Med, Oral Path, Oral Radiol Endod* 1999; **87**: 632-639.
- 4 Santler G, Karcher H, Ruda C, Kole E. Fractures of the condylar process: surgical versus non-surgical treatments *J Oral Maxillofac Surg* 1999; **57**: 392-397.
- 5 Hovinga J, Boering G, Stegenga B. Long term results of non-surgical management

- of condylar fractures in children. *Int J Oral Maxillofac Surg* 1999; **28**: 429-440.
- 6 Thoren H, Lizuka T, Hallikainen D, Nurminen M, Lindqvist C. Epidemiological study of patterns of condylar fractures in children. *Br J Oral Maxillofac Surg* 1997; **35**: 306-311.
- 7 Schellhas K P, Wilkes C H. Facial pain, headache, temporomandibular joint inflammation *Headache J* 1989; **29**: 4.
- 8 Avrahami E, Rabin A, Mejdani M. Unilateral medial dislocation of the temporomandibular joint. *Neuroradiology* 1997; **39**: 602-604.
- 9 Schellhas K P, Pollei S R, Wilkew E C H. Paediatric internal derangements of the temporomandibular joint. Effect on facial development. *Am J Orthod Dentofac Orthopaedics* 1993; **104**: 51-59.
- 10 Mitchell D A. A multicentre audit of unilateral fractures of mandibular condyle. *Br J Oral Maxillofac Surg* 1997; **35**: 230-236.



**Fig. 2 Right mandibular condyle and ramus**