

4

Good occlusal practice in advanced restorative dentistry

S. J. Davies,¹ R. M. J. Gray,² and S. A. Whitehead,³

In this part, we will discuss:

- The re-organised approach
- When and how to re-organise an occlusion in restorative dentistry

In most patients the existing occlusal scheme will be functional, comfortable and cosmetic; and so if a tooth or teeth need to be restored, the most appropriate way to provide the restoration(s) would be to adopt a 'conformative' approach: that is to provide treatment within the existing envelope of static and dynamic occlusal relationships. There will, however, be situations where the conformative approach cannot be adopted, and this section aims to describe what is 'Good Occlusal Practice' in these circumstances.

The 'conformative approach' is not always possible or appropriate for 'small cases'

The 're-organised approach' is not always needed or appropriate for 'large cases'

The term 'the re-organised approach' conjures up ideas of full mouth crown and bridgework even at a differing occlusal vertical dimension. This may be the case for rare situations, but it is not only the 'major' cases that need the extra thought and processes that comprise the re-organised approach. Equally it is often the case that with some care in planning the treatment sequence, apparently complex cases can still be completed within the conformative approach. This will be illustrated in addition to a description of how to 're-organise' an occlusion.

Question: When is the Conformative Approach not appropriate?

1. When it is not possible

This appears to be self evident. However, it is easy to fall into the trap of intending to restore the teeth to the pre-existing occlusion, but to then set about destroying the occlusal surfaces of so many teeth as to make it impossible to return to the pre-existing occlusion when trying to record the inter-arch relationship (bite) later in the treatment sequence.

Changing the occlusion may not be inevitable, even in complex cases

It may be necessary to modify the treatment plan, always leaving sufficient reference points to ensure that as the new restorations are provided they create an occlusion which conforms. For example, preparing alternative teeth at different visits may overcome the problem even in a quadrant in which all the teeth need to be restored. Alternatively, it may be possible to prepare all the teeth at the one visit but safeguard the situation by recording

an intermediate registration after the preparation of only some of the teeth. This intermediate registration then becomes the reference point once the remaining teeth have been prepared (Figs 1 a,b,c).

These approaches are simply examples of following the EDEC principle and may avoid the complication and danger of changing the occlusion, when initially it seemed inevitable.

Question: When is the Conformative Approach not appropriate?

2. When it is not wanted

It may be that the treatment objectives, of the dentist and patient, exclude the 'conformative approach'. Examples would be:

- An increase in vertical height is wanted or indicated
- A tooth or teeth is/are significantly out of position (ie overerupted, tilted or rotated)
- A significant change in appearance is wanted
- There is a history of occlusally related failure or fracture of existing restorations
- Recurrence of a temporomandibular disorder that has relapsed after a period of successful splint therapy.

The vast majority of TMD patients do not need anything other than a period of appropriate splint therapy to provide long-term resolution of their TMD symptoms.¹ There is, therefore, no universal justification for the so called 'second phase of treatment' of TMD involving unnecessary restorations. There will be, on rare occasions however, some patients who maybe need some permanent alteration of their teeth to prevent the reoccurrence of their TMD, and other patients who not only have a

¹GDP, 73 Buxton Rd, High Lane, Stockport SK6 8DR; P/T Lecturer in Dental Practice, University Dental Hospital of Manchester, Higher Cambridge Street, Manchester M15 6FH
²Honorary Fellow, University Dental Hospital of Manchester, Higher Cambridge Street, Manchester M15 6FH
³Consultant in Restorative Dentistry, Eden Valley Primary Care Trust, Central Clinic, 50 Victoria Place, Carlisle CA1 1HP

*Correspondence to: Stephen Davies
email: stephen.j.davies@man.ac.uk

REFEREED PAPER
© British Dental Journal
2001; 191: 421-434

The EDEC principle when restoring complex cases to the conformative approach

E = Examine the pre-existing occlusion

D = Design an operative procedure which allows the conformative approach

E = Execute that plan

C = Check that each stage of the restoration conforms to the occlusion of the previous stage

The reference points of the pre-existing occlusion may be lost with the first sweeps of the air rotor



Fig. 1a Pre-operative view before proposed crown preparation of LL4,5,6,7 (34,35,36,37)

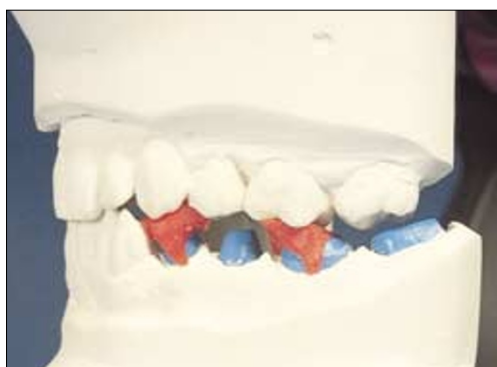

Fig. 1c All teeth are now prepared, but bites against LL4 and 6 ensure models are mounted to pre-operative registration (conformative approach)

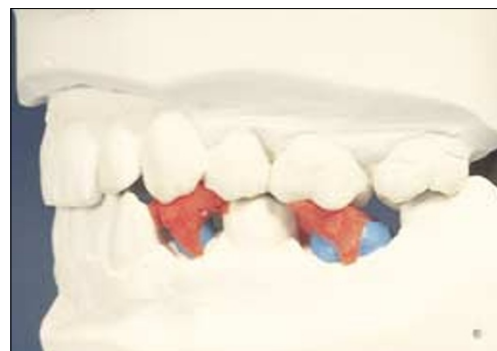

Fig. 1b LL4 (34), LL6 (36) are prepared and Duralay 'bites' taken on these teeth using occlusal contacts on LL5 (35) and LL7 (37) to ensure the 'conformative approach'

primary need for restoration of their teeth but also who have a TMD. These patient, in the authors' opinion, require the closest adherence to the principles of the re-organised approach.

When the Conformative Approach cannot be adopted, there are only two possibilities:

First possibility

Plan to provide new restorations to a different occlusion which is defined *before* the work is started: ie 'to visualise the end before starting': this is *the re-organised approach*.

Second possibility

Change the occlusion, without having planned the new occlusion and the related jaw relationship. To provide an occlusion which does not conform with the previously well tolerated one. This is an occlusion that has been arrived at by accident: ie *the unorganised approach*.

What is the treatment objective of a re-organised occlusion?

At its very simplest, it is to provide restorations, which although changing the occlusion, will be

well tolerated by the patient at every level. No occlusion can be said to be 'intrinsically bad'; an occlusion may only be judged by the patient's reaction to it.

An adverse or poorly tolerated reaction may include the following:

- A temporomandibular disorder
- Occlusal trauma to the periodontal tissues, leading to increased mobility
- Fracture of restorations or of the teeth
- Excessive tooth surface loss
- Hypersensitivity.

Singularly or collectively these represent a most unhappy outcome to dental treatment. The vast majority of dentists who have been actively involved in the provision of extensive restorative treatment plans have some experience of the distress that any or all of these sequelae produces.

For every dentist actively involved in the provision of advanced restorative treatments there is always the danger that a patient will react adversely to our treatment, but we believe that this strategy makes it much less likely. This is because the principle of providing an occlusion to the re-organised approach is to provide an occlusion that is ideal to the patient, *at every level*.

Definition of an 'ideal occlusion', at every level

The definition of 'ideal occlusion' needs to be given at the tooth level, at the system level and at the patient level.

The tooth level

An ideal occlusion will provide:

- Multiple simultaneous contacts
- No cuspal incline contacts
- Occlusal contacts that are in line with the long axis of the tooth
- Smooth and, wherever possible, shallow guidance contacts.

The articulatory system level
An ideal occlusion will provide:

- Centric Occlusion occurring in Centric Relation
- Freedom in Centric Occlusion
- No posterior interferences (anterior guidance at the front of the mouth).

The patient level

An ideal occlusion will be within the neuromuscular tolerances of that patient at that time in their life. It is only by careful adhesion to the characteristics of an ideal occlusion at the tooth and system levels that one can do more than just 'hope' that a new occlusion falls within the neuromuscular tolerances of the patient.

How to re-organise an occlusion so that it is 'ideal'

Essentially the only difference between the conformative and the re-organised approach is that the re-organised approach is the conformative approach with the extra stages of designing and executing a new occlusion before providing the definitive or 'final' restorations

As soon as these stages have been completed, the emphasis is to ensure that the definitive restorations conform to the design that was planned and executed in the provisional restorations.²

The re-organised approach is, therefore, the provision of a more appropriate occlusal scheme prior to delivering the final restoration. It is impossible to confidently proceed directly to final changes in the occlusal scheme and for the most part some form of 'mock up' is employed, usually in the form of a diagnostic wax-up. How to plan and manage the change in occlusal relationships is the challenge. Once the changes are made then the definitive restorations become 'conformative' in approach: that is, conforming to a new occlusal scheme.

It is impossible to make comprehensive *rules* for the management of every clinical situation. However, the following *guidelines* for planning the re-organisation of the occlusion provide a broadly applicable protocol.

Technique

The examination phase
(E = Examine the existing occlusion)

Recording jaw relationships.

The first essential part of the examination is to determine whether the patient's existing centric occlusion occurs in centric relation; if it does not, and assuming that the decision to re-organise the occlusion has been taken, centric relation must be found. The reader will note that the EDEC sequence differs from that in the conformative approach not only in the examination

but also in the execution phase. This is to estimate whether the new (centric) occlusion can be made to this ideal jaw relationship. It is optimal if it can. The difficulty in recording jaw relationships has already been discussed. The use of articulators becomes more critical if any degree of reproducibility is to be achieved in restorative cases where there are major changes to occlusal relationships. The accurate assessment of centric relation may be made more difficult by the length of time that patients have been functioning with their less than ideal occlusion incorporating habitual closure patterns and the guarding of potentially uncomfortable deflective contacts. It is often, therefore, necessary to 'de-programme' the musculature for some period of time before recording centric relation.

Bimanual manipulation of the jaw into a reproducible position can be difficult and some form of appliance may be necessary. At the chairside, an anterior bite plane ('Lucia jig') may be constructed in acrylic resin. This may be worn by the patient for some time in the chair to 'de-programme' the musculature prior to manipulation. Even, this may be ineffective and a stabilisation splint may have to be employed.³ This is a hard splint made to cover whichever dentition has the most missing teeth and aims to be a facsimile of an ideal occlusion (CO=CR and anterior guidance at the front). It is interesting to consider that the use of splints may comprise part of the examination phase of the re-organised approach, rather than being reserved solely for treatment of a TMD.

The static occlusion is also examined on a tooth level to discover the existence of any incline contacts between the cusps of opposing teeth.

The dynamic occlusion needs to be examined with a view to discovering any posterior interferences on the working (WS) or non-working sides (NWS). In addition an estimate of the condylar angles should be made. This can either be done on a semi-adjustable articulator by the use of latero-protrusive wax records or by simply adjusting the condylar angles of the articulator until the space (or lack of it) between the molars on the NWS is the same as it is in the patient. This can only be done if a face bow record has been used to mount the upper models into the articulator.

The planning phase
(D = design the new occlusion)

It is advisable to accurately duplicate the stone models at the correct centric relation and occlusion on the articulator. A *mock equilibration* can then be carried out on one set, whilst not sacrificing the hard earned accurate record which represents the patient's existing occlusion on the other set (ie the starting point of the treatment). This mock equilibration, involving many small occlusal adjustments, is carried out on the stone models until multiple and ideal contacts

'Organise': to give a definite and orderly structure, and to arrange and 'get up' something
OED

'Unorganised': not formed into an orderly whole
OED

The examination phase of the process is completed when the clinician has a set of articulated models that are an accurate representation of the patient's occlusion and jaw relationship



Fig. 2 The flag is attached to the articulator and the incisal pin is set before the upper model is removed



Fig. 3 An arc is drawn on the flag at a set radius using the tip of the lower canine as its centre (Canine Arc)

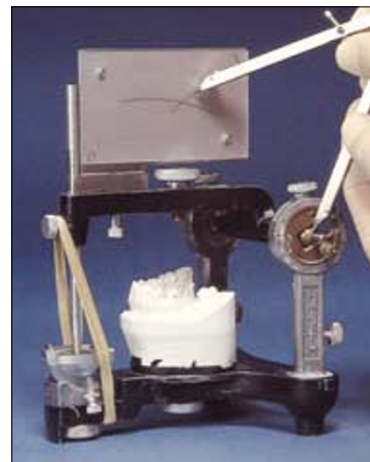

Fig. 4 The canine arc is bisected by an arc using the articulator hinge as its centre. This intersection is the centre of a possible occlusal plane (sphere)

Fig. 5a Proposed occlusal plane obviously still touches the tip of the lower canine



Fig. 5b Relationship of proposed occlusal plane to the mesial abutment and to pontic of the planned bridge



Fig. 5c Relationship of proposed occlusal plane to the distal abutment of the planned bridge



between opposing teeth occur in centric relation. The sequence of these adjustments on the models is recorded as an aid for subsequent clinical equilibration carried out in the mouth.⁴

If the adjustments of the stone teeth exceed that which the clinician judges to be possible or prudent for the real teeth, then an important conclusion will have been reached: that it will not be possible to achieve an ideal occlusion without major alteration to those teeth. This may indicate a need for considering any of the following:

- Provisional restorations of some type
- Orthodontic adjustment
- or even ... extraction.

The next stage in the design of the new occlusion is a *diagnostic wax up*. In this process the correctly mounted and now equilibrated casts are modified by the application of wax as a mock-up of the final restorations or prostheses. It is best if this is carried out by the clinician; but if it is carried out by the technician, the final responsibility of design still rests with the clinician. It is, therefore, of paramount importance that the technician providing the wax up understands that there are limitations to the provision of restorations because it is possible to 'cheat' in the laboratory but not in the mouth. The diagnostic wax up gives positive information on the occlusal scheme that can be generated. It is a valuable guide to the treatment objective for both the clinician and the technician and it should be agreed by both parties before the patient's teeth are touched. The concept of the 'ideal occlusion' should be incorporated wherever possible. The diagnostic wax up can also reveal information regarding the need for crown lengthening and orthodontic tooth movement, in addition to being a wonderful guide to the optimum crown preparation form. A diagnostic wax up will provide the template for the temporary restorations. Finally it gives the patient an opportunity to visualise the

treatment and enhance their ability to make informed choices.

The greatest difficulty in designing the occlusion in a diagnostic wax up is to create the occlusal planes. This can be assisted by the use of a 'flag' on the articulator. By the use of this device a approximation of the centre of the curves of Wilson and Spey can be made.

How to use a flag to determine the planes of occlusion in a diagnostic wax up

Step 1. Mount the models on a semi-adjustable articulator, after taking a facebow record and set the incisal pin to record the vertical height, with the models in occlusion. Now remove the upper model and attach the 'flag'. (Fig. 2)

Step 2. Draw an arc on the flag at a set radius from the tip of the lower canine, assuming that the canine is not due to be restored to an increased height. If it is, then a new cuspal tip is waxed up first, and that is used. This is the first stage of trying to find the centre of the sphere which incorporates the ideal occlusal planes. This technique is based upon the long held concept that the occluding surfaces of the upper and lower teeth move relative to each other as if over the surfaces of a sphere with a radius of about four inches, and that the height of the lower canine is the least likely to be changed (Fig. 3)

Step 3. A point along this arc (canine arc) is now found which will be the centre which determines both the antero-posterior occlusal plane (Spey) and the lateral plane (Wilson). As a starting point for establishing the centre of these occlusal planes, the canine arc is firstly bisected by an arc that uses the hinge (TMJ) of the articulator as its centre, using the same radius (Fig. 4).

Step 4. The antero-posterior occlusal plane provided by this centre is tested by reversing the

dividers so the point is placed onto the bisection of the arcs and the graphite end is used to draw onto the lower teeth (Fig. 5 a-c). In this way a harmonious occlusal plane of the proposed restoration can be developed by examining the effect that it would have on the existing lower teeth. At this stage the upper model can be replaced for a similar test, or this examination can be left until the waxing up stage of the treatment planning. The centre of the occlusal planes that is determined by this process is not 'cast in stone', it can be and often must be moved forwards or backwards along the 'canine arc' until an occlusal plane is found that, whilst still an arc, is compatible with the position of the existing teeth. A plane from a centre too far forward will be too traumatic to the opposing teeth (Fig. 6a), whereas if the centre of the occlusal plane was too far back along the 'canine arc' the preparation of the distal abutment would be too radical (Fig. 6b).

Summary

It is emphasised that this technique is suggested as an aid to diagnostic waxing; it is not prescriptive. It does not suggest that occlusions should be restored to a sphere that has a radius of four inches! This would clearly be ridiculous. This technique gives the clinician, who is planning the restoration of an occlusion, the opportunity to provide smooth and harmonious occlusal planes with a predictable effect upon the existing teeth. This information can now be used in the creation of a wax up of the definitive restorations (Steps 5 to 8).

How to do a diagnostic wax up, once the planes of occlusion have been established

Step 5. Firstly cut down the teeth on the lower model, which are destined to be restored, to about 1.5 mm below the proposed occlusal plane. Next add wax to these teeth and any gaps to be restored to a level above the proposed occlusal planes.

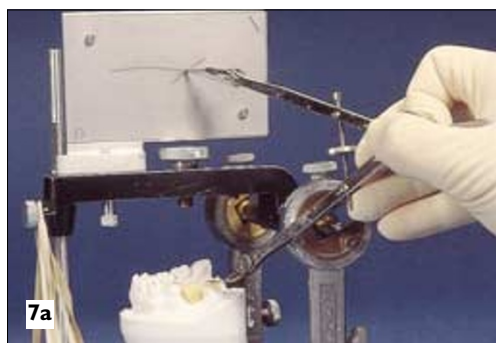Step 6. Use a knife attached to the geometric dividers to trim the wax down to this plane. This will give the position of the cuspal tips of the teeth to be restored, on both the curves of Wilson and Spey (Fig. 7a-c).



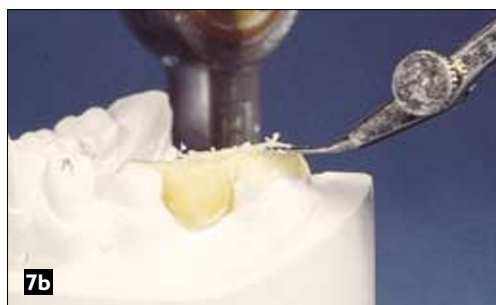Fig. 6a This occlusal plane would be impossible against the opposing molar



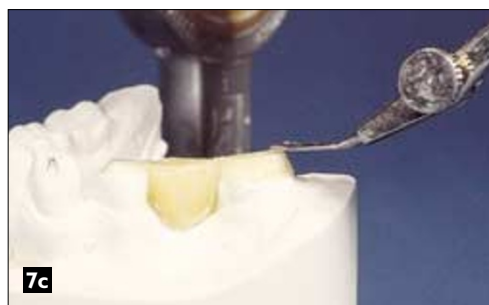Fig. 6b This occlusal plane would be too traumatic to the distal abutment of the proposed bridge



7a



7b



7c

Fig. 7 Wax carved to proposed occlusal planes

The EDEC principle in the re-organised approach

E = Examine the characteristics of the existing occlusion, including jaw relationship

D = Design and plan the new occlusion

E = Execute the new occlusal prescription prior to definitive restorations

C = Check that you are conforming to this new occlusion in the definitive restorations

**Is equilibrium possible?
Practice on plaster before making irreversible changes in the mouth**

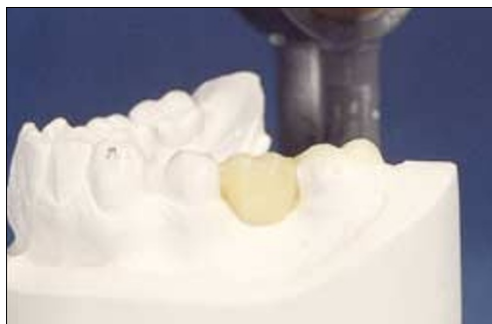

Fig. 8 Morphology is carved into the wax, to represent the final abutments and pontic of the proposed bridge to a planned occlusion



Fig. 9 Minor occlusal adjustment is necessary to the teeth opposing the abutment teeth, whereas the crown on the overrupted tooth opposing the gap (in this case) will need to be replaced

Step 7. Carve morphology into the wax to create the waxed up teeth (Fig. 8). (How do you carve an elephant out of a block of marble? Knock off all the bits that don't look like an elephant.)

Step 8. The wax up of the lower arch is now complete and the upper model is refitted to the articulator (Fig. 9). So that the incisal pin again rests on the incisal table, adjustment will usually be needed to the opposing teeth in the upper arch, this may be minor equilibration or significant change to severely overrupted teeth.

Note: These adjustments will need to be made when the lower restoration is fitted; the patient must be advised of this at the planning stage.

Summary

A wax up of a proposed restoration is an ideal opportunity to see the end point of an occlusal change, before picking up a handpiece. The improvement in the occlusion can be developed and visualised (Figs 10a,b and 11a,b)

The pre-definitive restoration treatment phase

(E = executing the planned new occlusion and jaw relationship)

Equilibration (adjusting natural teeth)

Equilibration will already have been performed on the models in the design phase; so the end point and adjustments required to

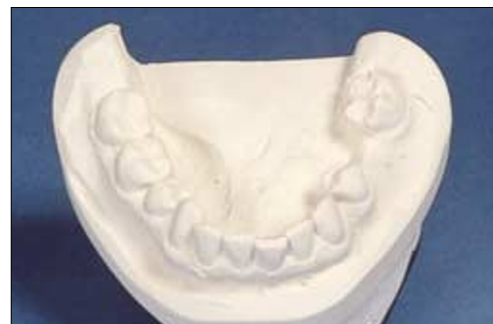

Fig. 10a Pre-operative lower model

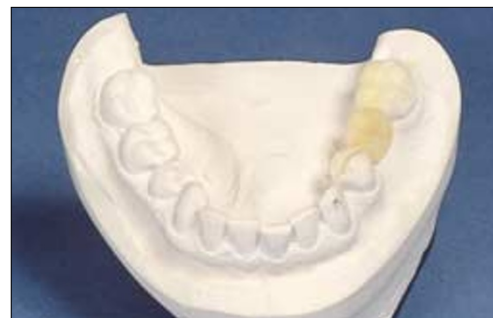

Fig. 10b Lower model after wax up to idealised occlusal planes



Fig. 11a Pre-operative lower model, illustrating lingual and mesial tilting of distal abutment of proposed bridge

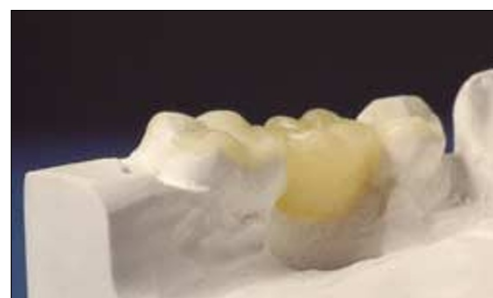


Fig. 11b Lower model after wax up illustrating improved occlusal planes

reach it will already be known. This 'mock equilibration' is highly recommended. It prevents anxiety in the mind of the clinician who when carrying out an equilibration may otherwise wonder whether he or she will be able to finish what they have started! The aim of equilibration is to effect changes in the centric occlusion to give it as far as possible the features of an ideal occlusion:

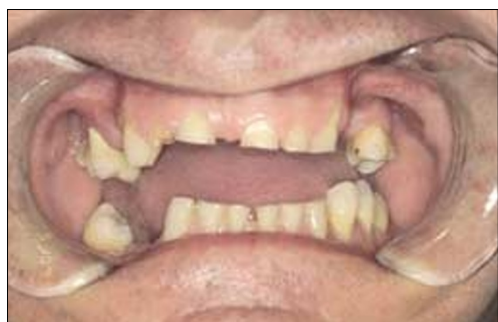

Fig. 12b Patient's dentition exhibiting significant tooth surface loss

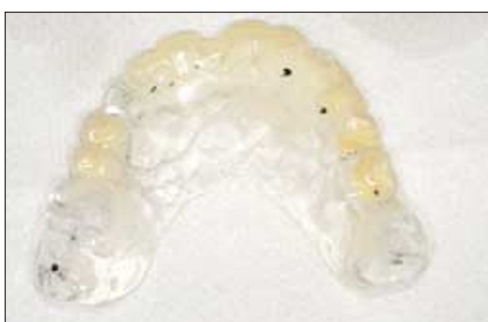

Fig. 12c Upper stabilisation splint with labial veneers to fit over unprepared upper anteriors

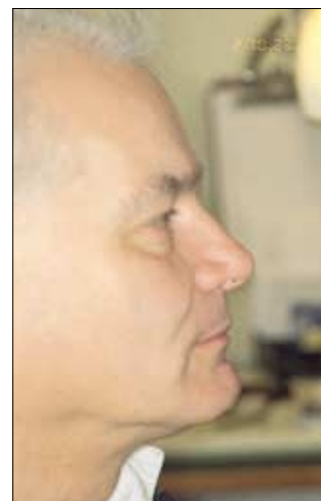

Fig. 12a Patient's profile, suggesting loss of vertical dimension

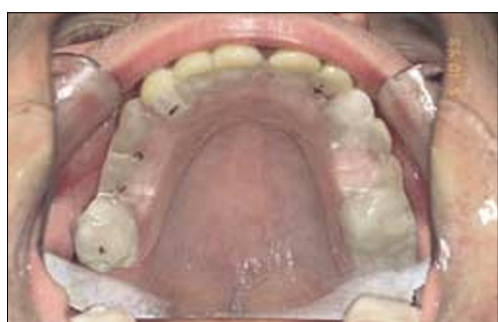

Fig. 12d Mirror view of upper stabilisation splint

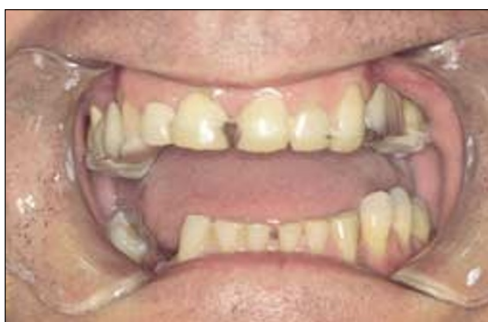

Fig. 12e Anterior view of upper stabilisation splint. Note the provision of median diastema

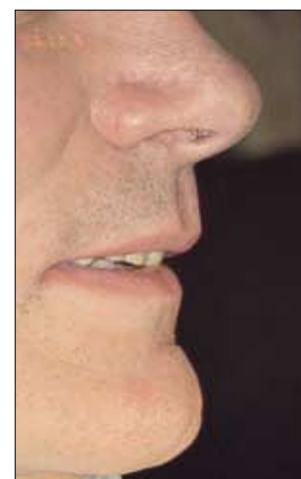

Fig. 12f Provisional restoration vertical dimension and labial support by the upper stabilisation splint. Compare with Fig. 12a

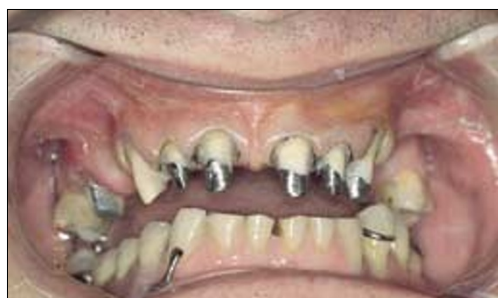

Fig. 12g Definitive lower restoration by partial denture and crown preparations of upper anterior teeth, at the prescribed vertical dimension

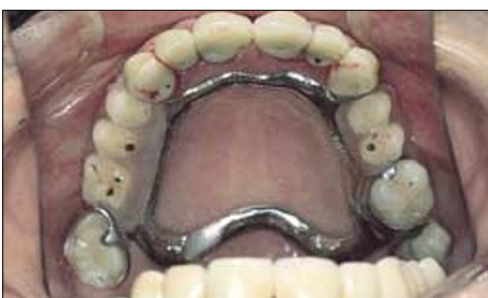

Fig. 12h Mirror view of upper definitive restoration by partial denture and anterior crowns as developed in the 'provisional' phase

- Multiple simultaneous contacts
- No cuspal incline contacts
- Occlusal contacts that are in line with the long axis of the tooth
- Smooth and, where possible, shallow guidance contacts
- Centric occlusion occurring in centric relation
- Freedom in centric occlusion
- No posterior interferences.

It may not be possible in every case to provide all of the features of an ideal occlusion. It is inevitable that dentists as restorers and replacers of teeth, sometimes change occlusions. These guidelines are listed to emphasise the point that we should plan to make the changed occlusion as

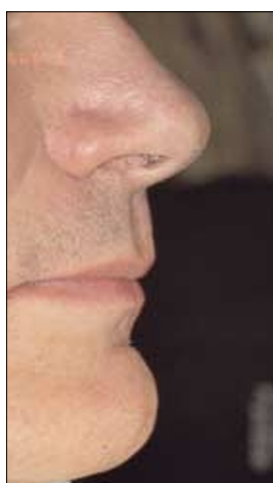

Fig. 12i Restoration of vertical dimension and labial support

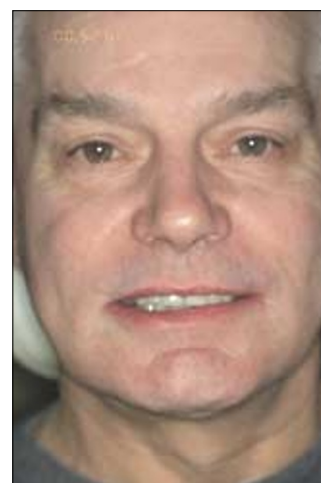

Fig. 12j The re-organised occlusion

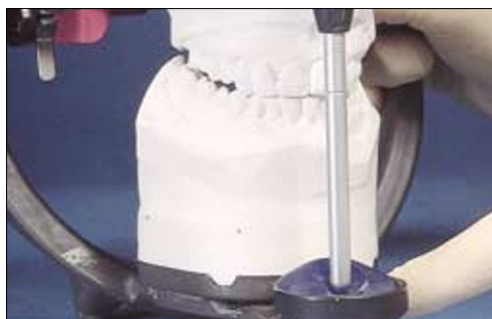

Fig. 13a The models, including provisional crowns on upper anterior teeth, are used to carve a custom incisal guidance table in a slow setting autopolymerising acrylic




Fig. 13b Custom incisal guidance table. The incisal pin of the articulator is resting in a position that is related to the centric occlusion of the models

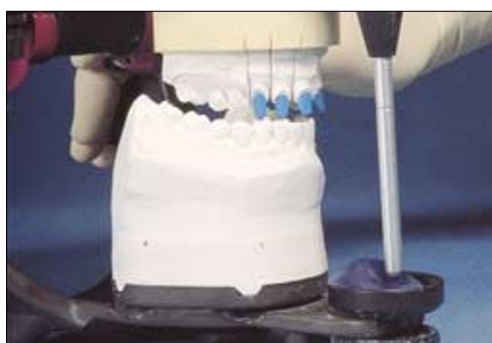

Fig. 13c Custom incisal guidance table is used to guide the upper working model into the same left lateral excursion as was present in the provisional restorations (This would be a right lateral excursion in the patient)



Fig. 13d Close up of custom incisal guidance table, guiding upper model into a left lateral excursion

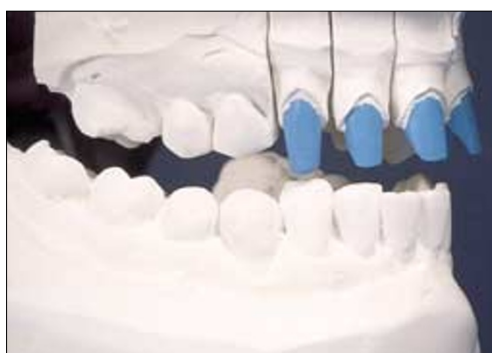

Fig. 13e Using this technique it is easy to see exactly what the crown length and palatal contour should be to provide the same canine guidance as was present in the provisionals



Fig. 13f Custom incisal guidance table determining the length of right canine definitive crown

The planning and design phase of the process is completed when the clinician has a set of articulated models and is confident that they are an accurate representation of the end point of the treatment plan

ideal as possible so reducing the risk of precipitating adverse reactions. This aim must be achieved in the pretreatment phase so that the definitive restoration can follow a conformative approach, using the occlusion that has been developed in the design and pre-treatment phases as the starting point.

Simple orthodontic treatment

Teeth may be moved in three planes to a position that is compatible with the aim of the treatment plan.⁵ Whether orthodontic movement of teeth is needed is determined at the study model stage.

Provisional restorations

Provisional restorations are always useful and sometimes essential in the management of the re-organised approach. All the information regarding the occlusal scheme of the final restorations should be programmed into the provisional restorations. Subtle changes may be required but the final restorations should conform to the provisionals. The provisions are used to 'develop' the re-organised occlusion.

Cases when the re-organisation of the occlusion includes an increase in vertical height are amongst the most difficult, and so the most essential to plan. The new occlusion

including the change in the vertical dimension must be tested (against the tolerances of the patient) by the placing of provisional restorations. A provisional removable prosthesis ie splint,⁶ may provide the ideal means of doing this, as it can be modified in the development of the treatment plan. In Fig. 12a–j, a patient with severe tooth surface loss and consequential loss of vertical dimension (Fig. 12a) has been treated initially by the provision of a removable stabilisation splint (Fig. 12c); this was not only the means of testing the tolerance of the new occlusion in three dimensions but also the vehicle to test the anterior aesthetics by means of acrylic labial veneers (Fig. 12d–f).

Once the occlusion has been prescribed in this way, it is relatively straight forward to proceed to the definitive restorations of upper and lower partial dentures and anterior crowns (Fig. 12g–j). In this case, the patient was also able to decide that he preferred not to have the central incisor diastema that had been incorporated into the provisional splint (contrast Fig. 12e and j).

Provisional restorations can be either chairside or laboratory made. Each have their own advantages. Both are adjustable and allow changes to be made until appropriate occlusal contacts and aesthetics are developed. In this context ‘appropriate’ means ‘accepted by the patient.’

The definitive treatment phase

(C =Checking that the definitive restorations conforms to the occlusion that has been designed and executed in the previous phases)

Once the provisional restorations are at the stage when the clinician and the patient are satisfied, they can be replaced by the definitive restorations now using the conformative approach.

It is unwise to proceed with the definitive restorations while the provisional restorations are giving any problems or the patient is not comfortable.

The challenge for the laboratory technician is to ‘copy’ the occlusal features that have been ‘developed’ in, and shown to be comfortable by, the provisionals. A customised incisal guidance table is a

good way of copying the guiding surfaces of the upper anterior provisional crowns in order to prescribe the same anterior guidance (Fig. 13a–f).

How to create a custom incisal bite table

A custom incisal bite table is necessary in order to be able to conform to the anterior guidance provided by the upper anterior provisional restorations.

1. Mount models of the completed pre-definitive restorations (provisionals) onto a semi-adjustable articulator, after a face bow record.
2. Lift the incisal pin clear of the incisal guide table by about 2 mm
3. Whilst some autopolymerising acrylic is setting on that table transcribe the tip of the incisal pin through it, whilst guiding the model incisors through excursive movements. (Fig. 13a) This creates a template of the movements of the articulator during lateral and protrusive movement: the custom incisal guidance table is created (Fig. 13b). As the upper models move backwards and sideways (movements which replicate mandibular protrusion and lateral excursion in the patient) the incisal pin of the articulator will move upwards and backwards from the centric occlusion position at the front and bottom of the acrylic guidance template (Fig. 13b).
4. The working model for the definitive upper crowns is now mounted in the same articulator and the custom incisal guidance table is used to guide this model through all excursive movements (Fig. 13c,d). This ‘custom’ anterior guidance table will now be used to enable the technician to make definitive upper anterior crowns that will guide the patient through the same envelope of mandibular movement as when they had the provisional restorations. It is particularly valuable in setting the ideal crown length and palatal contour of the canine restoration (Fig 13e,f).

Summary

An advanced restorative treatment plan involving the re-organisation of a patient’s occlusion

The pre-definitive restoration phase of the process is completed when the patient has an ideal (ie tolerated) occlusion in provisional restorations

The definitive restoration phase: Re-organisation complete — now conform

The need for the restorations comes first!

- **Ideal occlusion is a concept in the treatment of a patient who needs multiple restorations**
- **It is not a treatment objective in itself**
- **A patient should never be provided with multiple restorations solely to provide an ideal occlusion**

1. Davies S J, Gray R J M. The pattern of splint usage in the management of two common temporomandibular disorders. Part III: Long term follow-up in an assessment of splint therapy in the management of disc displacement with reduction and pain dysfunction syndrome. *Br Dent J* 1997; 183: 279-283.
2. Galindo D, Soltys J L, Graser G N. Long-term reinforced fixed provisional restorations. *J Prosthet Dent* 1998; 79: 698-701.
3. Howat A P, Capp N J, Barrett N V J. A colour atlas of occlusion and malocclusion. p447-455. Wolfe Publishing Limited, 1991.
4. Parker M W. The significance of occlusion in restorative dentistry. *Dent Clin North Am* 1993; 37: 341-351
5. Briggs P F, Bishop K, Djemal S. The clinical evolution of the 'Dahl Principle'. *Br Dent J* 1997; 183: 171-176.
6. Ramfjord SP, Ash MM. Reflections on the Michigan occlusal splint. *J Oral Rehabil* 1994; 21: 491-500.

is a major challenge for the restorative team. Successful completion will depend upon not only the skill of the clinician and the technician, but also the clinician's planning.

The clinician will need to have:

1. An accurate record of the patient's pre-treatment occlusion
2. A clear idea of the occlusion of the definitive restoration, including the jaw relationship at which it is to occur
3. A detailed sequential plan on how the treatment will progress from 1 to 2, with stated objectives for each phase.

Although it can appear to be a very long way from the starting point to the declared objective, 'every long march has to start with a first step'. If the objective is defined and if the successful completion of each clearly defined step is the foundation for the next phase, success will be the outcome. The key is the sequential treatment plan.

Guidelines of good occlusal practice

- 1 The examination of the patient involves the teeth, periodontal tissues and articulatory system.
- 2 There is no such thing as an intrinsically bad occlusal contact, only an intolerable number of times to parafunction on it.
- 3 The patient's occlusion should be recorded, before any treatment is started.
- 4 Compare the patient's occlusion against the benchmark of ideal occlusion.
- 5 A simple, two dimensional means of recording the patient's occlusion before, during and after treatment is an aid to good occlusal practice.
- 6 The conformative approach is the safest way of ensuring that the occlusion of a restoration does not have potentially harmful consequences.
- 7 Ensuring that the occlusion conforms (to the patient's pre-treatment state) is a product of examination, design, execution and checking (EDEC)
- 8 **The 'reorganised approach' involves firstly the establishment of a 'more ideal' occlusion in the patient's pretreatment dentition or provisional restorations; and then adhering to that design using the techniques of the 'conformative approach'**