

Fibre optics

Surgery by sunlight on live animals

Even though the deployment of solar radiation for surgery^{1–3} must be restricted to clear-sky periods in sun-belt climates, its appeal lies in its potentially low cost compared with conventional laser fibre-optic treatments⁴. Here we show that interstitial fibre-optic solar surgery can be used effectively to kill tissue in live animals, with highly concentrated sunlight producing the same rapid, localized and extensive damage that is achieved in laser surgery. To our knowledge, this is the first time that intense incoherent light has been applied successfully in an interstitial medical procedure to kill a sizeable and prescribed extent of organ tissue photothermally.

The key factor in most photothermal fibre-optic surgery is not the coherence or monochromaticity of the light, but attaining sufficiently high power density. Solar radiation is particularly effective because its average optical-penetration depth is of the order of millimetres; also, it does not preclude the realization of ultra-high power densities in concentrators⁵.

Our prototype solar fibre-optic concentrator decouples the collection and delivery of high-density photon flux. A compact outdoor optical system transports several watts of solar radiation into the operating theatre through a flexible, high-transmissivity optical fibre of numerical aperture 0.66 and up to 20 m in length, at a power density commensurate with that of lasers used for surgery (of the order of several watts per mm²)^{1,3,5}. *Ex vivo* experiments on chicken breasts and livers indicate that a similar type, rate and extent of tissue transformation can be achieved by solar and laser surgery^{2,3}.

This comparable performance of solar and laser fibre-optic surgery stems from their equivalent optical and biophysical properties. The advantages of solar surgery over radiofrequency ablation, cryoablation and electrocautery are therefore the same as those for laser surgery in comparison with these techniques⁶. However, an advantage of solar compared with laser surgery, apart from cost, is that it does not carry the risk of eye injury to the operating team because concentrated light is delivered over a large angular range¹.

For these pilot clinical trials on live animals, our aim was to necrose (by means of coagulation and ablation) a roughly hemispherical liver lesion of about 1 cm³ volume (which corresponds to the size of an average tumour in rats), within a period of 100 s or so, by delivering 2–3 watts of highly concentrated solar radiation.

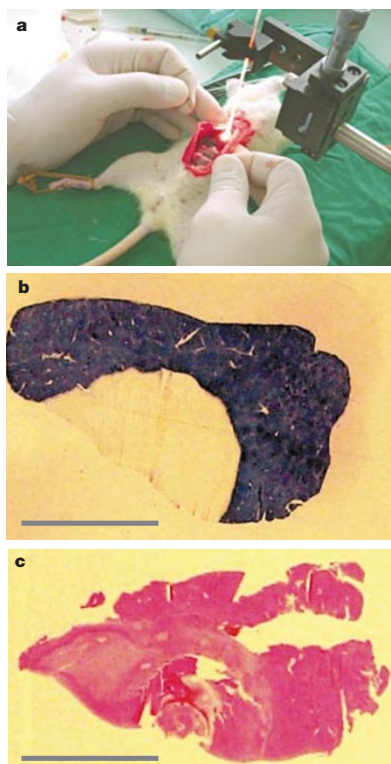


Figure 1 Solar surgery on a living rat, and the pathology of its liver after coagulation and ablation of a 12-mm section of tissue. **a**, Highly concentrated sunlight being injected into the liver of a live anaesthetized rat by using an optical fibre threaded from outdoors into the operating theatre. **b**, Transverse section of the liver lesion after staining for active NADH-dependent enzymes. Viable tissue is stained blue; the surgical lesion appears as a roughly hemispherical, transparent section. **c**, Transverse section of the same sample stained with haematoxylin and eosin, which also reveals dead tissue. The hepatocyte architecture is seen to be disrupted in the necrosed region. Experiments were carried out in accordance with the Helsinki Committee of the Soroka Medical Center and Ben-Gurion University, Beersheva, Israel. Scale bars, 10 mm.

A general anaesthetic was administered to two healthy 200-g female rats. The liver was exposed to view by scalpel incision on the animal's underside. Solar radiation — whose power was measured as 2.0–2.5 watts — was injected into the upper region of the liver from the distal tip of an optical fibre of 1.0 mm diameter (Fig. 1a). Each animal was irradiated twice, in two separate sections of its liver, for periods ranging from 40 to 180 s. The diameter of the resulting lesion was measured as about 12 mm immediately after the irradiation procedure.

The rats were revived and continued to function without complication. They were

killed 24 and 72 h later, respectively. Their liver pathology was investigated immediately with a specific stain for active NADH-dependent enzymes, which therefore identifies living tissue (Fig. 1b), and with haematoxylin-and-eosin stain, which stains both living and dead cells (Fig. 1c). The NADH-enzymatic stain therefore provides superior delineation of the necrosed region of each liver.

Longitudinal and transverse cuts revealed that necrosis was roughly hemispherical and symmetric. The lesion size after 24 h (about 1 cm³) was almost twice that recorded photographically at surgery, but did not increase after 72 h. These findings are consistent with lesion sizes recorded after liver surgery by laser, which increase progressively and markedly for about 24 h after treatment⁷.

Our results indicate that the efficacy of interstitial fibre-optic solar surgery — that is, the lesion volume per unit of injected light energy — is up to 5 mm³ per joule, which is comparable to that of laser surgery when used in similar procedures.

Jeffrey M. Gordon*†, **Daniel Feuermann***, **Mahmoud Huleihil***‡, **Solly Mizrahi**‡, **Ruthy Shaco-Levy**§

*Department of Solar Energy and Environmental Physics, Jacob Blaustein Institute for Desert Research, Ben-Gurion University of the Negev, Sede Boqer 84990, Israel

†Pearlstone Center for Aeronautical Engineering Studies, Department of Mechanical Engineering, and Departments of ‡Surgery A and §Pathology, Soroka Medical Center, and Faculty of Health Sciences, Ben-Gurion University of the Negev, Beersheva 84105, Israel

e-mail: jeff@bgumail.bgu.ac.il

1. Feuermann, D. & Gordon, J. M. *Opt. Eng.* **37**, 2760–2767 (1998).
2. Gordon, J. M., Feuermann, D. & Huleihil, M. *Appl. Phys. Lett.* **81**, 2653–2655 (2002).
3. Gordon, J. M., Feuermann, D., Huleihil, M., Mizrahi, S. & Shaco-Levy, R. *J. Appl. Phys.* **93**, 4843–4851 (2003).
4. Katzir, A. *Lasers and Optical Fibers in Medicine* (Academic, San Diego, 1993).
5. Feuermann, D., Gordon, J. M. & Huleihil, M. *Solar Energy* **72**, 459–472 (2002).
6. De Sanctis, J. T., Goldberg, S. N. & Mueller, P. R. *Cardiovasc. Intervent. Radiol.* **21**, 273–296 (1998).
7. Fujitomi, Y. *et al. Lasers Surg. Med.* **24**, 14–23 (1999).

Competing financial interests: declared none.

erratum

Vortex rings in a constant electric field

David G. Grier

Nature **424**, 267–268 (2003)

Yilong Han, the first author, was omitted from the list of authors of this communication. The correct listing should therefore be: Yilong Han, David G. Grier.

brief communications is intended to provide a forum for brief, topical reports of general scientific interest and for technical discussion of recently published material of particular interest to non-specialist readers (communications arising). Priority will be given to contributions that have fewer than 500 words, 10 references and only one figure. Detailed guidelines are available on Nature's website (www.nature.com/nature).