Spinal Cord (1998) 36, 797–799

http://www.stockton-press.co.uk/sc

Case Report

Brown-Sequard syndrome caused by a Kirschner wire as a complication of clavicular osteosynthesis

Luis Ignacio Carcavilla Loncán, Diego Ferrández Sempere and José Eiras Ajuria

Servicio Regional de Neurocirugía, Hospital 'Miguel Servet', Zaragoza, España

A case of spinal cord injury caused by delayed migration of a *Kirschner* wire is reported. Some cases of distant injuries caused by bone wires, and acupuncture needles have been published, but this is the first reported case of delayed thoracic spinal cord damage caused by the migration of a clavicular wire. A 22-year-old male patient was admitted with a clinical picture of spinal shock after performing physiotherapeutic exercises. Two months prior to this, the patient had undergone surgical treatment for a clavicular fracture in a different clinical center. Imaging showed a clavicular wire had migrated into the spinal canal. An early prescription of a spinal cord methyl-prednisolone protective treatment (NASCIS II), the surgical extraction of the foreign body and the rehabilitation exercises were the keys to a quick recovery.

Keywords: clavicle fracture; bone wire; spinal cord injury; Brown-Sequard Syndrome

Background

Surgical procedures are uncommon in the treatment of clavicular fractures, except in cases of instability. In such cases, binding can be performed using *Kirschner* wires, following *McKever's* technique of internal fixation.[1]

It is uncommon for these pins to migrate, mainly because orthopaedic surgeons usually bend the external tip of the wires in order to prevent displacements. Only one case of migration of a *Kirschner* wire into the spinal canal has been previously described, although no neural symptoms were described.[2] This is the first reported case of delayed thoracic spinal cord damage caused by migration of a clavicular fixation wire.

Clinical presentation

Previous history and anamnesis

Twenty-two year old male. Two months prior to being admitted into this Service of Neurosurgery the patient suffered minor cranial trauma and fracture of the distal third of the left clavicle, as a result of a traffic accident. This fracture was initially treated with non-surgical methods, but surgical osteosynthesis was required due to instability. Fixation was performed in another hospital using two *Kirschner* wires, one of which had later to be removed. Two months after surgery, while performing physiotherapeutic exercises, the patient suddenly felt a sharp interscapular and left cervical pain. He also suffered intense weakness in the legs. Later, severe cervico-brachialgia appeared, concentrated mainly in the medial half of the left arm. Urinary incontinence was also noticed.

Correspondence: Dr LIC Loncán

Neurological examination

The patient was conscious and no major functions were altered. Cranial nerves were normal. Muscular strength and sensitivity were assessed using the International Standards for Neurological and Functional Classification of Spinal Cord Injury.[3] Flexion-extension of ankle and knee and hip flexion in the lower left extremity: 1/5. The lower right extremity performed 3/5 for the same actions. Bicipital and radialis reflexes were diminished in the upper right extremity, and upper left responses were extremely weak. Patellaris, achilleus, abdominal, cremasteric and plantar reflexes were bilaterally absent. Pinprick sensitivity was 1/2 up to T5 dermatome, especially on the right side. Light touch remained unaltered in the right side, but it was affected in the left side (1/2) up to dermatome T3.

Imaging

A foreign body was detected in the osseous thorax study. The image revealed a surgical *Kirschner* wire, piercing between the second and the third thoracic vertebrae (Figure 1). A CT scan confirmed the canal piercing and the location of the wire in the spinal canal (Figure 2).

Treatment and results

We started the NASCIS II protocol for spinal cord injuries within 4 h of the onset of the syndrome.

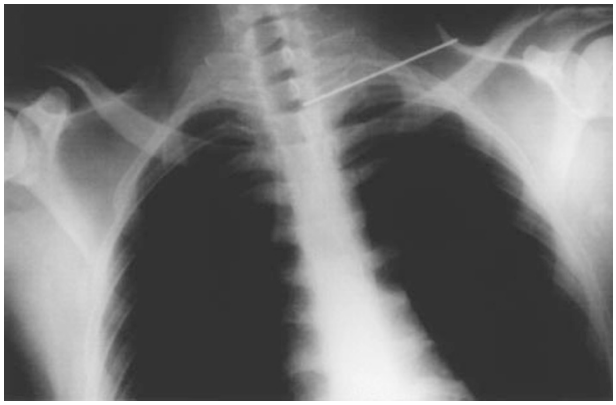

Figure 1 Osseous thorax x-ray image. *Kirschner* wire reaching the T2-T3 foramen



Figure 2 Vertebral CT slide. The wire is piercing the spinal canal through the T2-T3 left intervertebral *foramen*. The tip of the pin penetrates into the center of the canal

Surgical removal of the wire was carried out under general anesthesia. We performed a direct access via a left supraclavicular incision. We did not consider exposing the dura because of the danger and the uncertain benefits. The tip of the wire was clasped using pressure forceps and pulled out along the horizontal plane.

The patient began his rehabilitation exercises on the second day of the postoperative period. Two months later, he had already recovered sphincter control and could walk by himself with the help of a cane. He was neurologically asymptomatic four months after the treatment.

Discussion

Literature review

Spinal cord injuries caused by surgical materials that have been used to treat remote lesions are not commonly found. Perusing literature on similar subjects, we found some cases of neurological damage caused by migration of *Malbotsushin* acupuncture needles; this technique is based on the subcutaneous implantation of needles. The symptoms described are multiple: alterations to sensitivity, *Horner* syndrome, diplopia, headaches and even subarachnoid bleeding and arachnoiditis.[4–7]

Osteosynthesis procedures may induce some undesired side effects. The most common of these are usually related to localized problems due to infection. In some cases the wires may move and reach the vertebral bodies.[8] Intrathoracic and abdominal migration have also been described.[9–11]

Slow migration of distant osteosynthetic materials with penetration into the spinal canal and neurological damage is very rare. In the case published by Hinzpeter and Sartor[2] there were only visual disturbances resembling an optochiasmatic syndrome, nine months after treatment of the clavicular fracture. These findings were difficult to correlate to those of pin migration. However, the CSF study showed an increase in the albumin levels, leukocytosis and some red cells. One year after surgery, the foreign body was located with simple thorax radiology at C7-T1 level. The diagnosis was complemented with conventional tomography and angiography, which did not show any pathology.

Our experience

We can explain the migration of the pin as the conjunction of some factors. The pin was piercing the second cortical layer of the clavicle bone, the tip of the wire was not bent after implantation and the repetitive daily exercises were a good mechanism for the pin to advance.

In our patient, the symptoms started abruptly with pain, sudden paraparesis, urinary incontinence, and impairment of sensitivity. If we assess the clinical data, it is easy to make a topographic diagnosis.

The 'stab-like' pain was accurately distributed throughout the whole left T2 dermatome. Flaccid paraparesis, abolished reflexes and toneless sphincters are the initial expression of spinal pyramidal damage (shock phase). The effect on sensitivity was limited mainly to thermalgesia, especially in the contralateral side (lateral spinothalamic tract). Deep sensitivity was barely affected in the ipsilateral and caudal dermatomes, so the dorsal columns suffered minor trauma in this case. All of these data proved the lesion to be located in the left anterior quadrant of the T2 spinal segment.

The iconographic diagnosis of the foreign body was initially performed with a X-ray study and was complemented with a CT scan. This allowed us to discover the exact location and orientation of the wire in the canal. We considered the latter a more appropriate technique for the treatment planning.

We believe that this kind of complication is easy to prevent by bending the external tip of each implanted

wire. Also plates and screwed pins exist that may be used instead.

Acknowledgements

We would like to thank Alfonso Ferrández, Tim David, Andy Fenlon and Susi Thomas (Computational BioFluid Mechanics Group, School of Mechanical Engineering, The University of Leeds) and Beatriz Barriendos (Rehabilitation Department, Hospital Miguel Servet, Zaragoza) for their kind support.

References

1 Anderson K. Treatment of clavicular fractures. *Acta Orthop Scan* 1987; **58:** 71–78.
2 Hinzpeter Von T, Sartor K. Zum Problem Materialwanderung nach Osteosynthese. Eindringen eines *Kirschner*-Drahtes in den Spinalkanal. *Rofo Fortschr Geb Rontgenstr Nuklearmed* 1977; **127:** 493–494.
3 Maynard FM *et al*. International standards for neurological and functional classification of spinal cord injury. *Spinal Cord* 1997; **35:** 266–274.
4 Kida. Cervical spinal cord injury caused by acupuncture. *Arch Neurol* 1988; **45:** 831.
5 Kondo A, Koyama T, Ishikawa J, Yamasaki T. Injury to the spinal cord produced by acupuncture needle. *Surg Neurol* 1979; **11:** 155–156.
6 Murata K *et al*. Subarachnoid hemorrhage and spinal root injury caused by acupuncture needle. Case report. *Neuro Med Chir (Tokyo)* 1990; **30:** 956–959.
7 Oka N *et al*. Cervical adhesive arachnoiditis as a complication of acupuncture. *Rinsho Shinkeigaku* 1986; **26:** 874.
8 Habernek H, Walch G. Sekundare Drahtwanderung nach perkutaner Bohrdraht-Fixation einer Akromioklavikular luxation. *Aktuel Traumatol* 1989; **19:** 218–220.
9 Chou NS *et al*. Intrathoracic emigration of *Kirschner* wires. *J Formos Med Assoc* 1994; **93:** 974–976.
10 Peters J. Uber eine aussergewohnliche Komplikation nach osteosynthetischer Versorgung einer Klavikulafraktur. *Rofo Fortschr Geb Rontgenstr Neuen Bildgeb Verfahr* 1992; **156:** 1996–1997.
11 Naidoo P. Emigration of a *Kirschner* wire from the clavicle into the abdominal aorta. *Arch Emerg Med* 1991; **8:** 292–295.