Spinal Cord (1998) 36, 200–204

Long term follow up in lumbar spinal stenosis

Martin Scholz, Raimund Firsching and WR Lanksch

Department of Neurosurgery, Free University of Berlin, Department of Neurosurgery, Ruhr-University Bochum, Knappschaftskrankenhaus, In der Schornau 23-25, 44892, Bochum, Germany

In a retrospective study the charts of 72 patients who had decompressive surgery for lumbar stenosis between 1987 and 1990 were evaluated. Mean first follow up was 2.5 years (range 1.5 years to 3.5 years). A second follow up was done 8 years after surgery via mail. The mean age was 59.7 years (females 63.7, males 55 years). The average interval between the onset of complaints to surgery was 6 years. Claudicatio intermittens was found in 34.7% of cases. Patients were divided into four groups according to the classification by Arnoldi from 1976. Laminectomy or hemilaminectomy was performed in 73.6% of cases. In 68.1% nucleotomy was performed. In the first follow up outcome of patients was good in 73.6%. Complete recovery was noted in 61.1%. 11% were not satisfied with operative results. Old patients especially benefitted from the operation. In the second follow up after 8 years only 62.1% of the patients mentioned that their results were unchanged, good or better than at the first evaluation. The other 37.9% complained of a poorer result.

Keywords: lumbar spinal stenosis; laminectomy; spondylolisthesis

Introduction

In 1900 Sachs and Fränkel[1] reported on patients with an unusual disorder, which they termed 'claudicatio intermittens nervosa', pain and weakness in the legs after walking a short distance. Typically the patients stop walking while noting sudden numbness. The legs cannot be moved in spite of adequate arterial pulses. The authors attributed this disorder to a narrow spinal canal, which they called lumbar spinal stenosis.

There are several publications on the operative results in spinal stenosis with follow-up period of less than 1 year.[2] There are only a few reports on the long term results, but examination protocols are not uniform.[3]

This analysis deals with the long term results of 72 patients who were operated on in the department of Neurosurgery of the Free University of Berlin (Klinikum Rudolf Virchow) because of lumbar spinal stenosis between 1987–90. They were examined after an average time of 2.5 years after surgery (range 1.5–3.5 years) and were questioned again 8 years after surgery via mail. In all patients neuroradiological and intraoperative findings suggested stenosis of the spinal canal.

Patients and methods

Classification of patients (40 females, 32 males) was performed in a modification of the scheme of Arnoldi[4] from 1976. Four groups were distinguished:

Group 1
Constitutional and acquired stenosis without prolapse or protrusion of the nucleus pulposus (also Morbus Paget and fluorosis) = 9.7%

Group 2
Pseudospondylolisthesis without disc bulge = 23.7% Pseudospondylolisthesis was defined as a slipping of vertebral bodies without defect of the vertebral arch caused by degenerative disease of the facet joints.

Group 3
Any possible combination of stenosis with prolapse or protrusion or spondylolisthesis with prolapse or protrusion = 58.3%.

Group 4
Iatrogenic stenosis after laminectomy after ventral and dorsal fusion, after nucleolysis and spinal injury = 8.3%.

58.3% of our patients exhibited a combination of stenosis and nucleus pulposus prolapse (group 3). Average age of women was 63.7 years and of men 55 years (all patients 59.7 years) (Figure 1).

The symptoms were quite variable. The mean duration of presurgical complaints was more than 6 years. Claudicatio intermittens was found in 34.7%

Correspondence: M Scholz

Figure 1 Graph showing patient's age at time of operation

(25 patients). Ten of these patients described painful legs after walking a certain distance. Pain and sudden sensory deficit was observed in 5 patients and pain and sudden weakness in four. In four patients hypesthesia and sudden motor deficit were symptoms after walking a while. Only two patients in the 'claudicatio intermittens group' described sudden sensory deficit after a short distance without other complaints. The average distance that could be walked was 295 meters.

In general pain was the predominant symptom on admission to hospital and was reported in 68 of 72 patients (94.4%). In 32 cases firstly lumbar pain was described which changed to radicular pain in 22 patients 1–12 months prior to admission. Thirty-six patients reported lumbar and radicular pain from the beginning: 12 on both sides and 24 on one side. During neurological examination sensory deficits were found in 79.2% and motor deficits in 59.7% (43 patients). Bladder dysfunction was found in 6.9% of patients, but only in two cases other urological or gynecological causes could be excluded. There was a high incidence of coexisting medical diseases (Table 1). It is remarkable that three patients had previously been operated on for cervical myelopathy.

Neuroradiological diagnosis

CT-scan was performed in 80.6% of patients (Figures 2 and 3) and myelography in 66.7%. Mean location of all pathological findings was the lower lumbar spine, mainly segments L4 and L5. Magnetic resonance imaging (MRI) was used only in one case. Functional X-ray of the lumbar spine was done in patients with spondylolisthesis and pseudospondylolisthesis. There were 31 cases of spondylolisthesis grade I and II according to Meyerding[5] in 14 persons combined with a prolapse or protrusion.

Operative technique

Microsurgical procedures which were performed can be seen in Figure 4. Stenosis according to group 1 with bilateral pain was treated by laminectomy. In those

Table 1 Coexisting medical diseases in 72 patients operated for lumbar stenosis

Disease	*No. of cases*
Diabetes	9
Cervical myelopathy	3
Cancer	3
Coxarthrosis treated with hip replacement	2
Parkinson's disease	1
Dementia	1
Laurence-Moon-Biedl-syndrome	1
Apoplexia	2
Rheumatism	1
Coronary infarction	1
Artery occlusion treated with femoropopliteal bypass	1
Coronary arteriosclerosis treated with aortocoronary bypass	1

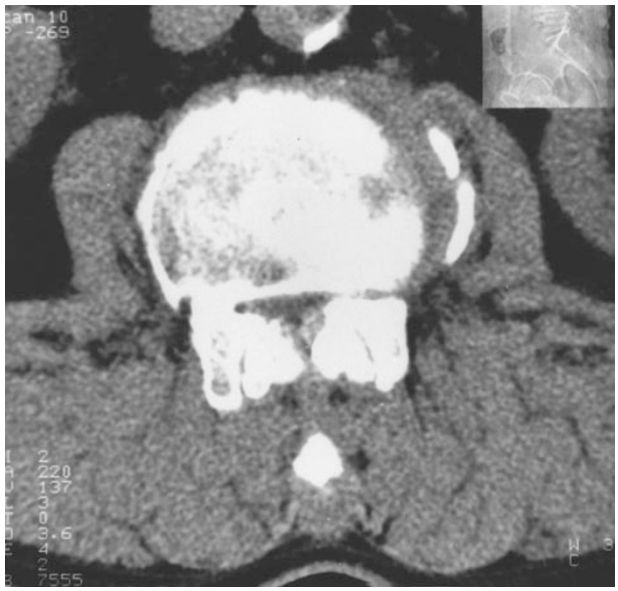

Figure 2 Computertomography of a 68 year old male in the level L3/4 shows central degenerative stenosis with hypertrophic facet joints

with unilateral stenosis (with unilateral complaints) hemilaminectomy was done when there was a combination of lumbar canal stenosis and prolapse hemilaminectomy, sequesterotomy and nucleotomy was chosen as the operative procedure. Patients with spondylolisthesis and pseudospondylolisthesis (group 2) were only decompressed by partial hemilaminectomy. Complete laminectomy was never done in these patients. Also implantation of fixation devices was not performed because functional X-ray of the lumbar spine could not reveal instability. Nucleotomy in patients with spondylolisthesis was avoided. In case of a sequestered prolapse only sequestrectomy was done. Foraminotomy and decompression of the lateral recesses was performed if necessary. In all of these

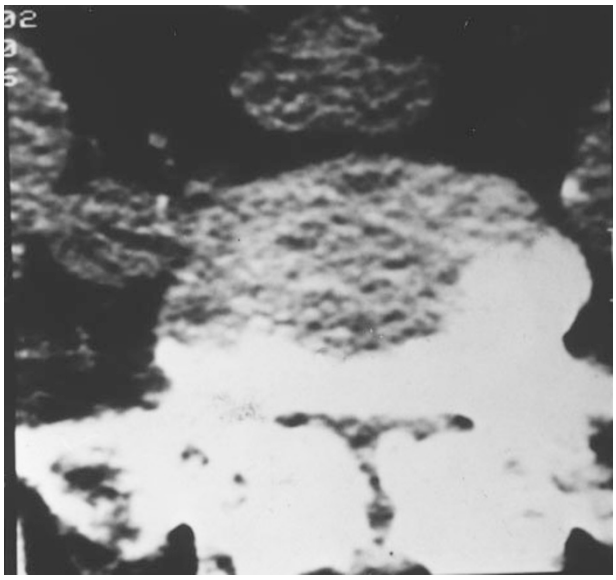

Figure 3 Computertomography of a 77 year old adipose female at the level L5/S1 demonstrates the typical cloverleaf-form of spinal canal in severe lateral stenosis

Complaints	*Points for scoring*	*Level of complaints*
Pain	0	no pain
	1	only after strain, shorter than half of the day
	2	pain at rest, more than half of the day
	3	like 2 with sleep disturbance or gait disturbance
	4	like 2 or 3 + high intake of pain medication
Motor activity	0	no motor deficit
	1	slight paresis (not noted by patient)
	2	moderate paresis
	3	severe paresis
	4	like 3 + severe gait disturbance claudicatio intermittens nervosa
Sensory deficit	0	no sensory deficit
	1	slight sensory deficit
	2	marked sensory deficit

The maximum score a patient with severe complaints could reach in this scheme was 10

patients the facet joints were only partially resected (medial) in order to preserve stability.

Hemilaminectomy or laminectomy of at least one segment was done in 53 patients (73.6%). In most of these patients two segments were decompressed (69%). 17.2% of patients were operated on in one segment and 13.8% in three segments. In the other patients flavectomy or partial hemilaminectomy was performed only. Nucleotomy was done in 68.1% in one or more segments.

Fifty-one patients were operated on only once, 21 patients several times. In 38.1% the first operation was performed at another hospital: 10 patients were operated on twice, six patients three times and five patients four times. In 10 cases only the diagnosis 'spinal stenosis' was made prior to the first operation. In all of other cases the diagnosis was made prior to the second, third or fourth operation. In 17 cases with multiple surgery the first operation was a nucleotomy.

A postoperative complication was only seen in one patient. After laminectomy a pseudomenin gocele causing radicular pain was found. After operative repair an epidural hematoma developed which was removed at a third operation, leading to complete recovery.

All patients were interviewed and examined by the first author according to a protocol which includes anamnesis of pre- and postoperative complaints, medical history and neurological examination. To complete our evaluation patients were asked for their subjective view of operative success. The patient's complaints and neurological deficits prior to surgery and at the postoperative follow-up examination were evaluated according to the following scheme.

With this scheme we tried to quantificate pain in four levels, motor deficit in four grades and sensoric deficit in two levels. Preoperative score and score at the follow-up examination were compared. Eight years after surgery the patients were evaluated again via mail. They had to answer if their outcome was unchanged, good, better or poorer than at the first follow up. They were also asked about any other operations to the lumbar spine.

Results

The invented scheme was highly suitable for analysing the postoperative results. With the help of this scheme patients could be separated in group A–D: 12.5% of patients (group A) have no pain and no complaints. 48.6% (group B) improved and in 9.7% (group C) the score remained unchanged. In 29.2% (group D) deterioration was found.

Postoperatively motor deficits were registered in 50% (36 patients). Six patients did not register their deficit, 6 other patients suffered from severe gait disturbances. During neurological follow up examination sensory deficits were found in 65.3% (46 patients). Seventeen patients of these persons had never known about their deficit prior to follow up evaluation.

After surgery 81.9% of patients reported mild lower lumbar back pain without radicular involvement. Severe pain level 3 and 4 was reached only by nine patients (12.5%) postoperatively. By contrast, prior to surgery 21 patients (29.2%) were selected in this group.

Therefore patients with spinal stenosis cannot expect a completely painfree life postoperatively. Due

to severe degenerative changes there remain some complaints which normally do not influence their lifestyles. To underline this point 73.6% of patients considered the operative result excellent or good 15.3% were indifferent and 11.1% were not satisfied with the result of operation. In the subgroup of 6 patients older than 75 years the rate of success was 100%. In 31 patients with stenosis caused by spondylolisthesis 61.3% had a good result.

Eight years after operation 25 patients could not be evaluated. In the other 47 patients the late outcome could be determined. Four of these persons had died one or two years before the questioning but near relatives could describe the outcome. 62.1% felt unchanged good or better than at the first evaluation. 37.9% complained about a poorer result. In this group of poorer outcome all four groups of stenosis were included without significant predominance. Three patients had undergone further operations: one male received a titanium implant because of instability. One patient underwent the implantation of an electric pain stimulator and another required two other decompressive operations on the lumbar spine.

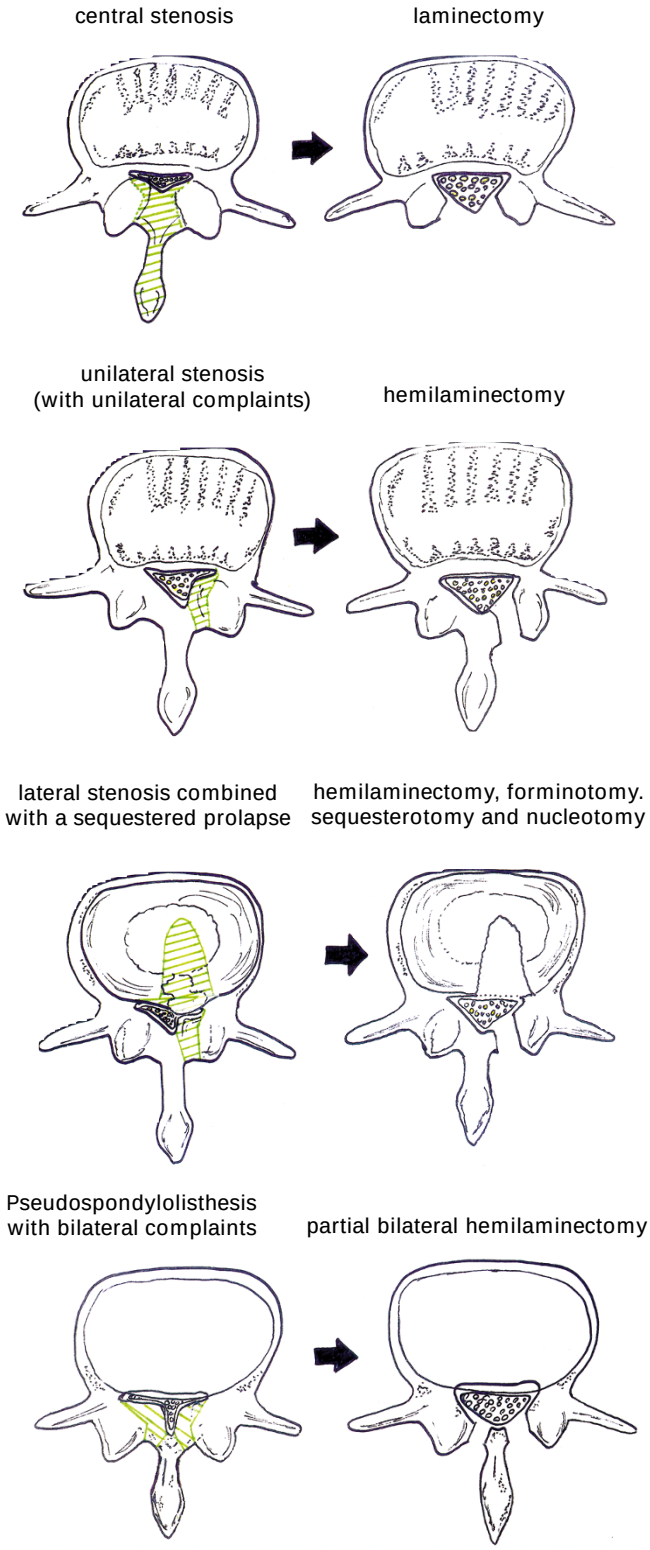

Figure 4 Microsurgical procedures in different kinds of spinal stenosis. (green: resected bony structure)

Discussion

The results from a long term follow up in patients treated for spinal stenosis are rarely reported in the literature. Several publications[2] are based on follow up periods of less than 1 year.[6] Other studies are dealing with selected subgroups of patients; Fast[7] evaluated the surgical results in lumbar spinal stenosis in the elderly.

Caputy and Luessenhop[3] reported on a long term follow up of 88 patients 5 years after decompressive surgery for degenerative lumbar stenosis. Mean age (67 years) was higher than in our study (59.7 years). They had excluded 20 patients who had undergone surgery for stenosis following discectomy at the same spinal level and stenosis following fusion for spinal fractures, scoliosis, spondylolisthesis secondary to spondylosis and instability secondary to spinal tumors. The authors suggested that spondylolisthetic stenosis tended to recur within a few years following decompression. They recommended stabilization at the site of spondylolisthetic stenosis in addition to decompressive surgery. This is controversial in the literature: Verbiest remarked in 1977[8] that in spite of a decompression instability of the spine was only slightly increased except when the spondylolisthesis was present. Herkowitz and Garfin in 1989[9] found a better result in patients undergoing decompressions who did not have spondylolisthesis than in patients with spondylolisthesis. This is similar to our results. Tile *et al*[10] observed in six cases of spondylolisthesis and two cases of new spondylolisthesis no symptoms attributable to an instability. In 1991 Herkowitz and Kurz[11] evaluated 53 patients and concluded that spinal stenosis combined with degenerative spondylolisthesis should undergo fusion following decompression.

In our study all groups of stenosis according to the scheme of Arnoldi[4] from 1976 were included. It is thought that the combination of stenosis or spondylolisthesis with a disc bulge is most important for the

understanding of nerve root compression in spinal stenosis. In this analysis 58.3% suffered from stenosis in addition to a prolapse or protrusion. Following the publications of Verbiest[12,13] we have to differentiate between absolute and relative stenosis. Patients with a relative stenosis and a sagittal diameter of 10–12 mm of the spinal canal could be asymptomatic until additional nerve compression by a protrusion of the disc adds to the stenosis.

If only nucleotomy without bony decompression is performed, results would be unsatisfactory. It is suggested that the high incidence of reoperations in our population of 29.2% can be explained in this way. In most cases the diagnosis of spinal stenosis was made after failure of routine lumbar nucleotomy without bony decompression.

In the face of the pathophysiology of lumbar spinal stenosis and it is mostly degenerative origin with e.g. bony hypertrophy of the facet joints also in other lumbar levels it is quite understandable that the postoperative outcome is poorer 8 years after surgery.

Lumbar myelography is thought to be the best diagnostic procedure to detect stenotic levels of the lumbar spine. Caputy and Luessenhop[2] performed myelography in every patient. In our study it was used in 66.7%. A combination with a post-myelo CT should be recommended.

The high incidence of coexisting medical diseases is an important factor for pre-, intra- and postoperative care of patients with lumbar spinal stenosis. Narrowing of the cervical spine with cervical myelopathy in addition to lumbar spinal stenosis, which had been observed in three cases in this series, has been known for more than 30 years.[14] In 1987 T Forcht Dagi and MA Tarkington[15] created the term 'tandem spinal stenosis'.

To obtain further information about the prognosis in lumbar spinal surgery it is necessary to evaluate a greater number of patients with precise examination protocols according to the different forms of stenosis as recommended by Arnoldi[4] for a longer follow up.

References

1 Sachs B, Fraenkel J. Progressive ankylotic rigidity of the spine (Spondylose rhizomelique). *J Nervous Ment Dis* 1900; **27:** 1–15.
2 Krüger J, Tönnies H, Senff H. Zum Krankheitsbild der Claudicatio intermittens nervosa bei lumbaler Spinalstenose. *Neurochirurgia* 1985; **28:** 121–129.
3 Caputy AJ, Luessenhop AJ. Long-term evaluation of decompressive surgery for degenerative lumbar stenosis. *J Neurosurg* 1992; **77:** 669–676.
4 Arnoldi CC *et al*. Lumbar spinal stenosis and nerve root entrapment syndromes. *Clinical Orthopaedics and related Research* 1976; **115:** 4–5.
5 Meyerding HW. Low backache and sciatic pain associated with spondylolisthesis and protruded intervertebral disc: incidence, significance and treatment. *J.B.J.* 1943; **461:** 23.
6 Conzen M, Sollmann H. Erfahrungsbericht über 210 Laminektomien bei erworbenem engem Spinalkanal. *Nervenheilkunde* 1986; **5:** 90–91.
7 Fast A, Robin GC. Surgical treatment of lumbar spinal stenosis in the elderly. *Arch Phys Med Rehabil* 1985; **66:** 149–151.
8 Verbiest H. The results of surgical treatment of idiopathic developmental stenosis of the lumbar vertebral canal. A review of twenty-seven years' experience. *J Bone Joint Surg [Br]* 1977; **59:** 181–188.
9 Herkowitz HN, Garfin SR. Decompressive surgery for spinal stenosis. *Semin Spine Surg* 1989; **1:** 163–167.
10 Tile M *et al*. Spinal stenosis. Results of treatment. *Clin Orthop* 1976; **115:** 104–108.
11 Herkowitz HN, Kurz LT. Degenerative lumbar spondylolisthesis with spinal stenosis. A prospective study comparing decompression with decompression and intertransverse process arthrodesis. *J Bone Joint Surg (Am)* 1991; **73:** 802–808.
12 Verbiest H. A radicular syndrome from developmental narrowing of the lumbar vertebral canal. *J Bone Joint Surg [Br]* 1954; **36:** 230–237.
13 Verbiest H. Fallacies of the present definition nomenclature and classification of the stenoses of the lumbar vertebral canal. *Spine* 1976; **1:** 217–225.
14 Brain R, Wilkinson M. The association of cervical spondylosis and disseminated sclerosis. *Brain* 1957; **80:** 456–478.
15 Dagi TF, Tarkington MA, Leech JJ. Tandem lumbar and cervical stenosis. *J Neurosurg* 1987; **66:** 842–849.