

peak peroxide value. The effect of increasing compression ratio on the aldehyde concentration parallels the effect on the peroxide curve. Tetraethyl lead uniformly decreases the aldehyde concentration at all points.

As regards the nature of the aldehydes produced, repeated tests with dimedone gave only the formaldehyde derivative.

This work has been carried out at the Ricardo Laboratory on behalf of the Shell Petroleum Co.

R. W. WHEELER
D. DOWNS

Ricardo and Co., Eng. (1927), Ltd.,
Bridge Works,
Shoreham-by-Sea.

A. D. WALSH

Laboratory of Physical Chemistry,
Cambridge.
July 2.

¹ *Phil. Trans. Roy. Soc., A*, **234**, 433 (1935).

² *Trudy Vsesoyuz Konfrentsi Anal. Khim.*, **2**, 608 (1943).

³ *Ind. and Eng. Chem., Anal. Edit.*, **6**, 241 (1934).

Infectious Chlorosis of Bananas in the Cameroons

DURING recent years, there has been a considerable extension of the cultivation of the Gros Michel banana in the British Cameroons. Vascular wilt disease (*Fusarium oxysporum cubense*) and *Cercospora* leaf-spot disease (*Cercospora musae* Zimm), which are both present there, are already well known to the planting community. Here I wish to direct attention to a virus disease which I observed during a recent visit. This disease, which has been described as 'infectious chlorosis' or 'heart rot' by Magee¹ and Morwood², has been recorded in New South Wales by these observers³ and in Guadeloupe and Haiti by myself^{4,5}.

In the Cameroons, infectious chlorosis has been observed in several plantations. The virus is known to be transmitted by the aphid *Pentalonia nigronervosa*¹; this is also present. According to the Australian workers, this disease is potentially as destructive as the better-known bunchy-top disease, caused by a different virus but also transmitted by the banana aphid. In the Cameroons the evidence (so far as I was able to ascertain during a brief visit) is that infectious chlorosis is at present of occasional occurrence but is capable of spreading under the local environmental conditions. Accordingly, Magee's warning of the possible destructiveness of this disease should be given due heed by all concerned with this valuable industry.

The symptoms include a characteristic chlorosis of the leaf (linear spots from midrib to margin), the development of localized, internal regions of necrosis in the leaf sheaths of the trunk, rotting of the heart leaves and the death of the plant before the onset of fruiting³.

C. W. WARDLAW

Department of Cryptogamic Botany,
University of Manchester.
Oct. 11.

¹ Magee, C. J., *Agric. Gaz. N.S. Wales*, **41**, 12 (1930).

² Morwood, R. B., *Ann. Rept. Queensland Dept. Agric.*, 1930-31, 47 (1931).

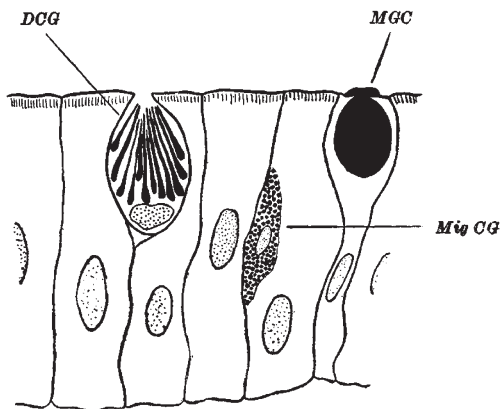
³ Wardlaw, C. W., "Diseases of the Bananas", 377-379 (London, 1935) (contains summaries of refs. 1 and 2).

⁴ Wardlaw, C. W., *Trop. Agric.*, **14**, 10 (1937).

⁵ Wardlaw, C. W., *Trop. Agric.*, **15**, 276 (1938).

Coarse Granulocytes in Epithelial Tissues of Teleost Fishes

IN the course of an investigation of blood-cell formation in teleost fishes, a peculiar formation has been seen in the intestinal mucosa and gill epithelium. Apparently the coarse granulocytes commonly found in these tissues migrate towards the surface and the granules elongate, appearing like long narrow clubs with pointed ends converging towards the epithelial surface. This regular characteristic pattern of arrangement was first noted by Duthie¹ in the mesenteries of teleost fishes of the families Labridae and Triglidae. I have seen it in the intestinal mucosa and gill epithelium of *Ttenolabrus rupestris* (Labridae) and *Trigla cuculus* (Triglidae), and also in the same sites in trout and roach. In trout and roach I have observed similar formations in the walls of kidney tubules and in the peritoneal coat of many internal organs.



Intestinal mucosa of trout. Fixed Zenker-formol. Stained Giemsa
DCG = Discharging coarse granulocyte; MGC = mucous goblet cell; Mig CG = migrating coarse granulocyte

Careful examination of dogfish, frog and mammalian material has not revealed a single example of such a condition. The appearance suggests a discharge of a fluid substance from the interior of the granules. These modified granules may be regarded as vesicles, containing a fluid which is discharged at the epithelial surfaces detailed above, the 'wall' of the vesicle remaining for a time in the cell body.

W. T. CATTON

Physiology Department,
Medical School,
King's College,
Newcastle-upon-Tyne 2.

¹ Duthie, E. S., *J. Anat.*, **73**, 306 (1939).

Burrowing of the Lugworm

IN his recent letter in *Nature*¹, Wells gives an interesting account of the movements and action of the proboscis of the lugworm and of the part that it plays in burrowing. He considers that its movements alone are sufficient to account for this activity, which is chiefly due to the diverging teeth of the buccal mass scraping away soil particles in the line of advance. He appears to consider that the physical properties of the soil are of no direct importance to burrowing, which he likens to that of a "digging rabbit".