Neuropsychopharmacology REVIEWS (2008) 33, 181–197

Brain Neuroplasticity in Healthy, Hyperactive and Psychotic Children: Insights from Neuroimaging

Judith L Rapoport[1] and Nitin Gogtay*,[1]

[1]*Child Psychiatry Branch, NIMH, Bethesda, MD, USA*

Noninvasive brain imaging permits longitudinal studies of anatomic brain development in healthy and psychiatrically ill children. The time course for gray matter maturation varies by region and parallels earlier histological studies, indicating dynamic patterns of overproduction and regression. Developmental trajectories vary in relation to gender, intelligence, and overall functioning. Twin studies show high heritability for brain volumes, which varies with region and with age. Diagnostically specific, illness-related changes as well as outcome-associated plastic response are observed as illustrated for two pediatric populations, childhood-onset schizophrenia and attention-deficit/hyperactivity disorder, conditions which may be, in part, disorders of brain plasticity.

Neuropsychopharmacology Reviews (2008) **33,** 181–197; doi:10.1038/sj.npp.1301553; published online 12 September 2007

Keywords: brain; neuroplasticity; neuroimaging; healthy development; childhood schizophrenia; ADHD

INTRODUCTION

Neuroplasticity is the change in neural structure and function in response to experience or environmental stimuli. The question of whether and how much the environment influences brain development is of broad general interest, with particular attention from the fields of developmental neurobiology, child development, education, and child psychopathology. The availability of brain imaging, particularly suitable for pediatric studies due to its safety, has enabled human developmental studies.

Structural MRI studies in adults have shown activity-dependent plastic responses in the brain structure, such as the increased hippocampal volume (which is involved in spatial navigation) in London taxi drivers that correlated with the amount of time spent in navigating the streets of London (Maguire *et al*, 2000). However, individual trajectories for these changes can only be addressed by longitudinal studies.

Functional imaging studies have the advantage of performance measures that can be obtained simultaneously with imaging that let us visualize the plastic reorganization of various brain regions in response to stimuli. For example, subjects learning sequential finger movements show alterations in the motor cortex, cerebellum, and basal ganglia (Elbert *et al*, 1995; Ungerleider *et al*, 2002) or healthy adult subjects trained in juggling show transient activity-dependent structural changes in visual motor cortex (Draganski *et al*, 2004).

Here, we discuss brain plasticity, particularly, as it relates to childhood psychopathology. Early cross-sectional and more recent longitudinal data show dynamic age-related changes that can vary with intelligence, clinical status, and/or treatment and long-term outcome. A wealth of normal and clinical data has been acquired in recent years which we discuss for normal brain development, and that for two childhood disorders: childhood-onset schizophrenia (COS) and attention-deficit/hyperactivity disorder (ADHD). Although some functional studies are mentioned, closer attention is paid to structural brain morphology. Similarly, while Diffusion Tensor Imaging (DTI) has begun to be studied in pediatric populations (Cascio *et al*, 2007), this important area is not addressed, as no DTI studies have yet focused on plastic change.

Throughout this review are speculations about possible mechanisms underlying anatomic brain MRI changes seen in healthy and clinical psychiatric populations. It needs to be clear at the outset that the MRI gives no information about the cellular correlates of the anatomic brain changes discussed in this review. The wealth of information about synaptic development in relation to age and to function has led to common 'shorthand' of interpreting many of these changes in terms of synaptic production and pruning. The weakness in this approach is not only that we do not have sufficient documentation of the underlying actual brain changes, but the field itself remains in flux as to what actual cellular components are involved at various time points (Sur and Rubenstein, 2005).

*Correspondence: Dr N Gogtay, Child Psychiatry Branch, NIMH, Bldg 10, Room 3N202, MSC-1600, Bethesda, MD 20892, USA, Tel: +1 301 435 4494, E-mail: gogtayn@mail.nih.gov
Received 7 May 2007; revised 11 July 2007; accepted 30 July 2007

PLASTICITY DURING BRAIN DEVELOPMENT

Childhood is a time of considerable changes in brain anatomical structure and connectivity (Huttenlocher, 1979; Huttenlocher and de Courten, 1987; Casey *et al*, 2000) and there is more striking evidence for plastic brain changes in childhood. As mechanisms of neural circuitry development are increasingly understood, phenomena surrounding behavioral development formerly referred to as 'sensitive periods' are being reframed in terms of brain plasticity with the recognition that some are only attributable to the immature brain (Knudsen, 2004).

During fetal development, neurons proliferate from early precursor cells that migrate radially outward from the ventricular zone to establish the normal cellular architecture of the cerebral cortex (Caviness and Takahashi, 1995). This leads to a human brain with about 100 billion neurons at birth. Following the neuronal migration, dendrites and axons arborize forming the intercellular communications and synapses. In humans, the initial overproduction of neurons is followed by selective apoptosis later in gestation resulting in the loss of up to 50% of cortical neurons (Rabinowicz *et al*, 1996). Similarly, during early postnatal brain development, there is a marked increase in synaptic density reaching substantially above adult levels (Bourgeois and Rakic, 1993; Bourgeois *et al*, 1994) which are subsequently 'pruned' during childhood and adolescence to adult levels with primary sensory and motor regions maturing early relative to regions subserving more complex functions (Huttenlocher and Dabholkar, 1997). Recent evidence indicates that further functional parcellation of cerebral cortical areas into discrete processing centers involves a rich array of signals, with complex interaction, between mechanisms both intrinsic to cortical progenitors and neurons and environmental stimuli extrinsic to the cortex requiring neural activity such as light stimulation to the developing eye (Sur and Rubenstein, 2005).

ADAPTIVE/COMPENSATORY PLASTICITY

Unique childhood plasticity has been demonstrated particularly in the areas of vision, audition, motor, and language abilities (Huttenlocher *et al*, 2002; Neville and Bavelier, 2002; Spessot *et al*, 2004). In both animals and humans, early lesions undergo more efficient repair. It is clear, for example, that lesions such as therapeutic hemispherectomy or stroke are handled better in childhood than at later ages. Perhaps the best known example of compensatory plasticity could be seen in the observation that the functional effects of strabismus (squint) in the infant are different from that in the adults. In infancy, strabismus causes suppression of the image from the squinting eye, whereas in adults squint causes persistent double vision, a disabling symptom. Surgical correction with preservation of vision is possible up to the age of 7 years (VonNoorden and Crawford, 1979). A similar period for maximal plasticity for auditory cortex has been defined within the first 7 years of life in children fitted with cochlear implants for early deafness (Sharma *et al*, 2002). These observations have led to the hope that treatment of cognitive or behavior disturbance during the childhood years might be more effective in reshaping trajectories of early development either to normalize or compensate for earlier abnormalities.

Age-related adaptive plasticity has been particularly well studied in relation to language functions. Unilateral brain damage with focal brain injury to the left cerebral hemisphere causes aphasia in adults but not in infants and young children. Although inconsistencies remain with these observations, as lesions in Wernicke's area in infants are still associated with some delay in language production (Bates, 1993) and subtle language deficits in children remain with early left hemisphere damage (Vargha-Khadem *et al*, 1994; Isaacs *et al*, 1996), there is general agreement about strikingly less impairment to language function when lesions are in early childhood. Similarly, recent functional studies indicate that training in the auditory domains (using musical or auditory working memory tasks) leads to improved reading skills in reading disabled populations (Gaab *et al*, 2005; Tallal and Gaab, 2006) raising the possibility as to whether auditory/musical training could also influence normal language development.

Another area of adaptive plasticity has been the adverse effects of drugs on the developing brain (Andersen and Navalta, 2004). There is a general concern that the use of psychotropic drugs in children will lead to drug-induced plasticity introducing harmful changes in the circuits of developing brains. Stimulant drugs in particular have been the subject of concern, because stimulant drugs exposure can produce sensitization of certain behaviors in animal models and addiction in humans. Some representative studies (Bolanos *et al*, 2003; Carlezon *et al*, 2003) administered methylphenidate during pre-adolescent periods of development in rats and observed the effect on subsequent adult behaviors in response to emotional stimuli. Bolanos *et al*, found methylphenidate decreased responsiveness to rewarding stimuli. Both groups also found the exposed animals more responsive to aversive stimuli as adults. The interest in these reports is based primarily on their possible relevance for clinical research and practice. However, any implications at this point would seem premature. There is no evidence that stimulant drug treatment for ADHD increases risk for substance abuse and, in fact, some evidence to suggest that the treatment decreases the risk (Biederman *et al*, 1999). Nonetheless, these studies are instructive as to how ultimately clinical research will likely reveal the most useful information on drug-induced brain changes in relatively subtle disorders such as ADHD.

A more interesting possibility based on preclinical or pharmacological studies is that early GABAergic drugs might alter critical period plasticity. Experience-dependent plasticity shapes the early postnatal brain, as exemplified by the loss of responsiveness to an eye briefly deprived of vision during a critical period, which results in severe amblyopia (poor visual acuity) (Fagiolini *et al*, 2004). Critical period onset can be delayed indefinitely if release of inhibitory neurotransmitter gamma aminobutyric acid (GABA) is kept low by gene-tarted disruption of its synthetic enzyme glutamic acid decarboxylase 65 (GAD 65) (Fagiolini and Hensch, 2000). The specificity of the GABA circuitry underlying visual cortical plasticity was studied using benzodiazepine agonists concurrently with monocular deprivation to prematurely trigger ocular

dominance plasticity (Fagiolini *et al*, 2004). This further showed that only GABA alpha-1-containing circuits drove cortical plasticity, whereas alpha-2 did not. This has implications for the safe design of benzodiazepines for use in children.

MECHANISMS IN PLASTICITY

The molecular mechanisms in developmental as well as adaptive/compensatory plasticity are still largely unknown. Much of the brain development is assumed to require modification of gene expression and protein production (Lamprcht and Ledoux, 2004). However, the role of environment in the development of neural circuits is increasingly being understood with the abundant evidence for the influence of experience-dependent activity in shaping the ultimate synaptic patterns (Hebb, 1949; Changeux and Danchin, 1976; Kandel *et al*, 2000). There is also evidence for plasticity in functional connectivity as seen in primates, where opposing wrist muscle movements could be reversed using an electronic neural implant (Jackson *et al*, 2006) and thus plasticity across modalities would imply more extensive connectivity within the involved regions (Neville and Bavelier, 2002).

Development of cortical areas involves a rich interplay of signals intrinsic to cortical progenitors and neurons with those extrinsic to the cortex requiring neural activity (Knudsen, 2004; Sur and Rubenstein, 2005). For example, repetitive activation (in response to external stimuli) of excitatory synapses increases the synaptic strength through a phenomenon called long-term potentiation (LTP) in many brain regions that are crucial in learning and memory (Malenka and Nicoll, 1999). This process in which synaptic connections are refined requires localized increase in intracellular calcium in dendritic spines, which is typically achieved via the activation of the NMDA subtype of glutamate receptor (McDonald and Johnston, 1990; Penn and Shatz, 1999) and is modulated further by activation of AMPA subtype of glutamate receptors (Malenka and Nicoll, 1999; Barry and Ziff, 2002). Persistent coincident firing of neurons leads to calcium entry through NMDA receptors into post-synaptic neurons and release of trophic factors that support synaptic connections (Kovalchuk *et al*, 2002). We propose that enhanced activation of the immature NMDA receptors would lead to enhanced plasticity (Crair and Malenka, 1995; Crair, 1999). The activity of the excitatory glutamatergic neurons is also modulated by inhibitory interneurons which use the major neurotransmitter GABA and also provide an important inhibitory signal for the development of neural networks (Zhang, 2006). Cortical GABA interneurons are a heterogeneous population with functionally and morphologically distinct subtypes, and thus consequences of GABAergic deficits depend on which subpopulation is affected. For example, in schizophrenia, only the calcium binding protein 'parvalbumin' expressing interneurons (chandelier cells) are affected (Lewis and Moghaddam, 2006). Recent studies suggest that the neurotrophin BDNF influences the GABA release by promoting the mobilization of presynaptic calcium channels near the vesicle release site (Woo and Lu, 2006). Thus, either the up- or downregulation of calcium channels on both glutamatergic (NMDA) as well as GABAergic neurons (with resultant changes in the $Ca++$ traffic in and out of the neurons) appears central in the mechanisms of neuroplasticity. This is of interest in light of the exaggerated gray matter loss seen in very early-onset schizophrenia as discussed below.

CEREBELLAR DEVELOPMENT

Although only 10% of total brain volume, the mature cerebellum contains more than half of the CNS neurons. It is the most sexually dimorphic part of the brain (the only regional volume remaining significantly larger in males after controlling for total cerebral volume). The cerebellum is critical for motor learning in vertebrates and evolutionarily conserved. Recently developed semiautomated measures allow for developmental studies of cerebellar regions (Pierson *et al*, 2002) and a number of recent imaging findings lead to its prominence in this review. Although it is one of the first brain structures to differentiate, it is one of the last to achieve maturity as cellular organization of the cerebellum continues to change for many months after birth. This protracted developmental process not only creates a special susceptibility to disruptions (Wang and Zoghbi, 2001), but also suggests its relevance to cognitive functions that develop during adolescence. Recent animal studies on simple behaviors such as vestibule-ocular reflex show that multiple plasticity mechanisms contribute to the cerebellum-dependent learning (Boyden *et al*, 2004), and functional and lesion studies have also documented important cognitive roles for the cerebellum (Desmond and Fiez, 1998; Desmond *et al*, 2005).

BRAIN MRI AND NORMAL BRAIN DEVELOPMENT

Developmental Trajectories

Considerable effort has gone into the use of non-invasive brain MRI for studies in pediatric populations (Caviness *et al*, 1999; Toga *et al*, 2006). Differences in cognition, behavior, and emotion between children and adolescents are self evident. Animal and postmortem studies have been informative, but have not been able to address how individuals change over time, what is the extent of variability between individuals and what factors impact these changes. Magnetic resonance imaging (MRI) has permitted serial observations of human development, and allowed us to address some of these questions (Toga *et al*, 2006).

Earlier longitudinal studies by Giedd *et al* (1999), using whole-lobe gray matter volumes confirmed, for the first time, the nonlinear nature of human gray matter development (Sowell *et al*, 2003). Gray matter increases during childhood and adolescence and then decreases with peak ages differing between the lobes, whereas the white matter myelination process appears to continue well into adulthood. In addition to the lobar GM heterogeneity, this study also showed a pronounced effect of gender with females reaching peak GM volumes typically 1–2 years earlier than

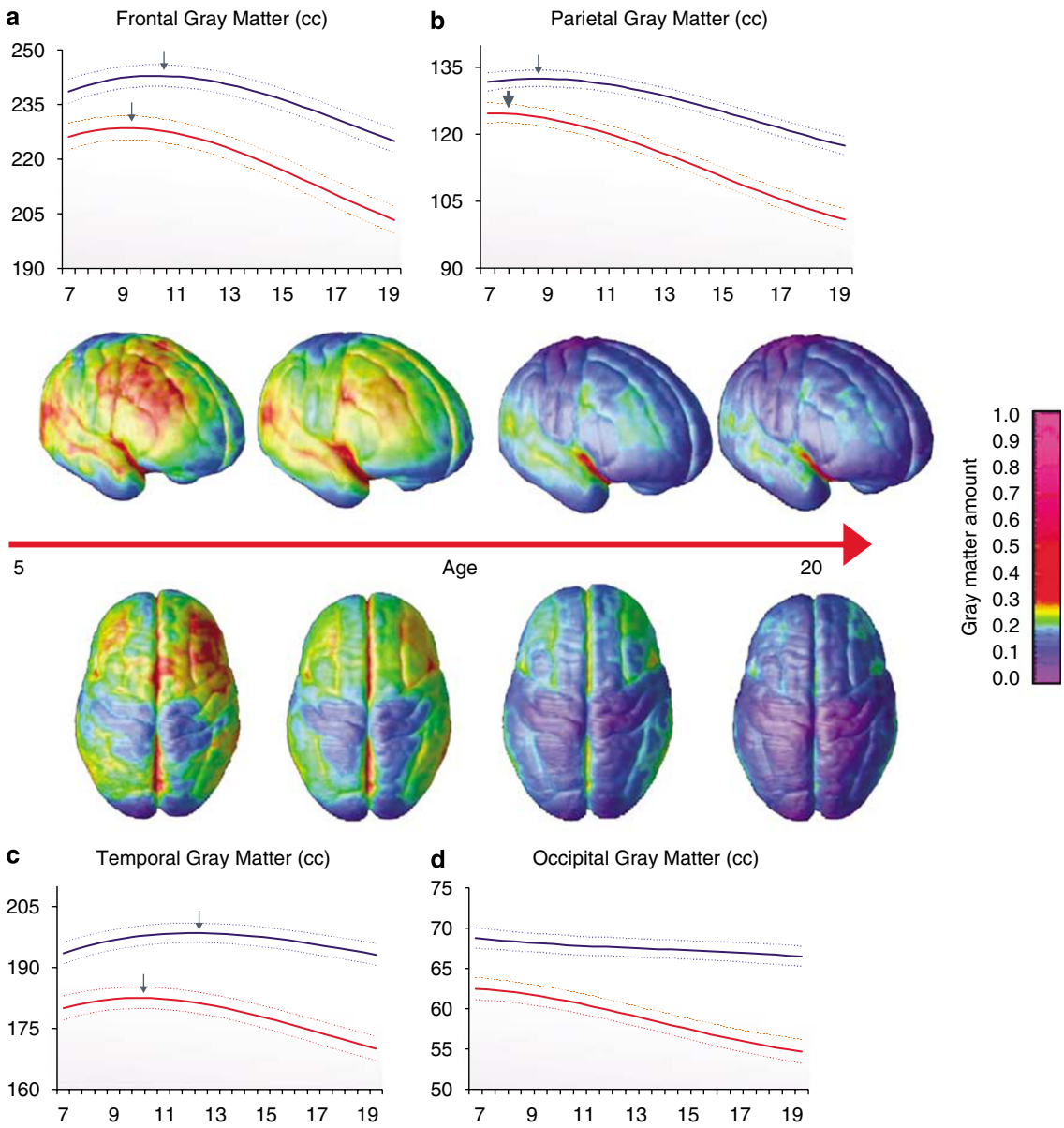

Figure 1 Cortical GM development in healthy children between ages 4 and 22. Right lateral and top views of the dynamic sequences of cortical GM maturation in healthy children ages 4–22 ($n = 13$; 54 scans; upper panel) rescanned every two years. Scale bar shows GM amount at each of the 65,536 cortical points across the entire cortex represented using a color scale (red to pink: more GM; blue: GM Loss). Cortical GM maturation appears to progress in a 'back-to-front' (parietotemporal) manner (Gogtay *et al*, 2004). The graphs show total lobar volumes of frontal, parietal, temporal, and occipital lobes in men (blue) and women (red) healthy children between ages 7 and 20. Arrows indicate peak GM volume for each curve and dotted lines represent confidence intervals. Adapted from Giedd *et al* (1999).

males, particularly for frontal, parietal, and temporal regions (see Figure 1).

The region specific variation in GM maturation was highlighted further in a recent study where, using a novel surface pattern matching method, GM development was mapped in spatio-temporal detail from age 4 to 21 years (Gogtay *et al*, 2004). Developmentally essential areas such as primary motor and sensory cortices, or primary visual fields mature at the earlier ages, whereas brain regions which subserve more complex functions (and hence require more intrinsic and extrinsic inputs) such as the association cortices (eg, the dorsolateral prefrontal cortex or superior temporal sulcus) mature at much later ages. Within the prefrontal cortex, however, the orbitofrontal (followed by ventrolateral prefrontal) cortex appears to mature at the earliest, showing functional maturation at the of age 3 years (Crone *et al*, 2006; Bunge and Wright, 2007). These observations show that structural brain development parallels functional milestones in the brain representing a complex interplay between programmed development and environmental inputs.

The parallels between the GM trajectories and those for regional synaptic counts in postmortem brains have led to the speculation that these trajectories are driven by synaptic over production and pruning (Sowell *et al*, 2003), as had been suggested earlier by the parallel age-related changes in sleep physiology and EEG coherence studies (Feinberg, 1982; Feinberg *et al*, 2006; Whitford *et al*, 2007). During

adolescence, the amount of deep sleep and the rate of brain metabolism fall sharply. Feinberg speculated that the reported fall in synaptic density seen in the postmortem studies might have relationship with the sleep patterns. Whether the best correlates will prove to be neuronal size, dendritic or axonal arborization, or vascular or glial changes will have to be answered by parallel primate imaging and cellular studies. Such studies should have high priority given their likely relevance to clinical outcome and resilience as discussed further in the section on schizophrenia below.

More focused studies dealing with changes within a relatively short time period, and examining nonlinear changes have extended the earlier studies of Giedd *et al* (1999) and documented regional brain maturation in relation to cognitive development. In an important study, Sowell and co-workers examined the relationship between GM development in the left inferior frontal gyrus (Brodmann's areas (BA) 6, 44, and 45) with maturation of a linguistic skill (Sowell *et al*, 2004; Lu *et al*, 2007). Forty-five children between ages of 5 and 11 years were scanned twice across a 2 year interval. Two tests of auditory processing were used; in addition, motor ability was assessed with the Purdue Pegboard Test of fine motor dexterity. As predicted, gray matter thickening in the left inferior frontal cortex (areas 6 and 44) was associated with improving phonological processing scores, but not with improving hand motor skills. In contrast, motor skill improvement was associated with thinning in the hand region of the left motor cortex (BA 4; an area that showed age-related thinning in the previous longitudinal study) and cortical change in this region was not associated with phonological processing. This specific correspondence between regional gray mater thickness change and language skill acquisition could only be identified with prospective studies because of the large individual variability in anatomy and maturational rate. Moreover, area 45 did not correlate significantly with the phonological processing measures, perhaps because this region is associated more selectively with syntactic processing (Bookheimer, 2002). As with all imaging studies, it is not known whether these regional GM changes are driven by synaptic/dendritic loss or proliferation, or other vascular or glial changes. The double dissociation found within this study, however, is particularly impressive and the regional cortical change (both thinning and thickening) was seen across only a 2-year time period.

A related study used a novel strategy to look at patterns of correlated age-related cortical thickness for 292 normal children and adolescents (Lerch *et al*, 2006). The question was whether thickness of one area of the cortex changed in a statistically correlated fashion with changes in thickness of other cortical regions. Taking BA44, a language processing area that has shown age-dependent connectivity patterns, as a 'seed region', the correlation maps were strikingly similar to tractography maps from DTI, with association areas showing the highest correlational strength and the correlations for BA44 changing with age with older subjects featuring tighter correlations with BA44 in the anterior portions of the superior temporal gyri. Furthermore, steeper correlations between BA44 and multiple frontal and parietal regions and anterior cingulate (highest) were found for higher IQ group, within this healthy population (Lerch *et al*, 2006). This association of the ACC, parietal, and lateral frontal cortex may reflect the role of these regions, as these regions have been implicated in the allocation of attention resources, planning, and cognitive control which are core facets of intelligence (Haier *et al*, 2004; Toga and Thompson, 2005).

GENETICS OF NORMAL BRAIN DEVELOPMENT

Imaging studies of adult twins have found a strong genetic influence on total cerebral volume and lobar gray and white matter volumes (Baare *et al*, 2001). An ongoing study of healthy MZ ($n = 90$) and DZ ($n = 38$) same sex twins confirmed high heritability (0.77–0.88) for nearly all brain regions (Wallace *et al*, 2006), but a surprising yet notable exception was the cerebellum with additive genetic effect of 0.49 (Dr Jay Giedd, unpublished data). This observation fits with several preclinical studies suggesting particular plasticity for the cerebellum (Floeter and Greenough, 1979; Boyden *et al*, 2004; Dong and Greenough, 2004) and adds interest to the findings of abnormal cerebellar development in ADHD described below.

Most developmental genes are expressed differentially across brain regions and age (Redmond *et al*, 2003). An adoption study showed that adoptee cognitive patterns are related to that of their biological, rather than adoptive parents across childhood and adolescence (Plomin *et al*, 1997).

Cross-sectional analyses from recent singleton, sibling, and twin data ($n = 600$ subjects, ages 5–19) also indicate some evidence of age-related alterations in regional anatomic brain heritability. Significant age by heritability interactions were observed with gray matter volumes showing a reduction in heritability with increasing age, whereas white matter volume heritability increased with greater age (Wallace *et al*, 2006). Subregional analyses of these data indicate a pattern in which cortical thickness of the regions involved in complex cognitive processes such as language, tool use, and executive functions shows strong environmental influences in childhood, but become increasingly genetically determined during adolescence. This was most marked for the dorsolateral prefrontal cortex, superior parietal cortex, and temporal cortex. Language-related regions in the left hemisphere including Brocas and Wernicke's areas showed greater increases in heritability than the corresponding regions on the right side. Conversely, heritability of cortical thickness within primary motor and somatosensory cortices decreases with age, being higher in subjects 5–11 years than in 12–19 years (Lenroot *et al*, submitted). Thus, the genetic and environmental factors seem to affect cortical development in both regional and age-specific manner. Longitudinal pediatric twin studies are underway by this group to further refine these regional findings.

COGNITIVE FUNCTIONS AND BRAIN DEVELOPMENT

Localization of complex cognitive functions (eg, executive functions) is relatively less precise and may be represented

in multiple brain regions with additional individual differences in cortical processing and notably large areas of activation are different across subjects doing the same task, suggesting that different cortical regions may be enlisted for the processing of the same task (Derbyshire *et al*, 1998). For example, the existence of multiple circuits involved in attentional tasks is supported by evidence from fMRI studies (Posner and Petersen, 1990; Posner and Dehaene, 1994). For example, executive functions such as planning, problem solving, working memory are thought to be represented in the prefrontal cortex based on recent fMRI and PET studies (Smith and Jonides, 1999), whereas posterior attentional system is subserved by the right parietal lobe which may not develop fully until adult years (Konrad *et al*, 2005). Thus, a developmental perspective on brain-cognition relationships is particularly important as age-specific patterns would be anticipated.

IQ AND NORMAL CORTICAL DEVELOPMENT

The existence of a general factor of intelligence suggests an overarching principle of brain development associated with intellectual level that extends beyond the specific connectivity of any particular cognitive ability and is consistent with a model of neural plasticity (Garlick, 2002). Garlick (2002) argued that the connectionist model for neural systems implies that the development of differentiated neuronal connections would have to be characterized by some ability to respond rapidly and appropriately to any phenomenon with which it (the nervous system) is presented.

The availability of a large cohort of children studied longitudinally across childhood and adolescence enabled the examination of regional cortical trajectories in relation to IQ. Recently, Shaw *et al* (2006a) examined the NIMH pediatric longitudinal data set for anatomic brain development in relation to IQ. Developmental trajectories for total and regional brain cortical thickness were examined in relation to IQ (measured at time of initial scan) for 307 children (the majority of whom has prospective repeated neuroanatomic scans) ages 4–26 years as shown in Figure 2. At younger ages, the relationship between cortical thickness and IQ was relatively diffuse, but approached the more circumscribed regional frontal lobe 'hot spots' in later adolescence. This established the development of increasingly specific neural connectivity with age. The contrast in trajectories across IQ groups, however, was particularly interesting. As speculated by Garlick (2002), more intelligent children demonstrated a particularly plastic cortex with an initial accelerated and prolonged phase of cortical increase followed by a particularly vigorous phase of cortical thinning.

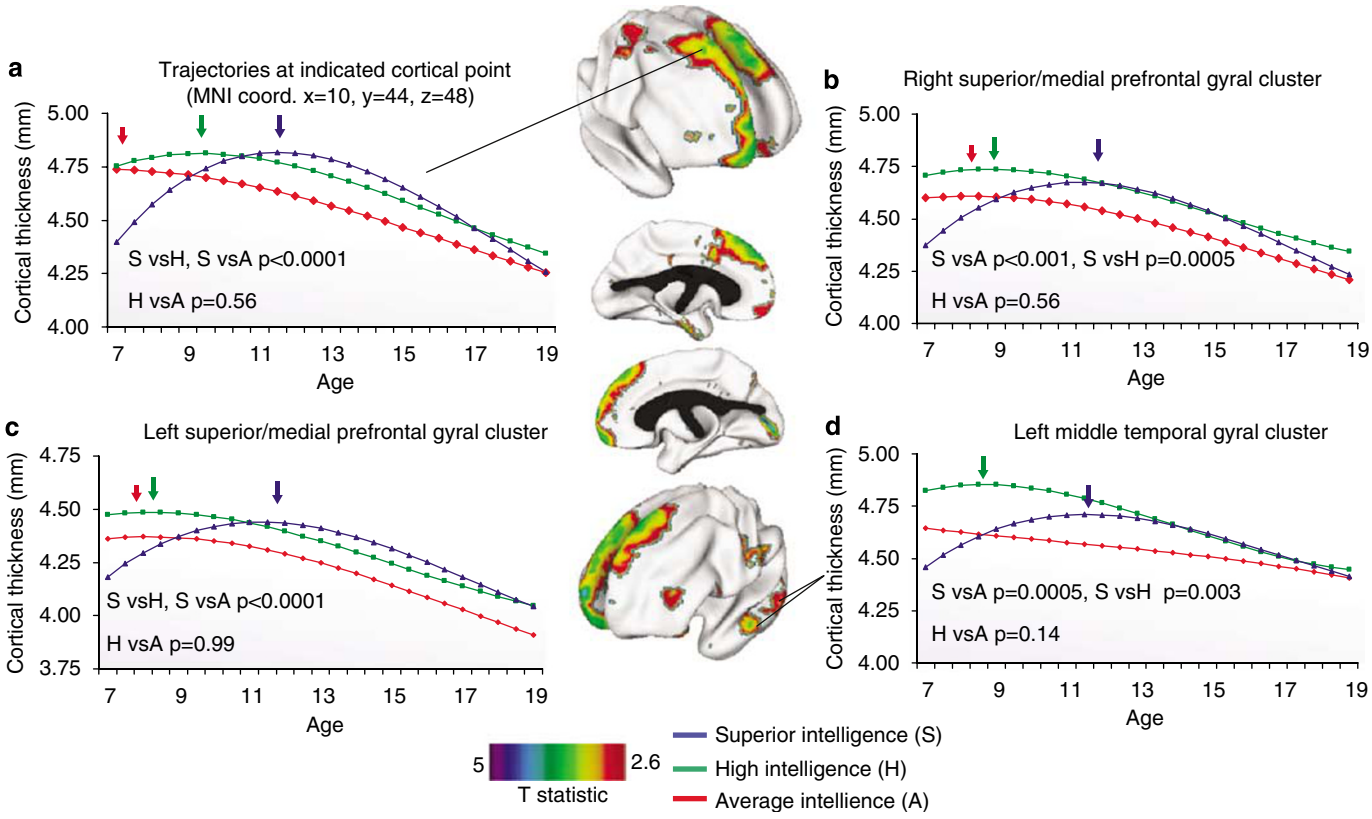

Figure 2 Trajectories of cortical change in children with superior ($n = 91$), high ($n = 101$), and average ($n = 115$) intelligence (total 629 scans). The brain maps (center panel) show prominent clusters where the superior and average intelligence groups differ significantly in the trajectories of cortical development (*t*-statistic maps show areas of significant interaction between these IQ groups and the cubic age term). (a) Graph showing the trajectories at the cortical point of maximum trajectory difference in the right superior frontal gyrus (point indicated in upper brain map). (b–d) Graphs showing the trajectories of the mean thickness of all cortical points in the other clusters. The graph in (d) relates to the area indicated in the lower brain map. The age of peak cortical thickness is arrowed and significance values of differences in shapes of trajectories are given on the graphs. Adapted from Shaw *et al* (2006a).

The implications of these findings are for a general model of neural plasticity underlying IQ. It would seem that the 'sensitive period' is shifted to a somewhat later period for the highest IQ population. This, somewhat counterintuitive finding is not only compatible with both different genetic determination, but also allowing for somewhat more complex experiential input during a period of great synaptic and other change (Knudsen, 2004). In addition, the steeper slope of both increase and decrease in cortical thickness for the highest IQ group suggests that these individuals share a more dynamic pattern of plasticity. Future functional studies should pursue other temporal response patterns in very high IQ individuals.

CHILDHOOD-ONSET SCHIZOPHRENIA

It is now accepted that schizophrenia is associated with structural brain abnormalities, with the most consistent findings being enlarged lateral ventricles and reduced temporal (medial and superior) and prefrontal GM volumes (Lawrie and Abukmeil, 1998). Early studies including animal models (Lipska *et al*, 1993) and cohort studies suggested an early, fixed 'lesion' and thus suggesting the 'neurodevelopmental' model for schizophrenia (Weinberger, 1987; Rapoport *et al*, 2005). This model, however, has come under increasing scrutiny as more recent series of longitudinal studies, both in adults and early-onset populations have demonstrated progressive gray matter loss starting with the earliest phase of the illness (Bridle *et al*, 2002; Mathalon *et al*, 2003; Pantelis *et al*, 2005). Although it is still possible that an early fixed lesion could manifest later on in life, the temporally dynamic pattern of the illness along with progression of structural brain abnormalities would also support a model of schizophrenia as a progressive neurodevelopmental disorder (Woods, 1998). Similarly, many of the schizophrenia genes associated with the illness appear to have functional roles throughout the lifespan and thus for a complex genetic disorder like schizophrenia, it is possible to imagine an ongoing interplay of genetic, epistatic, and the environmental factors (Harrison and Weinberger, 2005; Rapoport *et al*, 2005).

Postmortem studies show no widespread neuronal loss in schizophrenia, or a glial response to a potential neuronal injury. The cortical GM loss observed in schizophrenia has been shown to be due to the loss of 'neuropil' which consists of glia, synaptic, and dendritic arbors and vasculature (Selemon and Goldman-Rakic, 1999). These observations have lead investigators to revisit Feinberg's (1982) 'excessive pruning hypothesis' where a (genetically or environmentally based) fault in programmed synaptic elimination during adolescence could lead to neuropathology of schizophrenia (Feinberg, 1982). Neurophysiologic and functional neuroimaging studies also suggest abnormal synaptic activity and disrupted functional connectivity in schizophrenia (Volkow *et al*, 1988; Weinberger *et al*, 1992; Friston, 1999, 2005), supporting a general model in which structural or functional synaptic abnormalities could be the core deficit of schizophrenia and highlighting the role of synaptic plasticity in this disease (Frost *et al*, 2004; Friston, 2005). A greater understanding of the cellular correlates of the gray matter change remains crucial for the advocates of the 'excessive pruning hypothesis'.

Although the studies of COS below represent a rare opportunity to examine the interaction of the illness with early brain development, there is abundant evidence of much earlier prepsychotic brain developmental abnormalities than our age 8 onwards imaging data can reveal. For example, delayed or impaired development across a wide sphere of behaviors and abilities is seen in the childhood of adult patients with schizophrenia (Cannon *et al*, 2003; Maki *et al*, 2005; Ridler *et al*, 2006), and our very early-onset COS patients also show clinical evidence of early abnormalities in brain development with more frequent language (43%) and learning problems (65%), years before onset of psychosis (Alaghband-Rad *et al*, 1995). Forty-three percent of the COS had an anxiety disorder at initial screening, perhaps indicating a phenotype with prominent GABAergic abnormalities (Hensch, 2004; Mohler *et al*, 2004).

PATTERN AND SPECIFICITY OF GM FINDINGS

Earlier studies using whole-lobe volume measures had shown profound and global GM loss with ventricular expansion in COS (Rapoport *et al*, 1997, 1999; Rapoport and Inoff-Germain, 2000). Subsequent longitudinal analysis using finer brain mapping techniques showed that the GM loss in COS progressed in a characteristic back-to-front (parieto-frontal -temporal) direction during adolescent years (Thompson *et al*, 2001). This is strikingly similar to the pattern of GM loss (maturation) seen during normal cortical development (Gogtay *et al*, 2004). Taken together, the cortical GM loss in COS appears to be an exaggerated pattern of the normal brain development and could reflect the lack of normal controls on synaptic pruning (Schoop *et al*, 1997; Sowell *et al*, 2001).

The diagnostic specificity of these GM trajectories was established by comparing them with a longitudinally scanned group of children with atypical psychosis with similar initial presentation, but ruled out to have schizophrenia after an extensive evaluation including complete medication washout (Kumra *et al*, 1998). At 2–10 years follow-up, none of these children had converted to meeting diagnostic criteria for schizophrenia, but a surprising 40% of them became bipolar I. The developmental trajectories for these children show a subtle but very distinct pattern of cortical GM gain in left temporal cortex and GM loss in right temporal and subgenual cingulate cortices, a pattern that has no overlap with the pattern seen for COS (Gogtay *et al*, 2007b). As seen in Figure 3, these observations, which establish the diagnostic specificity of the GM findings, also suggest that the GM changes are unlikely to be influenced by medications as the bipolar group had been treated with similar medications (Gogtay *et al*, 2004). The familial/genetic nature of these observations is further supported studies of healthy siblings discussed below.

LONG-TERM COURSE OF GM CHANGES

Studies on neurobiological risk factors suggested support the continuity of COS with the adult-onset illness (Nicolson and Rapoport, 1999; Nicolson *et al*, 2000). Thus it would be expected that the GM changes would eventually evolve into

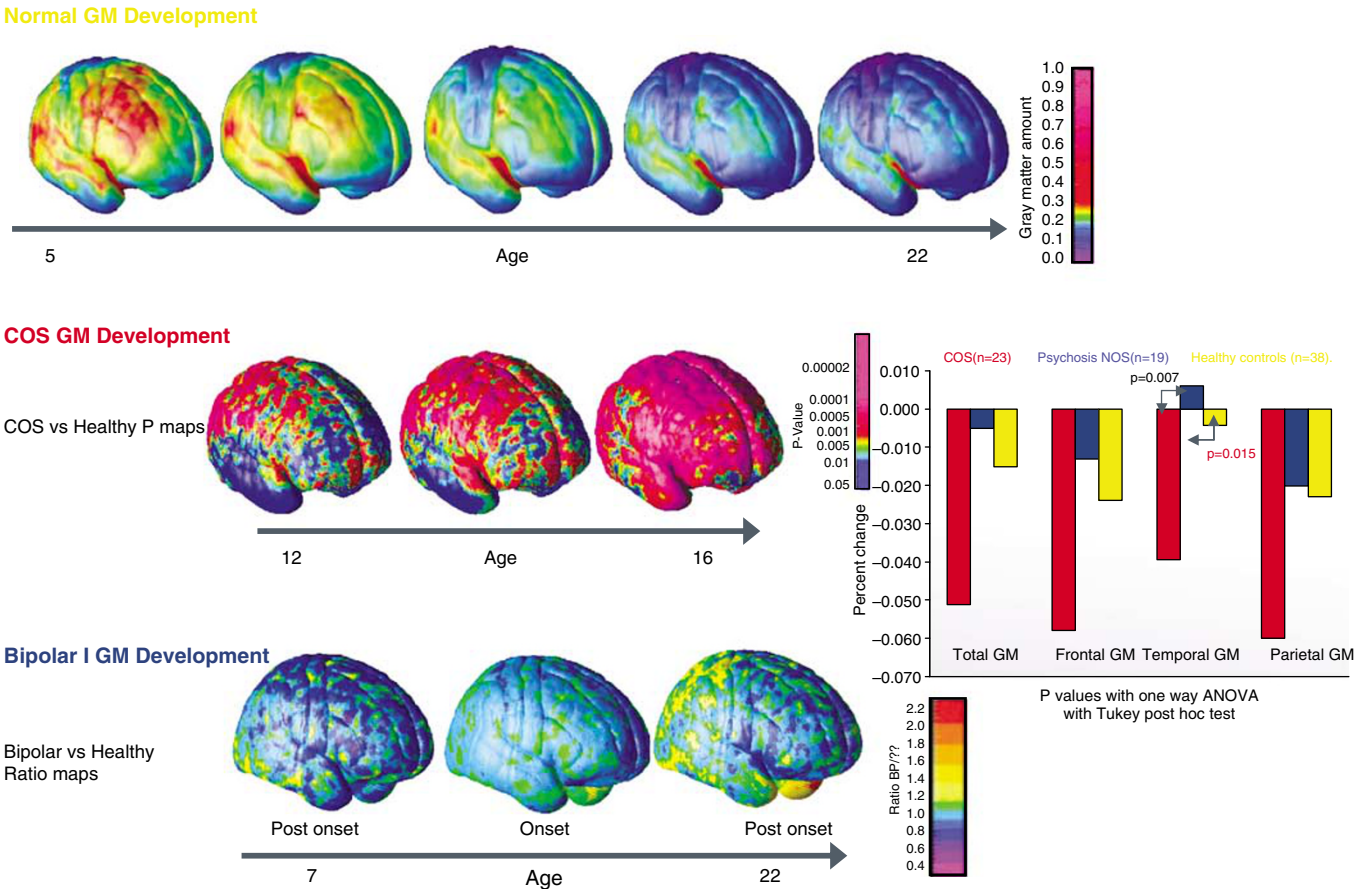

Figure 3 Comparison and specificity of GM developmental patterns in healthy, COS, and Bipolar children. Top panel shows right lateral views of dynamic sequences of cortical GM maturation in 13 healthy children between ages 4 and 22 as was displayed in Figure 1. The GM maturation (blue color) proceeds in parietofrontal-temporal direction (Gogtay *et al*, 2004). The middle panel shows dynamic sequence of significant GM loss (p-maps) in 12 prospectively scanned COS children compared to matched healthy controls between ages 12 and 16. The pattern of GM loss in COS appears to be an exaggeration of the normal GM maturation (Thompson *et al*, 2001). The bottom panel shows dynamic sequence of comparison of the GM amount (ratio maps) between nine psychotic bipolar I children and their 18 matched controls before and after onset of mania. There is no overlap of GM developmental pattern between COS and bipolar GM development establishing the diagnostic specificity of the findings (Gogtay *et al*, 2007b). The graph shows three way comparison of change in GM amount over 2-year period in COS (red bars), psychosis NOS (blue bars), and healthy controls (yellow bars). Psychosis NOS children had similar medications and treatment history as COS children at the time of initial scans. Thus GM changes seen COS are unlikely to be related to drug exposure (Gogtay *et al*, 2004).

a pattern similar to that seen in the adult-onset illness. Adult-onset studies using VBM or cortical thickness mapping methods, show predominant cortical GM loss in prefrontal and superior temporal cortices (Kuperberg *et al*, 2003; White *et al*, 2003; Wiegand *et al*, 2004; Narr *et al*, 2005). In a recent analyses on a group of 70 COS children followed from ages 8 to 28 years, the pattern of GM loss indeed became more circumscribed to the prefrontal and superior temporal cortices by age 26 years, further supporting the continuity with the adult-onset disorder (Greenstein *et al*, 2006).

GM LOSS OR WM ENCROACHMENT?

The brain MRI studies showing GM loss have raised the question whether the cortical GM loss is just a perceived loss resulting from the encroachment by continued white matter myelination, a process which normally is extended through the 4th decade (Benes, 1993; Benes *et al*, 1994; Sowell *et al*, 1999). A recent analysis using whole-lobe WM volumes on 70 COS children (ages 7–26 years) with prospective rescans ($n = 162$ scans) showed that the slope for WM growth was significantly lower in COS children compared to matched healthy controls in all lobes ($P < 0.05$), indicating that the GM reduction in COS is not secondary to WM encroachment (Dr N Gogtay, unpublished data). We are currently applying the novel tensor-based mapping technique to create dynamic maps of WM growth for these subjects.

CLINICAL REMISSION AND CORTICAL THICKNESS

The cortical GM thickness of COS children who met the criteria for clinical remission ($n = 16$) at the time of their discharge from the NIMH typically 3–4 months after the initial scan (mean duration 104.8 ± 25.4 days), was thicker in prefrontal, temporal as well as parietal cortices for the remitted children than for those COS children who did not meet the remission criteria ($n = 40$) (Greenstein *et al*,

submitted). Thicker cortex could reflect a general protective process seen in both probands and healthy COS siblings as described below.

HEALTHY COS SIBLINGS

GM abnormalities in schizophrenia are at least in part familial/trait markers (Weinberger and McClure, 2002; Cannon *et al*, 2003; Gilbert *et al*, 2003; Yucel *et al*, 2003). Most studies of high-risk populations, typically close relatives of schizophrenia patients, show smaller total and regional GM volumes (Cannon *et al*, 2002a, b; Job *et al*, 2005; McIntosh *et al*, 2006), total white matter volumes (Narr *et al*, 2002; Hulshoff Pol *et al*, 2004), reduced GM volumes of thalamus (Staal *et al*, 1998) and/or hippocampal-amygdalar complex (Lawrie *et al*, 2001; Cannon *et al*, 2002; Keshavan *et al*, 2002; Seidman *et al*, 2002; Van Erp *et al*, 2002), although inconsistencies remain across the studies (Boos *et al*, in Press; Marcelis *et al*, 2003; McDonald *et al*, 2006).

Longitudinal brain MRI studies on healthy COS siblings provide further insights into the phenomenon of cortical GM changes. Because of the striking progression of GM deficits in COS probands, their full siblings (age 8 to 28 years) were also followed prospectively (Gogtay *et al*, 2007a). For this analysis, siblings were chosen with minor psychopathology and any 'schizophrenia spectrum' disorder either on Axis I or Axis II was exclusionary. Longitudinal GM development of 52 healthy COS full siblings showed these siblings to have initial GM loss which, for this group, did not progress during adolescence (unlike their COS probands), but in fact normalized by age 20. The early GM loss in siblings was most prominent in the prefrontal and temporal cortices (see Figure 4) as has been seen for COS probands, but unlike that seen in probands, siblings did not show parietal GM loss in younger ages (Gogtay *et al*, 2007a). The age-related amelioration of deficits did follow a somewhat similar pattern in both probands and siblings. This apparent 'plastic' response (inhibition of cortical thinning) in healthy siblings is intriguing and warrants replication. Within the healthy sibling group, regional cortical thickness increased with increase in overall 'life functioning' as measured by the Global Assessment Scale (GAS), which suggests a direct relationship between cortical thickness and restitutive normalization process with general competence (GAS scores). Furthermore, mean cortical thickness (MCT) at initial scan positively correlated with the most current GAS scores and was not significantly related to the IQ. In other words, better social and cognitive 'competence' was predicted by initial cortical thickness. Whether this relationship between GM thickness and GAS reflects cause, or is secondary to both having a common antecedent remains unknown.

GENETICS AND COS BRAIN DEVELOPMENT

Schizophrenia is a complex genetic disorder with many genes of small effect thought to be etiologic for most patients and likely modified by other genetic, epigenetic, and environmental factors (Harrison and Weinberger, 2005). Recent advances in neuroimaging may allow stronger and more biologically meaningful associations between

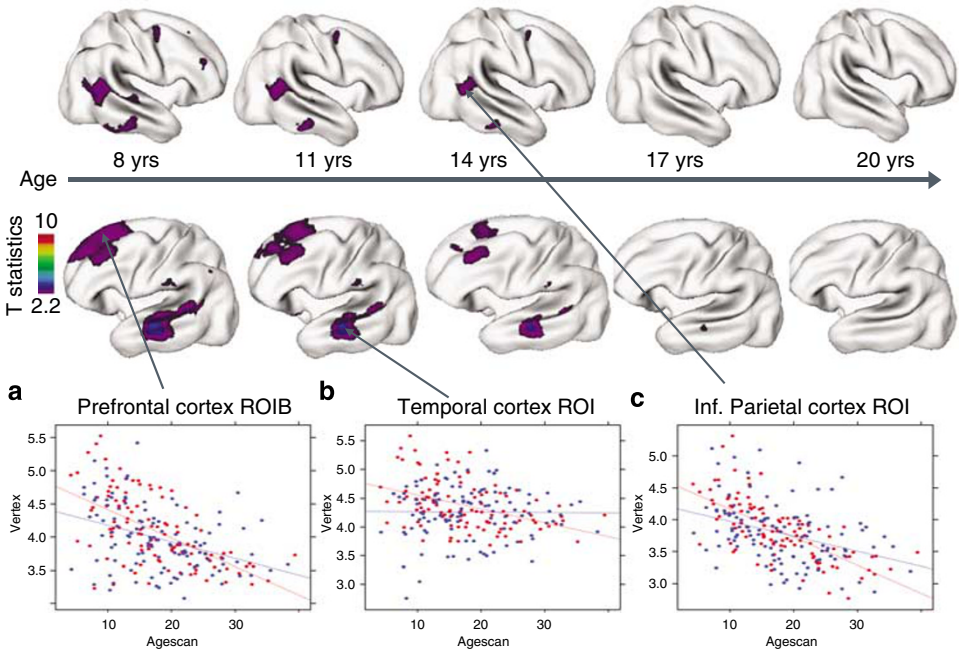

Figure 4 Early Cortical GM loss in healthy COS siblings normalizes by age 20. Cortical GM thickness in healthy COS siblings ($n = 52$; 110 scans) compared to age, sex, and scan interval matched healthy controls ($n = 52$; 108 scans) between ages 8 and 28. Healthy COS siblings show significant GM deficits left prefrontal and bilateral temporal cortices and smaller deficits in right prefrontal and inferior parietal cortices. These deficits in healthy siblings normalize with age with no abnormalities remaining by age 20. Side bar shows *t*-statistic with threshold to control for multiple comparisons using the false discovery rate (FDR) procedure with $q = 0.05$; significant at $t = 2.2$. The graphs (a–c) show trajectories of GM development in healthy COS siblings (Blue) and those for matched healthy controls (red) in select regions of interest. Adapted from Gogtay *et al* (2007a).

potential risk alleles and intermediate phenotypes such as morphological brain abnormalities (Meyer-Lindenberg and Weinberger, 2006). The assumption is that the effect size of risk allele association will be greater for a brain imaging measure (or other intermediate phenotype) than that with the diagnosis (Flint and Munafo, 2007). Many of the susceptibility genes reported for schizophrenia appear to have an impact on the synaptic molecular biology (Harrison and Owen, 2003; Harrison and Weinberger, 2005), thus associations between specific risk alleles and brain morphological changes could provide further insights into genetic influences on synaptic plasticity. For example, our recent analyses using cortical thickness measures show that both COS probands and healthy siblings with GAD risk allele, a modulator enzyme that converts glutamate to GABA which has an inhibitory influence on the downstream prefrontal pyramidal neurons (Coyle, 2004), have steeper slopes of cortical GM loss in prefrontal cortex. Thus, GAD risk status may influence synaptic/dendritic plasticity in prefrontal cortex (Dr N Gogtay unpublished data); possibly through various mechanisms such as, glutamatergic overdrive resulting in excitotoxicity due to reduced GABA inhibition, reduced synaptic protein synthesis due to simultaneous reduction of reelin expression (Fatemi *et al*, 2000), or calcium channel abnormalities in GABA interneuron described earlier. Although it is difficult to calculate the effect size for the brain morphological findings obtained using mixed model regression analyses, it is hoped that these observations will enhance the understanding of gene effects on brain morphology. It would be worth exploring the association of other risk genes involved either in glutamate/NMDA (eg, dysbindin, mGlu3) or GABA circuitries (eg, Reelin, Parvalbumin) (Fatemi *et al*, 2005; Gisabella *et al*, 2005; Stephan *et al*, 2006) and their relationship to developmental trajectories.

ADHD

ADHD is a common childhood disorder characterized by developmentally inappropriate levels of inattention, impulsivity, and motor restlessness. Although these are usually seen as the core deficits, other factors such as response preparation and control and reward processes are also altered. Approximately half of most ADHD populations have a benign outcome, although controversy remains as to rate of complete remission (Klein, 1987).

Brain anatomic studies of ADHD have confirmed longstanding indirect evidence that suggested subtle abnormalities of subcortical and regional cortical volumes in regions related to executive functions. Most prominently cortical thinning is seen in medial and superior prefrontal and precentral regions (Casey and Durston, 2006; Mackie *et al*, 2007; Shaw *et al*, 2006b). These findings of cortical thinning were also recently replicated in a study of 24 Adult ADHD subjects who had continuous disorder into adult years compared to 18 healthy controls (Makris *et al*, 2007). Unfortunately, this study did not include adults whose childhood ADHD had remitted, which may have provided replication of the Shaw *et al* provocative outcome finding.

STIMULANT DRUGS AND BRAIN DEVELOPMENT

In understanding the brain abnormalities of ADHD, the studies of the effects of stimulant drug exposure cited above on rat brain development might suggest that any brain abnormalities found for ADHD might be stimulant induced. This does not appear to be the case. Castellanos *et al* (2002) found no significant effects of stimulant drug for a large cohort of ADHD children and in Shaw's study the good and poor outcome subjects had virtually equivalent stimulant drug exposure. As observed by Hyman (Hyman, 2003), it is not only the pharmacologic agents that regulate gene expression in neurons and alter neural circuits; but also mental illness and experience do so as well and preclinical studies so far have not proved useful for informing human studies.

BRAIN IMAGING AND PLASTICITY IN ADHD

A unique recent study examined data from prospective anatomic brain images using a measure of total and regional cortical thickness for 163 children with ADHD, 97 of who had two or more images along with clinical evaluations at each scan point (Lerch *et al*, 2006; Shaw *et al*, 2006b). These prospective data enabled regional thickness trajectories to be examined, using mixed model regression analyses, in relation to both diagnosis and (within diagnostic group) to clinical outcome. Trajectories of cortical thickness differed significantly for the ADHD group in the right parietal cortex, an area known be important for attentional control. In the ADHD group, the age-related thinning in this region appeared to be slowed resulting in a relatively spared regional thickness (See Figure 5).

A second analysis addressed the question of whether regional cortical development differed between good and pure outcome ADHD groups (defined as both a continuous and dichotomous measure). The 'normalization' of right posterior parietal cortical thickness was driven by the better outcome children and this finding could not be ascribed to medication exposure which was virtually identical for good and poor outcome groups. Further analyses showed that the good outcome cases exhibited compensatory right parietal 'slowing' of the normal decline, most plausibly activity driven. This interpretation is also supported by functional studies indicating that ADHD children have excess activation in this posterior parietal region (Rubia *et al*, 2000; Durston *et al*, 2003). Moreover, activation of the right parietal cortex during tasks of alerting and reorienting of attention is not fully mature until adulthood, and this component of the attentional network may develop during adolescence (Konrad *et al*, 2005), and there is also evidence of training-induced plasticity for activation at this site (Olesen *et al*, 2004).

Recent studies show a uniquely delayed pattern of cortical development for ADHD children with good outcome. Utilizing a program which maps the age of maximal cortical thickness across childhood and adolescence, quadratic curves of cortical development were established using a large number of subjects with multiple scans and mixed model regression analyses. A back to front 'wave' of cortical

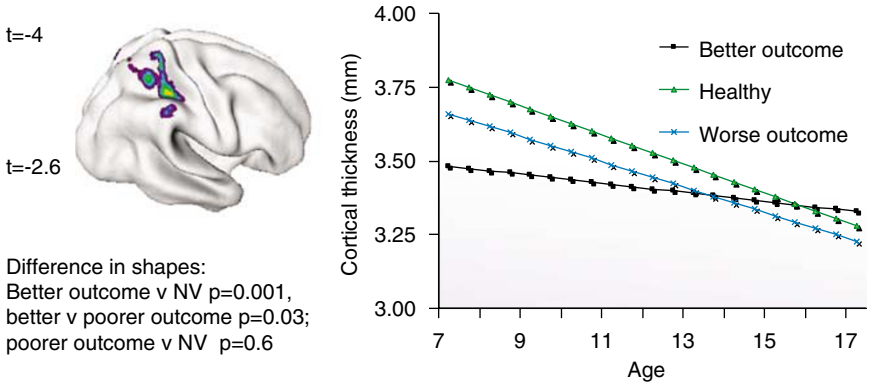

Figure 5 Normalization of Right parietal cortex and better outcome in ADHD. The *t* map indicates vertices where there was a significant interaction in the regional trajectory slopes between the better outcome and healthy control groups. The graph illustrates group trajectories in this region (difference in gradients: better outcome group *vs* controls, $P=0.001$; better *vs* worse outcome groups, $P=0.03$; and worse outcome group *vs* controls, $P=0.60$). Adapted from Shaw *et al* (2006b).

development is seen for both populations, but the GM peaks in ADHD subjects were about 3 years later than in the healthy controls (Dr P Shaw, submitted).

The cerebellum has been of increasing interest in the pathogenesis of ADHD. Dopaminergic innervation appears early in cerebellar development and there is widespread immunoreactivity for various dopamine receptors on the dendritic arbors of the Purkinje as well as granule cells (Yew *et al*, 1995; Khan *et al*, 1998, 2000; Ishibashi *et al*, 2002). Structural abnormalities are one of the most consistently reported features with reductions in overall volume particularly in the cerebellar vermis which has the highest concentration of dopaminergic innervation (Melchitzky and Lewis, 2000; Hurley *et al*, 2003). Although traditionally considered a site of motor control; lesion studies and functional imaging studies involving the cerebellum have demonstrated deficits in a wide range of cognitive and affective functioning (Schmahmann, 2004). A longitudinal case–control study of ADHD patients and matched controls included cerebellar measures for six lobes of the cerebellar hemispheres, and three vermal subdivisions both acquired at baseline and two or more follow-up time points at 2 years intervals. The results showed a loss of superior cerebellar vermis volume in the ADHD group which persisted at 5-year follow-up regardless of clinical outcome. However, in the cerebellar hemispheres, ADHD subjects with a worse clinical outcome displayed a downward trajectory in the inferior posterior lobes which became progressively small during adolescence relative to both healthy controls and ADHD subjects with a better outcome (Mackie *et al*, 2007).

Thus, the cerebellar hemispheres, like the right parietal region may show a plastic, state-specific response and possibly be targets for clinical intervention in ADHD. Given the relatively higher rate of environmental effects on these cerebellar volumes discussed above (Wallace *et al*, 2006), if these findings are replicated, compensatory training should be considered, although to date such approaches have not been encouraging (Klingberg *et al*, 2005). Alternately, genetic causes of subtle progressive decline in cerebellar volumes should be explored. Finally, the specificity of these findings needs to be documented. To date, we know that these patterns do not resemble those for age matched psychotic adolescents; differentiation from other neurodevelopmental disorders including specific learning disabilities remains to be demonstrated.

RISK GENES AND ADHD BRAIN DEVELOPMENT

ADHD is one of the most heritable neuropsychiatric disorders (Levy *et al*, 1997; Faraone, 2000). Limited twin-brain imaging data suggest that discordant MZ twins often represent lesion based phenocopies in the ill twin (Levy *et al*, 1997; Castellanos *et al*, 2003). Several candidate risk genes have been replicated for ADHD among them, the 7-repeat polymorphism within the D4 receptor gene. In spite of small diagnostic effect size, there have been some reports of risk gene association with brain volume. Using the longitudinal cohort study, Shaw *et al* found that the DRD4 7-repeat allele was associated with a thinner prefrontal and posterior parietal cortex overlapping with the generally thinner regions in ADHD subjects studied prospectively as described above. However, the 7-repeat group of subjects showed greater normalization of the right parietal cortical region, a pattern previously linked with better clinical outcome (Shaw *et al*, 2007). Thus, the neuroanatomic correlates of the DRD4 7-repeat were limited to subjects at younger ages (there were no significant effects of DRD1 or DAT1 polymorphisms on clinical outcome or cortical development) (Shaw *et al*, 2007). This finding remains controversial as some find good outcome with this gene, whereas others do not (Barkley *et al*, 2006). Possession of the 7 repeat allele had the same effect on cortical thickness in ADHD and controls (Shaw *et al*, 2007). There is some evidence for the specificity of the gene effect as Durston and her group have also shown a different effect (on the caudate volume) for DAT1, a gene expressed in the basal ganglia rather than in the cortex (Durston *et al*, 2005). The finding of gene effect on brain volume or trajectory is impressive for several reasons. ADHD is a complex genetic disorder with many risk genes involved each of relatively small effect; a recent meta-analysis shows the pooled Odds Ratio for the D4VNTR 7-repeat to be 1.4 (in family based) and 1.24 (in case–control) studies, and 1.13 (CC) for DAT1 (Faraone *et al*, 2005). The similar relationship of the D4 risk allele to

cortical thickness in both healthy and ADHD brains encourages the use of regional volumes and trajectories as endophenotypes, and is consistent with the dimensional nature of ADHD.

We can only speculate on the mechanisms through which the DRD4 allele may exert structural effects. Cortical changes were concentrated partly in the frontal region which have the highest levels of dopamine D4 receptors (Meador-Woodruff *et al*, 1996). Variants of the receptor have subtle differences in pharmacological binding properties and the 7-repeat allele inhibits cyclic adenosine monophosphate less efficiently, which may denote sensitivity to endogenous dopamine. Studies with antipsychotics (which are D2 receptor family antagonists) may have trophic effects on the cortex through increasing metabolism and ultrastructural change in the dendritic tree and synapse morphology (Konradi and Heckers, 2001; Miller *et al*, 2001). It is thus possible that changes in D4 receptor levels and activity associated with the 7-repeat allele could have trophic effects in part through altering endogenous dopamine levels.

These findings of outcome-related brain developmental trajectories are paralleled by studies on Tourette's syndrome, a disorder, closely related to ADHD; approximately 80% of Tourette's patients greatly improve or remit by the end of adolescence. In recent years, Peterson and co-workers have carried out a series of imaging studies on adolescent and adult patients with Tourette's syndrome. These cross-sectional studies show that both adult and child patient have decreased caudate volume, which may represent a trait marker for this disorder. Functional studies had indicated prefrontal, parietal, and temporal activation during tic suppression for this group. It is intriguing therefore, that prefrontal cortical volumes were uniquely low in the non-remitted adults with TS in comparison with the wide range of volumes seen in the childhood sample—a group ultimately expected to have a large remission rate. The implication from this cross-sectional data is that prefrontal hypertrophy seen in the younger subjects mediates their ultimate remission reflecting a plastic compensatory process. A longitudinal study and one that includes remitted adults is waiting to be undertaken. It is anticipated that remitted subjected will show a greater cortical plastic response.

DISCUSSION AND FUTURE DIRECTIONS

The availability of normative human brain developmental data has provided new developmental and clinical insights. Longitudinal data for human studies counter balance the large individual differences which can obscure the developmental changes. These have also shown the importance of timing of trajectory to the level of functioning within healthy individuals (as shown in the Shaw et at IQ study) and the exaggerated cortical loss in psychotic patients (Thompson *et al*, 2001). Clinical outcome is also related to the mean gray matter thickness in the childhood schizophrenia cohort illustrating the relevance of such measures to core features of the illness (Greenstein *et al*, submitted).

Twin studies indicate high heritability with respect to developmental trajectories (Lenroot *et al*, submitted), and change in regional heritability which may vary across developmental period. The probable plasticity and late maturation of the human cerebellar lobes should be explored in relation to clinical and cognitive status for a variety of disorders following on the data from the ADHD studies, indicating possible plastic brain response in the cerebellar lobes and posterior parietal cortex. It is possible that some children with developmental lag have slower cortical development and longitudinal studies should compare timing of peak volumes in relation to the clinical amelioration.

A major limitation to date has been the lack of parallel information about the cellular changes underlying the developmental anatomic MRI changes discussed throughout this review. The observed changes are almost certainly glial and vascular in nature rather than purely neuronal. This could (and should) be addressed by a parallel developmental primate study in which young monkeys are scanned at regular intervals as appropriate with sacrifice and postmortem brain cellular characteristics obtained.

The bridging between the anatomic measures of compensatory plasticity and regional molecular events remains unknown. The degree to which new utilization of unspecified (labile) synapses and competition for synaptic sites accounts for these changes is unknown. Some hints however may be found in the seminal studies of Hensch (2004), demonstrating the ability to control the timing, duration, and closure of critical periods of brain development in animal models such as by modulating receptors pharmacologically.

The probable heterogeneity and lack of major gene influence in these disorders severely limits understanding to date of signaling pathways underlying these changes. In contrast, for a few developmental cognitive disorders for which major genes have been identified, there have been rapid advances in the identification and characterization of cellular, molecular, and genetic mechanisms important in neuroplasticity and the brain abnormalities of these conditions. Recent work on Neurofibromatosis, Fragile X, Rett syndrome, informally classified as disorders of brain plasticity, and other genetic syndromes with impaired cognitive phenotypes shows how one may move from gene to signaling pathways to putative treatments (Johnston, 2006). Johnston and others provide schema of signaling pathways as they affect transcription and lead to unique treatment trials. For example, based on the anticholesterol drug Lovastatin's ability to inhibit brain MAP kinase, this drug was successfully used to reverse learning deficits in a mouse model of neurofibromatosis (Li *et al*, 2005). New information on molecular contributions to patterning plasticity of brain development is overwhelming (Sur and Rubenstein, 2005; Kriegstein and Parnavelas, 2006), but the combining of these mouse/cellular data with human studies remains critical. This is being tested in the relatively rare neurodevelopmental disorders for which one or more major genes have been identified. This review has also shown the surprising success achieved so far in linking behavioral changes with brain anatomic change. The next need will be to link the gross anatomic developmental trajectories to their underlying cellular/molecular processes. In parallel with clinical studies outlined here, it will be crucial to carry out investigations of molecular changes in synapses during normal development to

gain insight into the mechanism governing structural changes underlying functional plasticity.

DISCLOSURE OF CONFLICT OF INTEREST

Both authors declare that, except for income received from their primary employer, no financial support or compensation has been received from any individual or corporate entity over the past three years for research or professional services and there are no personal financial holdings that could be perceived as constituting a potential conflict of interest.

REFERENCES

Alaghband-Rad J, McKenna K, Gordon CT, Albus KE, Hamburger SD, Rumsey JM *et al* (1995). Childhood-onset schizophrenia: the severity of premorbid course. *J Am Acad Child Adolesc Psychiatry* **34**: 1273–1283.

Andersen SL, Navalta CP (2004). Altering the course of neurodevelopment: a framework for understanding the enduring effects of psychotropic drugs. *Int J Dev Neurosci* **22**: 423–440.

Baare WF, Hulshoff Pol HE, Boomsma DI, Posthuma D, de Geus EJ, Schnack HG *et al* (2001). Quantitative genetic modeling of variation in human brain morphology. *Cereb Cortex* **11**: 816–824.

Barkley RA, Smith KM, Fischer M, Navia B (2006). An examination of the behavioral and neuropsychological correlates of three ADHD candidate gene polymorphisms (DRD4 7+, DBH TaqI A2, and DAT1 40 bp VNTR) in hyperactive and normal children followed to adulthood. *Am J Med Genet B Neuropsychiatr Genet* **141**: 487–498.

Barry MF, Ziff EB (2002). Receptor trafficking and the plasticity of excitatory synapses. *Curr Opin Neurobiol* **12**: 279–286.

Bates E (1993). Comprehension and production in early language development (see comment). *Monogr Soc Res Child Dev* **58**: 222–242; discussion 243–252.

Benes FM (1993). The relationship between structural brain imaging and histopathologic findings in schizophrenia research. *Harv Rev Psychiatry* **1**: 100–109.

Benes FM, Turtle M, Khan Y, Farol P (1994). Myelination of a key relay zone in the hippocampal formation occurs in the human brain during childhood, adolescence, and adulthood. *Arch Gen Psychiatry* **51**: 477–484.

Biederman J, Wilens T, Mick E, Spencer T, Faraone SV (1999). Pharmacotherapy of attention-deficit/hyperactivity disorder reduces risk for substance use disorder. *Pediatrics* **104**: e20.

Bolanos CA, Barrot M, Berton O, Wallace-Black D, Nestler EJ (2003). Methylphenidate treatment during pre- and periadolescence alters behavioral responses to emotional stimuli at adulthood. *Biol Psychiatry* **54**: 1317–1329.

Bookheimer S (2002). Functional MRI of language: new approaches to understanding the cortical organization of semantic processing. *Ann Rev Neurosci* **25**: 151–188.

Boos BM, Aleman A, Cahn W, Hulshoff Pol H, Kahn RS (in Press). Brain volumes in relatives of patients with schizophrenia: a meta-analysis. *Arch Gen Psychiatry* **64**: 297–304.

Bourgeois JP, Goldman-Rakic PS, Rakic P (1994). Synaptogenesis in the prefrontal cortex of rhesus monkeys. *Cereb Cortex* **4**: 78–96.

Bourgeois JP, Rakic P (1993). Changes of synaptic density in the primary visual cortex of the macaque monkey from fetal to adult stage. *J Neurosci* **13**: 2801–2820.

Boyden ES, Katoh A, Raymond JL (2004). Cerebellum-dependent learning: the role of multiple plasticity mechanisms. *Annu Rev Neurosci* **27**: 581–609.

Bridle N, Pantelis C, Wood SJ, Coppola R, Velakoulis D, McStephen M *et al* (2002). Thalamic and caudate volumes in monozygotic twins discordant for schizophrenia. *Aust N Z J Psychiatry* **36**: 347–354.

Bunge SA, Wright SB (2007). Neurodevelopmental changes in working memory and cognitive control. *Curr Opin Neurobiol* **17**: 243–250.

Cannon TD, Thompson PM, van Erp TG, Toga AW, Poutanen VP, Huttunen M *et al* (2002a). Cortex mapping reveals regionally specific patterns of genetic and disease-specific gray-matter deficits in twins discordant for schizophrenia. *Proc Natl Acad Sci USA* **99**: 3228–3233.

Cannon TD, van Erp TG, Bearden CE, Loewy R, Thompson P, Toga AW *et al* (2003). Early and late neurodevelopmental influences in the prodrome to schizophrenia: contributions of genes, environment, and their interactions. *Schizophr Bull* **29**: 653–669.

Cannon TD, van Erp TG, Rosso IM, Huttunen M, Lonnqvist J, Pirkola T *et al* (2002b). Fetal hypoxia and structural brain abnormalities in schizophrenic patients, their siblings, and controls. *Arch Gen Psychiatry* **59**: 35–41.

Carlezon Jr WA, Mague SD, Andersen SL (2003). Enduring behavioral effects of early exposure to methylphenidate in rats. *Biol Psychiatry* **54**: 1330–1337.

Cascio CJ, Gerig G, Piven J (2007). Diffusion tensor imaging: application to the study of the developing brain. *J Am Acad Child Adolesc Psychiatry* **46**: 213–223.

Casey BJ, Durston S (2006). From behavior to cognition to the brain and back: what have we learned from functional imaging studies of attention deficit hyperactivity disorder? *Am J Psychiatry* **163**: 957–960.

Casey BJ, Giedd JN, Thomas KM (2000). Structural and functional brain development and its relation to cognitive development. *Biol Psychol* **54**: 241–257.

Castellanos FX, Lee PP, Sharp W, Jeffries NO, Greenstein DK, Clasen LS *et al* (2002). Developmental trajectories of brain volume abnormalities in children and adolescents with attention-deficit/hyperactivity disorder. *JAMA* **288**: 1740–1748.

Castellanos FX, Sharp WS, Gottesman RF, Greenstein DK, Giedd JN, Rapoport JL (2003). Anatomic brain abnormalities in monozygotic twins discordant for attention deficit hyperactivity disorder. *Am J Psychiatry* **160**: 1693–1696.

Caviness VSJ, Lange NT, Makris N, Herbert MR, Kennedy DN (1999). MRI-based brain volumetrics: emergence of a developmental brain science. *Brain Dev* **21**: 289–295.

Caviness Jr VS, Takahashi T (1995). Proliferative events in the cerebral ventricular zone. *Brain Dev* **17**: 159–163.

Changeux JP, Danchin A (1976). Selective stabilization of developing synapses as a mechanism for the specification of neuronal networks. *Nature* **264**: 705–712.

Coyle JT (2004). The GABA-glutamate connection in schizophrenia: which is the proximate cause? *Biochem Pharmacol* **68**: 1507–1514.

Crair MC (1999). Neuronal activity during development: permissive or instructive? *Curr Opin Neurobiol* **9**: 88–93.

Crair MC, Malenka RC (1995). A critical period for long-term potentiation at thalamocortical synapses. *Nature* **375**: 325–328.

Crone EA, Donohue SE, Honomichl R, Wendelken C, Bunge SA (2006). Brain regions mediating flexible rule use during development. *J Neurosci* **26**: 11239–11247.

Derbyshire SW, Vogt BA, Jones AK (1998). Pain and Stroop interference tasks activate separate processing modules in anterior cingulate cortex. *Exp Brain Res* **118**: 52–60.

Desmond JE, Chen SH, Shieh PB (2005). Cerebellar transcranial magnetic stimulation impairs verbal working memory. *Ann Neurol* **58**: 553–560.

Desmond J, Fiez JA (1998). Neuroimaging studies of the cerebellum: language, learning and memory. *Trends Cogn Sci* **2**: 355–363.

Dong WK, Greenough WT (2004). Plasticity of nonneuronal brain tissue: roles in developmental disorders. *Ment Retard Dev Disabil Res Rev* **10**: 85–90.

Draganski B, Gaser C, Busch V, Schuierer G, Bogdahn U, May A (2004). Neuroplasticity: changes in grey matter induced by training. *Nature* **427**: 311–312.

Durston S, Fossella JA, Casey BJ, Hulshoff Pol HE, Galvan A, Schnack HG *et al* (2005). Differential effects of DRD4 and DAT1 genotype on fronto-striatal gray matter volumes in a sample of subjects with attention deficit hyperactivity disorder, their unaffected siblings, and controls. *Mol Psychiatry* **10**: 678–685.

Durston S, Tottenham NT, Thomas KM, Davidson MC, Eigsti IM, Yang Y *et al* (2003). Differential patterns of striatal activation in young children with and without ADHD. *Biol Psychiatry* **53**: 871–878.

Elbert T, Pantev C, Wienbruch C, Rockstroh B, Taub E (1995). Increased cortical representation of the fingers of the left hand in string players. *Science* **270**: 305–307.

Fagiolini M, Fritschy JM, Low K, Mohler H, Rudolph U, Hensch TK (2004). Specific GABAA circuits for visual cortical plasticity. *Science* **303**: 1681–1683.

Fagiolini M, Hensch TK (2000). Inhibitory threshold for critical-period activation in primary visual cortex. *Nature* **404**: 183–186.

Faraone SV (2000). Genetics of childhood disorders: XX. ADHD, Part 4: is ADHD genetically heterogeneous? *J Am Acad Child Adolesc Psychiatry* **39**: 1455–1457.

Faraone SV, Perlis RH, Doyle AE, Smoller JW, Goralnick JJ, Holmgren MA *et al* (2005). Molecular Genetics of Attention-Deficit/Hyperactivity Disorder. *Biol Psychiatry* **57**: 1313–1323.

Fatemi SH, Earle JA, McMenomy T (2000). Reduction in Reelin immunoreactivity in hippocampus of subjects with schizophrenia, bipolar disorder and major depression. *Mol Psychiatry* **5**: 571, 654–663.

Fatemi SH, Stary JM, Earle JA, Araghi-Niknam M, Eagan E (2005). GABAergic dysfunction in schizophrenia and mood disorders as reflected by decreased levels of glutamic acid decarboxylase 65 and 67 kDa and Reelin proteins in cerebellum. *Schizophr Res* **72**: 109–122.

Feinberg I (1982). Schizophrenia: caused by a fault in programmed synaptic elimination during adolescence? *J Psychiatr Res* **17**: 319–334.

Feinberg I, Higgins LM, Khaw WY, Campbell IG (2006). The adolescent decline of NREM delta, an indicator of brain maturation, is linked to age and sex but not to pubertal stage. *Am J Physiol Regul Integr Comp Physiol* **291**: R1724–R1729.

Flint J, Munafo MR (2007). The endophenotype concept in psychiatric genetics. *Psychol Med* **37**: 163–180.

Floeter MK, Greenough WT (1979). Cerebellar plasticity: modification of Purkinje cell structure by differential rearing in monkeys. *Science* **206**: 227–229.

Friston K (2005). Disconnection and cognitive dysmetria in schizophrenia. *Am J Psychiatry* **162**: 429–432.

Friston KJ (1999). Schizophrenia and the disconnection hypothesis. *Acta Psychiatr Scand* **395**(Suppl): 68–79.

Frost DO, Tamminga CA, Medoff DR, Caviness V, Innocenti G, Carpenter WT (2004). Neuroplasticity and schizophrenia. *Biol Psychiatry* **56**: 540–543.

Gaab N, Tallal P, Kim H, Lakshminarayanan K, Archie JJ, Glover GH *et al* (2005). Neural correlates of rapid spectrotemporal processing in musicians and nonmusicians. *Ann New York Acad Sci* **1060**: 82–88.

Garlick D (2002). Understanding the nature of the general factor of intelligence: the role of individual differences in neural plasticity as an explanatory mechanism. *Psychol Rev* **109**: 116–136.

Giedd JN, Blumenthal J, Jeffries NO, Castellanos FX, Liu H, Zijdenbos A *et al* (1999). Brain development during childhood and adolescence: a longitudinal MRI study. *Nat Neurosci* **2**: 861–863.

Gilbert AR, Montros DM, Sahni SD, Diwadkar VA, Keshavan MS (2003). Obstetric complications correlate with neurobehavioral and brain structural alterations in young relatives at risk for schizophrenia. *Ann NY Acad Sci* **1008**: 269–275.

Gisabella B, Bolshakov VY, Benes FM (2005). Regulation of synaptic plasticity in a schizophrenia model. *Proc Natl Acad Sci USA* **102**: 13301–13306.

Gogtay N, Giedd JN, Lusk L, Hayashi KM, Greenstein D, Vaituzis AC *et al* (2004). Dynamic mapping of human cortical development during childhood through early adulthood. *Proc Natl Acad Sci USA* **101**: 8174–8179.

Gogtay N, Greenstein D, Lenane M, Clasen L, Sharp W, Gochman P *et al* (2007a). Cortical Brain Development in Non-Psychotic Siblings of Patients with Childhood Onset Schizophrenia. *Arch Gen Psychiatry* **64**: 772–780.

Gogtay N, Ordonez A, Herman D, Hayashi KM, Greenstein D, Vaituzis AC *et al* (2007b). Dynamic Mapping of Cortical Development Before and After the Onset of Pediatric Bipolar Illness. *J Child Psycol Psychiatry* **48**: 852–862.

Gogtay N, Sporn A, Clasen LS, Nugent III TF, Greenstein D, Nicolson R *et al* (2004). Comparison of progressive cortical gray matter loss in childhood-onset schizophrenia with that in childhood-onset atypical psychoses. *Arch Gen Psychiatry* **61**: 17–22.

Greenstein D, Lerch J, Shaw P, Clasen L, Giedd J, Gochman P *et al* (2006). Childhood onset schizophrenia: cortical brain abnormalities as young adults. *J Child Psychol Psychiatry* **47**: 1003–1012.

Haier RJ, Jung RE, Yeo RA, Head K, Alkire MT (2004). Structural brain variation and general intelligence. *NeuroImage* **23**: 425–433.

Harrison PJ, Owen MJ (2003). Genes for schizophrenia? Recent findings and their pathophysiological implications. *Lancet* **361**: 417–419.

Harrison PJ, Weinberger DR (2005). Schizophrenia genes, gene expression, and neuropathology: on the matter of their convergence. *Mol Psychiatry* **10**: 40–68; image 5.

Hebb DO (1949). *The Organization of Behavior: A Neuropsychological Theory*. Wiley: New York.

Hensch TK (2004). Critical period regulation. *Annu Rev Neurosci* **27**: 549–579.

Hulshoff Pol HE, Brans RG, van Haren NE, Schnack HG, Langen M, Baare WF *et al* (2004). Gray and white matter volume abnormalities in monozygotic and same-gender dizygotic twins discordant for schizophrenia. *Biol Psychiatry* **55**: 126–130.

Hurley MJ, Mash DC, Jenner P (2003). Markers for dopaminergic neurotransmission in the cerebellum in normal individuals and patients with Parkinson's disease examined by RT-PCR. *Eur J Neurosci* **18**: 2668–2672.

Huttenlocher J, Duffy S, Levine S (2002). Infants and toddlers discriminate amount: are they measuring? *Psychol Sci* **13**: 244–249.

Huttenlocher PR (1979). Synaptic density in human frontal cortex—developmental changes and effects of aging. *Brain Res* **163**: 195–205.

Huttenlocher PR, Dabholkar AS (1997). Regional differences in synaptogenesis in human cerebral cortex. *J Comp Neurol* **387**: 167–178.

Huttenlocher PR, de Courten C (1987). The development of synapses in striate cortex of man. *Hum Neurobiol* **6**: 1–9.

Hyman SE (2003). Methylphenidate-induced plasticity: what should we be looking for? *Biol Psychiatry* **54**: 1310–1311.

Isaacs E, Christie D, Vargha-Khadem F, Mishkin M (1996). Effects of hemispheric side of injury, age at injury, and presence of seizure disorder on functional ear and hand asymmetries in hemiplegic children. *Neuropsychologia* **34**: 127–137.

Ishibashi T, Wakabayashi J, Ohno Y (2002). 7-Hydroxy-N,N′-di-n-propyl-2-aminotetraline, a preferential dopamine D3 agonist,

induces c-fos mRNA expression in the rat cerebellum. *Jpn J Pharmacol* **89**: 309–315.
Jackson A, Mavoori J, Fetz EE (2006). Long-term motor cortex plasticity induced by an electronic neural implant. *Nature* **444**: 56–60.
Job DE, Whalley HC, Johnstone EC, Lawrie SM (2005). Grey matter changes over time in high risk subjects developing schizophrenia. *NeuroImage* **25**: 1023–1030.
Johnston MV (2006). Fresh ideas for treating developmental cognitive disorders. *Curr Opin Neurol* **19**: 115–118.
Kandel ER, Schwartz JH, Jessell TM (2000). *Principles of Neuroscience*. Elsevier: New York.
Keshavan MS, Dick E, Mankowski I, Harenski K, Montrose DM, Diwadkar V *et al* (2002). Decreased left amygdala and hippocampal volumes in young offspring at risk for schizophrenia. *Schizophr Res* **58**: 173–183.
Khan ZU, Gutierrez A, Martin R, Penafiel A, Rivera A, De La Calle A (1998). Differential regional and cellular distribution of dopamine D2-like receptors: an immunocytochemical study of subtype-specific antibodies in rat and human brain. *J Comp Neurol* **402**: 353–371.
Khan ZU, Gutierrez A, Martin R, Penafiel A, Rivera A, de la Calle A (2000). Dopamine D5 receptors of rat and human brain. *Neuroscience* **100**: 689–699.
Klein RG (1987). Prognosis of attention deficit disorder and its management of adolescence. *Pediatr Rev* **8**: 216–222.
Klingberg T, Fernell E, Olesen PJ, Johnson M, Gustafsson P, Dahlstrom K *et al* (2005). Computerized training of working memory in children with ADHD—a randomized, controlled trial. *J Am Acad Child Adolesc Psychiatry* **44**: 177–186.
Knudsen EI (2004). Sensitive periods in the development of the brain and behavior. *J Cogn Neurosci* **16**: 1412–1425.
Konrad K, Neufang S, Thiel CM, Specht K, Hanisch C, Fan J *et al* (2005). Development of attentional networks: an fMRI study with children and adults. *NeuroImage* **28**: 429–439.
Konradi C, Heckers S (2001). Antipsychotic drugs and neuroplasticity: insights into the treatment and neurobiology of schizophrenia. *Biol Psychiatry* **50**: 729–742.
Kovalchuk Y, Hanse E, Kafitz K, Konnerth A (2002). Postsynaptic induction of BDNF-mediated long-term potentiation. *Science* **295**: 1729–1734.
Kriegstein A, Parnavelas JG (2006). Progress in corticogenesis. *Cereb Cortex (New York, NY)* **16**(Suppl 1): i1–i2.
Kumra S, Jacobsen LK, Lenane M, Zahn TP, Wiggs E, Alaghband-Rad J *et al* (1998). 'Multidimensionally impaired disorder': is it a variant of very early-onset schizophrenia? *J Am Acad Child Adolesc Psychiatry* **37**: 91–99.
Kuperberg GR, Broome MR, McGuire PK, David AS, Eddy M, Ozawa F *et al* (2003). Regionally localized thinning of the cerebral cortex in schizophrenia. *Arch Gen Psychiatry* **60**: 878–888.
Lamprcht A, Ledoux J (2004). Structural plasticity and memory. *Nat Neurosci* **5**: 45–54.
Lawrie SM, Abukmeil SS (1998). Brain abnormality in schizophrenia. A systematic and quantitative review of volumetric magnetic resonance imaging studies. *Br J Psychiatry* **172**: 110–120.
Lawrie SM, Whalley HC, Abukmeil SS, Kestelman JN, Donnelly L, Miller P *et al* (2001). Brain structure, genetic liability, and psychotic symptoms in subjects at high risk of developing schizophrenia. *Biol Psychiatry* **49**: 811–823.
Lenroot R, Schmitt E, Ordaz S, Wallace G, Neale M, Lerch J *et al* (submitted). Developmental changes in postnatal genetic and environmentla influences on the human cerebral cortex.
Lerch JP, Worsley K, Shaw WP, Greenstein DK, Lenroot RK, Giedd J *et al* (2006). Mapping anatomical correlations across cerebral cortex (MACACC) using cortical thickness from MRI. *NeuroImage* **31**: 993–1003.
Levy F, Hay DA, McStephen M, Wood C, Waldman I (1997). Attention-deficit hyperactivity disorder: a category or a continuum? Genetic analysis of a large-scale twin study. *J Am Acad Child Adolesc Psychiatry* **36**: 737–744.
Lewis DA, Moghaddam B (2006). Cognitive dysfunction in schizophrenia: convergence of gamma-aminobutyric acid and glutamate alterations. *Arch Neurol* **63**: 1372–1376.
Li W, Cui Y, Kushner SA, Brown RA, Jentsch JD, Frankland PW *et al* (2005). The HMG-CoA reductase inhibitor lovastatin reverses the learning and attention deficits in a mouse model of neurofibromatosis type 1. *Curr Biol* **15**: 1961–1967.
Lipska BK, Jaskiw GE, Weinberger DR (1993). Postpubertal emergence of hyperresponsiveness to stress and to amphetamine after neonatal excitotoxic hippocampal damage: a potential animal model of schizophrenia. *Neuropsychopharmacology* **9**: 67–75.
Lu L, Leonard C, Thompson P, Kan E, Jolley J, Welcome SE *et al* (2007). Normal developmental changes in inferior frontal gray matter are associated with improvement in phonological processing: a longitudinal MRI Analysis. *Cereb Cortex* (in press).
Mackie S, Shaw P, Lenroot R, Pierson R, Sharp W, Giedd J *et al* (2007). Cerebellar Development and Clinical Outcome in Attention Deficit/Hyperactivity Disorder. *Am J Psychiatry* **164**: 647–655.
Maguire EA, Gadian DG, Johnsrude IS, Good CD, Ashburner J, Frackowiak RS *et al* (2000). Navigation-related structural change in the hippocampi of taxi drivers. *Proc Natl Acad Sci USA* **97**: 4398–4403.
Maki P, Veijola J, Jones PB, Murray GK, Koponen H, Tienari P *et al* (2005). Predictors of schizophrenia—a review. *Br Med Bull* **73–74**: 1–15.
Makris N, Biederman J, Valera EM, Bush G, Kaiser J, Kennedy DN *et al* (2007). Cortical thinning of the attention and executive function networks in adults with attention-deficit/hyperactivity disorder. *Cereb Cortex* **17**: 1364–1375.
Malenka RC, Nicoll RA (1999). Long-term potentiation—a decade of progress? *Science* **285**: 1870–1874.
Marcelis M, Suckling J, Woodruff P, Hofman P, Bullmore E, van Os J (2003). Searching for a structural endophenotype in psychosis using computational morphometry. *Psychiatry Res* **122**: 153–167.
Mathalon DH, Rapoport JL, Davis KL, Krystal JH (2003). Neurotoxicity, neuroplasticity, and magnetic resonance imaging morphometry. *Arch Gen Psychiatry* **60**: 846–848; author reply 848–849.
McDonald JW, Johnston MV (1990). Physiological and pathophysiological roles of excitatory amino acids during central nervous system development. *Brain Res* **15**: 41–70.
McDonald C, Marshall N, Sham PC, Bullmore ET, Schulze K, Chapple B *et al* (2006). Regional brain morphometry in patients with schizophrenia or bipolar disorder and their unaffected relatives. *Am J Psychiatry* **163**: 478–487.
McIntosh AM, Job DE, Moorhead WJ, Harrison LK, Whalley HC, Johnstone EC *et al* (2006). Genetic liability to schizophrenia or bipolar disorder and its relationship to brain structure. *Am J Med Genet B Neuropsychiatr Genet* **141**: 76–83.
Meador-Woodruff JH, Damask SP, Wang J, Haroutunian V, Davis KL, Watson SJ (1996). Dopamine receptor mRNA expression in human striatum and neocortex. *Neuropsychopharmacology* **15**: 17–29.
Melchitzky DS, Lewis DA (2000). Tyrosine hydroxylase- and dopamine transporter-immunoreactive axons in the primate cerebellum. Evidence for a lobular- and laminar-specific dopamine innervation. *Neuropsychopharmacology* **22**: 466–472.
Meyer-Lindenberg A, Weinberger DR (2006). Intermediate phenotypes and genetic mechanisms of psychiatric disorders. *Nat Rev Neurosci* **7**: 818–827.
Miller DD, Andreasen NC, O'Leary DS, Watkins GL, Boles Ponto LL, Hichwa RD (2001). Comparison of the effects of risperidone

and haloperidol on regional cerebral blood flow in schizophrenia. *Biol Psychiatry* **49**: 704–715.

Mohler H, Fritschy JM, Crestani F, Hensch T, Rudolph U (2004). Specific GABA(A) circuits in brain development and therapy. *Biochem Pharmacol* **68**: 1685–1690.

Narr KL, Bilder RM, Toga AW, Woods RP, Rex DE, Szeszko PR *et al* (2005). Mapping cortical thickness and gray matter concentration in first episode schizophrenia. *Cereb Cortex* **15**: 708–719.

Narr KL, Cannon TD, Woods RP, Thompson PM, Kim S, Asunction D *et al* (2002). Genetic contributions to altered callosal morphology in schizophrenia. *J Neurosci* **22**: 3720–3729.

Neville H, Bavelier D (2002). Human brain plasticity: evidence from sensory deprivation and altered language experience. *Prog Brain Res* **138**: 177–188.

Nicolson R, Lenane M, Hamburger SD, Fernandez T, Bedwell J, Rapoport JL (2000). Lessons from childhood-onset schizophrenia. *Brain Res Brain Res Rev* **31**: 147–156.

Nicolson R, Rapoport JL (1999). Childhood-onset schizophrenia: rare but worth studying. *Biol Psychiatry* **46**: 1418–1428.

Olesen PJ, Westerberg H, Klingberg T (2004). Increased prefrontal and parietal activity after training of working memory. *Nat Neurosci* **7**: 75–79.

Pantelis C, Yucel M, Wood SJ, Velakoulis D, Sun D, Berger G *et al* (2005). Structural brain imaging evidence for multiple pathological processes at different stages of brain development in schizophrenia. *Schizophr Bull* **31**: 672–696.

Penn AA, Shatz CJ (1999). Brain waves and brain wiring: the role of endogenous and sensory-driven neural activity in development. *Pediatr Res* **45**(4 Pt 1): 447–458.

Pierson R, Corson PW, Sears LL, Alicata D, Magnotta V, Oleary D *et al* (2002). Manual and semiautomated measurement of cerebellar subregions on MR images. *NeuroImage* **17**: 61–76.

Plomin R, Fulker D, Corley R, DeFries JC (1997). Nature, nurture and cognitive development from 1 to 16 years: a parent–offspring adoption study. *Psychol Sci* **8**: 442–447.

Posner MI, Dehaene S (1994). Attentional networks. *Trends Neurosci* **17**: 75–79.

Posner MI, Petersen SE (1990). The attention system of the human brain. *Ann Rev Neurosci* **13**: 25–42.

Rabinowicz T, de Courten-Myers GM, Petetot JM, Xi G, de los Reyes E (1996). Human cortex development: estimates of neuronal numbers indicate major loss late during gestation. *J Neuropathol Exp* **55**: 320–328.

Rapoport JL, Addington AM, Frangou S, Psych MR (2005). The neurodevelopmental model of schizophrenia: update 2005. *Mol Psychiatry* **10**: 434–449.

Rapoport JL, Giedd J, Kumra S, Jacobsen L, Smith A, Lee P *et al* (1997). Childhood-onset schizophrenia. Progressive ventricular change during adolescence. *Arch Gen Psychiatry* **54**: 897–903.

Rapoport JL, Giedd JN, Blumenthal J, Hamburger S, Jeffries N, Fernandez T *et al* (1999). Progressive cortical change during adolescence in childhood-onset schizophrenia. A longitudinal magnetic resonance imaging study. *Arch Gen Psychiatry* **56**: 649–654.

Rapoport JL, Inoff-Germain G (2000). Update on childhood-onset schizophrenia. *Curr Psychiatry Rep* **2**: 410–415.

Redmond Jr DE, Zhao JL, Randall JD, Eklund AC, Eusebi LO, Roth RH *et al* (2003). Spatiotemporal patterns of gene expression during fetal monkey brain development. *Brain Res* **146**: 99–106.

Ridler K, Veijola JM, Tanskanen P, Miettunen J, Chitnis X, Suckling J *et al* (2006). Fronto-cerebellar systems are associated with infant motor and adult executive functions in healthy adults but not in schizophrenia. *Proc Natl Acad Sci USA* **103**: 15651–15656.

Rubia K, Overmeyer S, Taylor E, Brammer M, Williams SC, Simmons A *et al* (2000). Functional frontalisation with age: mapping neurodevelopmental trajectories with fMRI. *Neurosci Biobehav Rev* **24**: 13–19.

Schmahmann JD (2004). Disorders of the cerebellum: ataxia, dysmetria of thought, and the cerebellar cognitive affective syndrome. *J Neuropsychiatry Clin Neurosci* **16**: 367–378.

Schoop VM, Gardziella S, Muller CM (1997). Critical period-dependent reduction of the permissiveness of cat visual cortex tissue for neuronal adhesion and neurite growth. *Eur J Neurosci* **9**: 1911–1922.

Seidman LJ, Faraone SV, Goldstein JM, Kremen WS, Horton NJ, Makris N *et al* (2002). Left hippocampal volume as a vulnerability indicator for schizophrenia: a magnetic resonance imaging morphometric study of nonpsychotic first-degree relatives. *Arch Gen Psychiatry* **59**: 839–849.

Selemon LD, Goldman-Rakic PS (1999). The reduced neuropil hypothesis: a circuit based model of schizophrenia. *Biol Psychiatry* **45**: 17–25.

Sharma A, Dorman MF, Spahr AJ (2002). A sensitive period for the development of the central auditory system in children with cochlear implants: implications for age of implantation. *Ear and hearing* **23**: 532–539.

Shaw P, Gornick M, Lerch J, Addington A, Seal J, Greenstein D *et al* (2007). Polymorphisms of the dopamine D4 receptors, clinical outcome and cortical structure in attention0deficit/hyperactivity disorder. *Arch Gen Psychiatry* **64**: 921–931.

Shaw P, Greenstein D, Lerch J, Clasen L, Lenroot R, Gogtay N *et al* (2006a). Intellectual ability and cortical development in children and adolescents. *Nature* **440**: 676–679.

Shaw P, Lerch J, Greenstein D, Sharp W, Clasen L, Evans A *et al* (2006b). Longitudinal mapping of cortical thickness and clinical outcome in children and adolescents with attention-deficit/hyperactivity disorder. *Arch Gen Psychiatry* **63**: 540–549.

Smith EE, Jonides J (1999). Storage and executive processes in the frontal lobes. *Science* **283**: 1657–1661.

Sowell ER, Peterson BS, Thompson PM, Welcome SE, Henkenius AL, Toga AW (2003). Mapping cortical change across the human life span. *Nat Neurosci* **6**: 309–315.

Sowell ER, Thompson PM, Holmes CJ, Jernigan TL, Toga AW (1999). In vivo evidence for post-adolescent brain maturation in frontal and striatal regions. *Nat Neurosci* **2**: 859–861.

Sowell ER, Thompson PM, Leonard CM, Welcome SE, Kan E, Toga AW (2004). Longitudinal mapping of cortical thickness and brain growth in normal children. *J Neurosci* **24**: 8223–8231.

Sowell ER, Thompson PM, Tessner KD, Toga AW (2001). Mapping continued brain growth and gray matter density reduction in dorsal frontal cortex: Inverse relationships during postadolescent brain maturation. *J Neurosci* **21**: 8819–8829.

Spessot AL, Plessen KJ, Peterson BS (2004). Neuroimaging of developmental psychopathologies: the importance of self-regulatory and neuroplastic processes in adolescence. *Ann N Y Acad Sci* **1021**: 86–104.

Staal WG, Hulshoff Pol HE, Schnack H, van der Schot AC, Kahn RS (1998). Partial volume decrease of the thalamus in relatives of patients with schizophrenia. *Am J Psychiatry* **155**: 1784–1786.

Stephan KE, Baldeweg T, Friston KJ (2006). Synaptic plasticity and dysconnection in schizophrenia. *Biol Psychiatry* **59**: 929–939.

Sur M, Rubenstein JL (2005). Patterning and plasticity of the cerebral cortex. *Science* **310**: 805–810.

Tallal P, Gaab N (2006). Dynamic auditory processing, musical experience and language development. *Trends Neurosci* **29**: 382–390.

Thompson PM, Vidal C, Giedd JN, Gochman P, Blumenthal J, Nicolson R *et al* (2001). Mapping adolescent brain change reveals dynamic wave of accelerated gray matter loss in very early-onset schizophrenia. *Proc Natl Acad Sci USA* **98**: 11650–11655.

Toga AW, Thompson PM (2005). Genetics of brain structure and intelligence. *Ann Rev Neurosci* **28**: 1–23.

Toga AW, Thompson PM, Sowell ER (2006). Mapping brain maturation. *Trends Neurosci* **29**: 148–159.

Ungerleider LG, Doyon J, Karni A (2002). Imaging brain plasticity during motor skill learning. *Neurobiol Learn Mem* **78**: 553–564.

Van Erp TG, Saleh PA, Rosso IM, Huttunen M, Lonnqvist J, Pirkola T *et al* (2002). Contributions of genetic risk and fetal hypoxia to hippocampal volume in patients with schizophrenia or schizoaffective disorder, their unaffected siblings, and healthy unrelated volunteers. *Am J Psychiatry* **159**: 1514–1520.

Vargha-Khadem F, Isaacs E, Muter V (1994). A review of cognitive outcome after unilateral lesions sustained during childhood. *J Child Neurol* **9**(Suppl 2): 67–73.

Volkow ND, Wolf AP, Brodie JD, Cancro R, Overall JE, Rhoades H *et al* (1988). Brain interactions in chronic schizophrenics under resting and activation conditions. *Schizophr Res* **1**: 47–53.

VonNoorden GK, Crawford ML (1979). The sensitive period. *Trans Opthal soc UK* **99**: 442–446.

Wallace GL, Eric Schmitt J, Lenroot R, Viding E, Ordaz S, Rosenthal MA *et al* (2006). A pediatric twin study of brain morphometry. *J Child Psychol Psychiatry* **47**: 987–993.

Wang VY, Zoghbi HY (2001). Genetic regulation of cerebellar development. *Nat Rev* **2**: 484–491.

Weinberger DR (1987). Implications of normal brain development for the pathogenesis of schizophrenia. *Arch Gen Psychiatry* **44**: 660–669.

Weinberger DR, Berman KF, Suddath R, Torrey EF (1992). Evidence of dysfunction of a prefrontal-limbic network in schizophrenia: a magnetic resonance imaging and regional cerebral blood flow study of discordant monozygotic twins. *Am J Psychiatry* **149**: 890–897.

Weinberger DR, McClure RK (2002). Neurotoxicity, neuroplasticity, and magnetic resonance imaging morphometry: what is happening in the schizophrenic brain? *Arch Gen Psychiatry* **59**: 553–558.

White T, Andreasen NC, Nopoulos P, Magnotta V (2003). Gyrification abnormalities in childhood- and adolescent-onset schizophrenia. *Biol Psychiatry* **54**: 418–426.

Whitford TJ, Rennie CJ, Grieve SM, Clark CR, Gordon E, Williams LM (2007). Brain maturation in adolescence: concurrent changes in neuroanatomy and neurophysiology. *Hum Brain Mapp* **28**: 228–237.

Wiegand LC, Warfield SK, Levitt JJ, Hirayasu Y, Salisbury DF, Heckers S *et al* (2004). Prefrontal cortical thickness in first-episode psychosis: a magnetic resonance imaging study. *Biol Psychiatry* **55**: 131–140.

Woo NH, Lu B (2006). Regulation of cortical interneurons by neurotrophins: from development to cognitive disorders. *Neuroscientist* **12**: 43–56.

Woods BT (1998). Is schizophrenia a progressive neurodevelopmental disorder? Toward a unitary pathogenetic mechanism. *Am J Psychiatry* **155**: 1661–1670.

Yew DT, Luo CB, Shen WZ, Chow PH, Zheng DR, Yu MC (1995). Tyrosine hydroxylase- and dopamine-beta-hydroxylase-positive neurons and fibres in the developing human cerebellum—an immunohistochemical study. *Neuroscience* **65**: 453–461.

Yucel M, Wood SJ, Phillips LJ, Stuart GW, Smith DJ, Yung A *et al* (2003). Morphology of the anterior cingulate cortex in young men at ultra-high risk of developing a psychotic illness. *Br J Psychiatry* **182**: 518–524.

Zhang ZW (2006). Canadian Association of Neurosciences review: postnatal development of the mammalian neocortex: role of activity revisited. *Can J Neurol Sci* **33**: 158–169.